

CASE REPORT**ANOTHER ADDITION TO THE COVID-19 ASSOCIATED
COMPLICATIONS-MUCORMYCOSIS****Fizza Mahmood, Muhammad Usama Mahmood, Aniq Riaz**

Department of Medicine, Bahawal Victoria Hospital, Bahawalpur-Pakistan

New manifestations of coronavirus disease are appearing over time. The association between coronavirus and mucormycosis must be given serious consideration. Without early diagnosis and treatment, there may be rapid progression of the disease, with high mortality from complications. We present a case of a 40-year-old male who presented with rhino-orbital-cerebral mucormycosis and COVID-19 infection. With this case, we highlight the importance of considering mycotic coinfection in COVID-19 patients with diabetes and the significance of its early diagnosis and treatment.

Keywords: COVID-19; Mucormycosis; Diabetes mellitus; Opportunistic infections

Citation: Mahmood F, Mahmood MU, Riaz A. Another addition to the COVID-19 associated complications-mucormycosis. J Ayub Med Coll Abbottabad 2022;34(4):872-3.

DOI: 10.55519/JAMC-04-9871

INTRODUCTION

Since the start of the corona virus pandemic, there has been a lot to learn about its pathophysiology, diagnosis, management, sequelae and complications. The symptom spectrum has expanded with time but so has the number of associated complications. Notable among these are the secondary infections among the COVID-19 patients. The frequency of secondary infections is 10–30% cases among the hospitalized, severely ill COVID-19 patients, with fungal infections being 10 times more common¹. Over the past few months, a sudden rise in cases of invasive fungal sinusitis, specifically mucormycosis has been seen. The reported mortality rates from intra-orbital and intracranial complications are 50–80 percent². Early identification is crucial for optimal treatment and improved outcomes. Here, we present a case of rhino-orbital-cerebral mucormycosis in a patient who presented to the ER with fever, pain in left eye and altered mental status.

CASE REPORT

A forty-year-old male, with past medical history of diabetes mellitus for 11 years managed by insulin, presented to the ER with complaints of fever for 15 days, pain in left eye for 15 days and altered mental status for 1 day. He had the following vitals: Blood pressure was 110/70, pulse was 85 beats per minute, Respiratory rate was 20 breaths per minute, temperature was 101°F and oxygen saturation was 94% on room air. Clinical examination revealed a black necrotic patch on the palate. On CNS examination, he was disoriented and had complete ophthalmoplegia of left eye, with absent left eye direct light reflex along with left eye ptosis, proptosis and chemosis. The sensations on the left side of face

were decreased and left sided facial weakness was present. The rest of the systemic examination was unremarkable. The provisional clinical diagnosis of cavernous sinus thrombosis secondary to pansinusitis and fungal infection was made.

The complete blood count showed total leukocyte count of 24300/mm³ with 85% neutrophils and 8% lymphocytes. The serum chemistry was significant for a blood glucose level of 418 and creatinine 1.1. Urinary ketones were three positives. ABGs showed arterial pH of 7.1. The chest x-ray showed left lower zone infiltrates. A chest computed tomography (CT) scan was performed and revealed peripheral patchy ground glass opacification bilaterally, more marked in the lower lobes. COVID-19 reverse transcription-polymerase chain reaction (RT-PCR) was ordered which returned positive. Inflammatory marker levels were C-reactive protein 49.13 mg/L (reference range: <0.7 mg/L); D-dimer 1.16 µg FEU/mL (reference range: <0.5 µg FEU/mL); and serum ferritin level of 1235.7 ng/dL (reference range for men, 18-464 ng/mL). The inflammatory marker levels along with chest computed tomography (CT) scan findings were highly suggestive of COVID infection. CT scan paranasal sinuses revealed soft tissue density material/thick fluid attenuation material in bilateral maxillary, ethmoid, sphenoid and frontal sinuses with few internal hyper densities. The CT findings were in favour of pansinusitis with superimposed fungal infection. MRI brain revealed fluid signals in all visualized paranasal sinuses indicative of pansinusitis and thrombus in left cavernous sinus. Ophthalmology was consulted which revealed left complete ophthalmoplegia, ptosis, left disc swelling, severe bilateral non-proliferative diabetic retinopathy and macular oedema. Otolaryngology was consulted

which revealed thick purulent discharge from left maxillary antrum and oedematous turbinate with no sign of tissue necrosis or blackening of tissue on naso-endoscopic examination which was highly suggestive of mucormycosis.

The patient was initially managed for diabetic ketoacidosis in the ER with intravenous fluids, sodium bicarbonate and insulin infusions per local protocol. Afterwards, the patient was shifted to medical ward for treatment of cavernous sinus thrombosis and fungal infection. He was treated empirically with Ceftriaxone, Vancomycin and Metronidazole for bacterial coverage and Enoxaparin for anticoagulation. Amphotericin and Voriconazole were given for coverage of fungal infection. Otolaryngology consultation suggested functional endoscopic sinus surgery (FESS) to clear antrum and widening of ostium for proper drainage. The patient was shifted to ENT department for serial debridements where he left against medical advice and was lost to follow up.

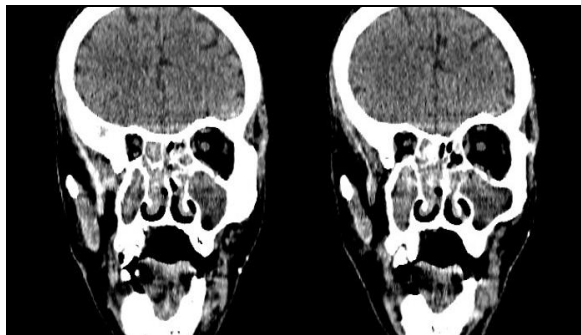


Figure-1: CT scan paranasal sinuses; coronal section; showing soft tissue density material in bilateral maxillary and ethmoidal sinuses

DISCUSSION

As the COVID-19 pandemic continues, a myriad of complications has been reported. Notable among these is the prevalence of opportunistic fungal co-infections in COVID-19 infected patients. Cases of mucormycosis in patients with acute and recent COVID-19 have been on the rise, making it more important to emphasize the importance of being aware of the possibility of infection and working

towards early diagnosis and management to improve patient survival. The pathophysiologic features of COVID-19 that may permit secondary fungal infections include its predilection to lung tissue, subsequent alveolo-interstitial pathology and associated immune dysregulation manifested as reduced numbers of T lymphocytes.³ Diabetes, a classic risk factor for mucormycosis, is associated with increased incidence and severity of COVID-19. A UK study shows higher prevalence of DM and DKA in COVID-19 patients as compared to national prevalence in the general population. The features of alteration of iron metabolism and endothelialitis associated with severe COVID-19 provides further possible explanation for the association between COVID-19 and mucormycosis. Mucormycosis appears to be in the grey area between COVID-19 and poorly controlled DM in the setting of the pandemic.⁴ The complex amalgam of factors including pre-existing diseases, widespread use of steroids/monoclonal antibodies/broad-spectrum antibiotics and systemic alterations of COVID-19 infection itself may lead to secondary infections. Physicians need to be vigilant of the possibility of opportunistic fungal co-infections in COVID-19 patients to reduce the risk of mortality, especially in patients with pre-existing risk factors. The use of immunosuppressive drugs and broad-spectrum antibiotics should be carefully monitored.⁵

Declaration of Competing Interest

The authors have declared that no competing interests exist.

REFERENCES

1. Maini A, Tomar G, Khanna D, Kini Y, Mehta H, Bhagyasree V. Sino-orbital mucormycosis in a COVID-19 patient: A case report. *Int J Surg Case Rep* 2021;82:105957.
2. Sharma S, Grover M, Bhargava S, Samdani S, Kataria T. Post coronavirus disease mucormycosis: a deadly addition to the pandemic spectrum. *J Laryngol Otol* 2021;135(5):442-7.
3. Gangneux JP, Bougnoux ME, Dannaoui E, Cornet M, Zahar JR. Invasive fungal diseases during COVID-19: We should be prepared. *J Mycol Med* 2020;30(2):100971.
4. John TM, Jacob CN, Kontoyiannis DP. When Uncontrolled Diabetes Mellitus and Severe COVID-19 Converge: The Perfect Storm for Mucormycosis. *J Fungi (Basel)* 2021;7(4):298.
5. Mehta S, Pandey A. Rhino-Orbital Mucormycosis Associated With COVID-19. *Cureus* 2020;12(9):e10726.

Submitted: July 16, 2021

Revised: November 16, 2021

Accepted: April 9, 2022

Address for Correspondence:

Fizza Mahmood, Department of Medicine, Bahawal Victoria Hospital, Bahawalpur-Pakistan

Cell: +92 336 240 0444

Email: fizamahmood23@gmail.com