

CASE REPORT

NON-UNION AND RESORPTION OF EXTENDED TROCHANTERIC OSTEOTOMY AND MANAGEMENT USING MODULAR TAPERED STEM IN PATIENT WITH EXTENSIVE SURGICAL HISTORY

Oluwatobi O Onafowokan, Amit Singh, Kuntal Patel

Royal Lancaster Infirmary-United Kingdom

Extended trochanteric osteotomy is an invaluable technique for enhancing femoral exposure during revision total hip arthroplasty. Complications are rarely reported but may include non-union. Even rarer is the incidence of extended trochanteric osteotomy resorption. We present our experience using a modular tapered stem in managing a resorbed extended trochanteric osteotomy following revision total hip arthroplasty in a patient with extensive hip surgical history. Good surgical technique is important in the prevention and management of resorption. It is also important to identify high risk patients such as smokers or those with peripheral vascular disease. Long femoral stem prosthesis with diaphyseal fixation may help in dealing with proximal bone loss due to resorption of an extended trochanteric osteotomy, and avoids the need for allogenic bone graft.

Keywords: Greater trochanter; Osteotomy; Ununited fracture; Bone resorption; Total hip arthroplasty

Citation: Onafowokan OO, Singh A, Patel K. Non-union and resorption of extended trochanteric osteotomy and management using modular tapered stem in patient with extensive surgical history. J Ayub Med Coll Abbottabad 2023;35(1):152-4.

DOI: 10.55519/JAMC-01-9550

INTRODUCTION

Extended trochanteric osteotomy (ETO), first described by Younger *et al*¹, is the gold standard for improving hip exposure during revision total hip arthroplasty (THA)¹. Complications include fracture, fragment migration, infection, mal-union and non-union.² Extended trochanteric osteotomy non-union is debilitating for patients; causing significant pain, hip instability, recurrent dislocation, and abnormal gait.^{1,3} Risk factors include: increased age, multiple surgical interventions, inadequate fragment stability, vascular disruption, soft tissue mishandling, and infection.³ Reports about co-occurrence of ETO non-unions and resorption of the trochanteric fragment are rare. Such complex pathology requires addressing the non-union and compensating for the proximal bone loss, otherwise risking stem destabilisation and implant failure. We present our experience with such a case.

CASE PRESENTATION

A 59-year-old man (BMI = 21.9 kg/m²) presented with progressive right hip and thigh pain. He was an active high-volume smoker with chronic obstructive pulmonary disease (COPD) and peripheral vascular disease (PVD), with femoral artery occlusion. He had an extensive surgical history. He underwent right hip arthrodesis 40 years previously, which failed within two years. He then underwent cemented THA [Figure-1], which lasted ~38 years, but eventually failed due to aseptic loosening. An uncemented revision THA was performed using an extended trochanteric osteotomy (ETO) [Figure-2].

Radiographs at six weeks indicated delayed ETO healing [Figure-3]. Radiographs at three months indicated significant lateral trochanteric bone resorption [Figure-4]. Radiographs at 1 year indicated worsening bone resorption [Figure-5]. Eight years later, he was referred to our unit. Radiographs indicated further bone resorption and a loosened femoral prosthesis [Figure-6]. After fully informed discussions and thorough workup to rule out infection, he underwent revision THA using a posterior approach. The acetabular shell was well-fixed and so the metal liner alone was exchanged for a lipped polyethylene liner, to provide additional stability. A modular tapered size 15 by 190 distal stem and 20×75 proximal body was used. Trial reduction with a +9 head was very stable. Thus, the final component was a metal 32 mm +9 head. A lipped liner was impacted in the cup to provide additional hip stability. Routine closure was performed. At six-week follow-up, he was progressing well, mobilising with crutches and able to bear some weight on his right leg; with satisfactory radiographs. At three months, he was still progressing well but complained of some right thigh and knee pain. Radiographs indicated the distal tip of the stem abutting the anterior cortex, due to a mismatch between the bow of the stem and the patient's native femoral bow [Figure-7]. He was advised to slightly reduce the weight-bearing on the right leg until the pain intensity had decreased adequately to allow comfortable weight-bearing. At six months, his pain had significantly reduced and radiographs did not indicate any progression of the abutment of the distal stem against the femoral cortex. At his most recent follow-up at 12 months, he continues to have some mild thigh pain, but plain film radiographs of the femur have shown bone remodelling around the proximal stem [Figure-8]. He is being followed up closely due to his increased risk of periprosthetic fracture.

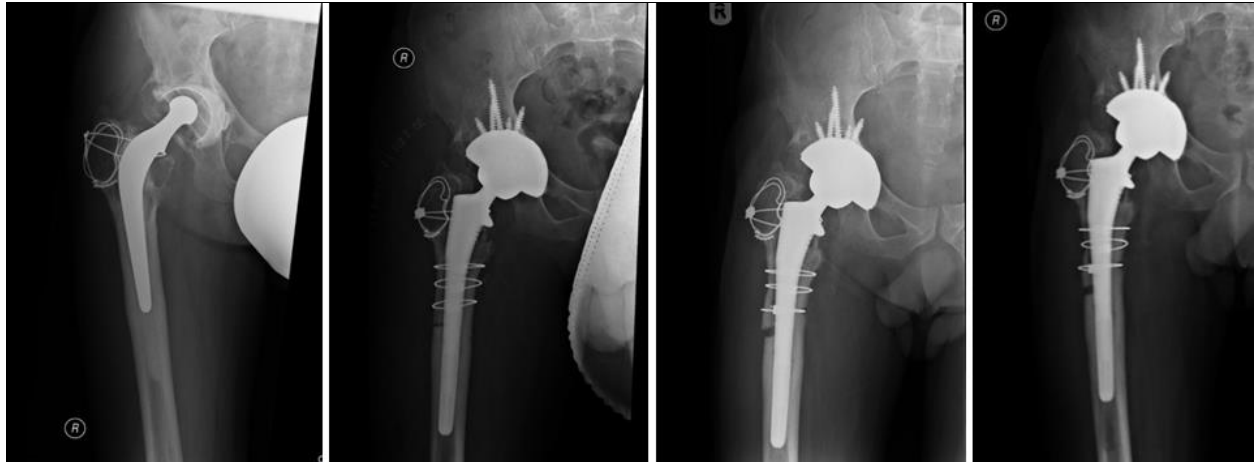


Figure-1: Initial cemented hip arthroplasty. Generalised loosening around femoral and acetabular components. Cortical hypertrophy around the tip of loose stem. Resorption of proximal femoral bone noted

Figure-2: Uncemented revision hip arthroplasty. Evidence of extended trochanteric osteotomy fixed with three cerclage wires.

Figure-3: Six weeks post-op. No evidence of healing at osteotomy site. Early signs of cerclage wires cutting through the proximal femoral bone

Figure-4: Three months post-op. Near complete resorption of trochanteric bone on lateral aspect

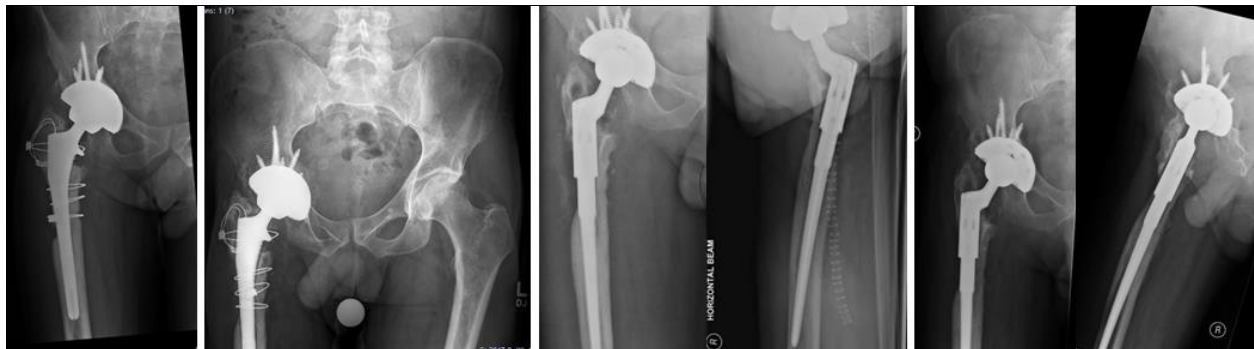

Figure-5: 1-year post-op. Complete resorption of bone under distal two cerclage wires on lateral aspect

Figure-6: 8-years post-op. Further bone resorption and loosened femoral prosthesis

Figure-7: Three months post-op second revision hip arthroplasty. Distal tip of the stem noted to be abutting the anterior femoral cortex

Figure-8: 1-year post-op second revision hip arthroplasty. Bone remodelling noted around proximal stem

DISCUSSION

There are three types of trochanteric osteotomy. Standard trochanteric osteotomy is rarely used, except in complex acetabular revision where extensive acetabular exposure is needed.⁴ Trochanteric slide osteotomy is similar, with the added advantage of retaining the intact vastus lateralis origin, preventing proximal trochanteric migration.⁵ The extended trochanteric osteotomy (ETO) advances on the previous two techniques by also enhancing femoral exposure for easier stem extraction.¹ Compared to the other two techniques, complications following ETO are rarely reported, but may include non-union, osteotomy fragment fracture and vascular injury.¹

There are limited reports of ETO non-unions in the literature. In one report, the stem remained

well-fixed within the femur. The authors re-fixed the trochanteric fragment with the aid of autogenous bone grafting, and the osteotomised femoral flap (OFF) subsequently healed completely.⁶ In another instance there was subsidence and loosening of the stem, and so the stem was completely revised with the aid of proximal femoral allograft.⁷ In yet another instance, the patient had asymptomatic fibrous union (with incomplete bony union), and therefore the authors did not intervene.⁸

The exact aetiology of post-ETO femoral bone resorption is unknown. A multi-factorial hypothesis has been proposed including: inadequate revascularisation, slow immunologic rejection, and mechanical stress shielding due to distal cemented fixation.⁹ Our patient's increased risk for non-union and resorption was likely due to multiple surgeries,

PVD, COPD, and his extensive smoking history; all factors which predictably compromised vascular supply to the bone surrounding the osteotomy site. There is also the possibility of stress shielding and devascularization when the initial ETO was created. In this report, we describe how we managed a non-union and resorption of an ETO. The decision on the revision implant choice was made based on the patient's relatively young age. The rationale was that the longer stem would ensure better distal loading, with stability being achieved by fixation into the diaphyseal isthmus. Modular femoral stems such as the one used in this case have been previously used effectively in achieving desirable effects such as femoral offset restoration, leg length equalisation and increased hip stability.¹⁰

Extended trochanteric osteotomy has been a welcome advancement in techniques for tackling the complexity of revision THA. ETO non-unions are a rare but challenging complication. It has been suggested that longer ETOs (mean length ~20 cm) may reduce incidence of non-union, due to the higher diaphyseal surface area for healing.⁷ To our knowledge, there is still no definitive management of concurrent ETO non-unions and resorptions following revision THA in the literature. A long femoral stem prosthesis with diaphyseal fixation may help in dealing with proximal bone loss due to resorption of ETO, and avoids the need for allogenic bone graft. A custom-made prosthesis may be required to avoid the mismatch between the curve of the stem and the femoral diaphysis; which avoids the problem of the tip of the stem abutting against the femoral anterior cortex. It is also important to identify patients with risk factors for ETO resorption,

such as PVD, smoking, multiple surgical interventions and long-term steroid treatment.

Conflicts of Interest:

None declared

REFERENCES

1. Younger TI, Bradford MS, Magnus RE, Paprosky WG. Extended proximal femoral osteotomy. A new technique for femoral revision arthroplasty. *J Arthroplasty* 1995;10(3):329–38.
2. Miner TM, Momberger NG, Chong D, Paprosky WL. The extended trochanteric osteotomy in revision hip arthroplasty: a critical review of 166 cases at mean 3-year, 9-month follow-up. *J Arthroplasty* 2001;16(8 Suppl 1):188–94.
3. Sambandam SN, Duraisamy G, Chandrasekharan J, Mounasamy V. Extended trochanteric osteotomy: current concepts review. *Eur J Orthop Surg Traumatol* 2016;26(3):231–45.
4. Hardinge K. The direct lateral approach to the hip. *J Bone Joint Surg Br* 1982;64(1):17–9.
5. Glassman AH, Engh CA, Bobyn JD. A technique of extensile exposure for total hip arthroplasty. *J Arthroplasty* 1987;2(1):11–21.
6. Mardones R, Gonzalez C, Cabanela ME, Trousdale RT, Berry DJ. Extended femoral osteotomy for revision of hip arthroplasty: results and complications. *J Arthroplasty* 2005;20(1):79–83.
7. Lakstein D, Kosashvili Y, Backstein D, Safir O, Lee P, Gross AE. The long modified extended sliding trochanteric osteotomy. *Int Orthop* 2011;35(1):13–7.
8. Kuruvalli RR, Landsmeer R, Debnath UK, Suresh SP, Thomas TL. A New Technique to Reattach an Extended Trochanteric Osteotomy in Revision THA Using Suture Cord. *Clin Orthop Relat Res* 2008;466(6):1444–8.
9. Haddad FS, Garbuz DS, Masri BA, Duncan CP. Structural proximal femoral allografts for failed total hip replacements: a minimum review of five years. *J Bone Joint Surg Br* 2000;82(6):830–6.
10. Restrepo C, Mashadi M, Parvizi J, Austin MS, Hozack WJ. Modular femoral stems for revision total hip arthroplasty. *Clin Orthop Relat Res* 2011;469(2):476–82.

Submitted: May 2, 2021

Revised: July 15, 2022

Accepted: August 2, 2022

Address for Correspondence:

Oluwatobi O Onafowokan, Royal Lancaster Infirmary-United Kingdom

Tel: +44 1524 65944

Email: tonafowokan7@gmail.com