

## ORIGINAL ARTICLE

## ANAPLASTIC THYROID CARCINOMA WITH LEUCOCYTOSIS

Shagufta Naeem, Anila Riyaz, Shabana Naz, Aisha Jamil, Abdur Rehman, Sidra Maqbool, Hamza Javed

Department of Pathology, Ayub Medical College, Abbottabad-Pakistan

**Background:** Anaplastic thyroid carcinoma is a high-grade tumour with poor prognosis. Most of the cases are easily diagnosed on cytology and some of these are associated with increased neutrophils in cytology specimen as well as in the blood. The objective of the study is to determine the frequency of neutrophilia with fever in anaplastic thyroid carcinoma. **Methods:** This descriptive cross-sectional study was performed in the Department of Pathology Ayub Teaching Hospital Abbottabad as well as in association with Advance lab Abbottabad. All the cases diagnosed as anaplastic thyroid carcinoma on cytology were included, histopathological examination was done only in 5 cases. The duration of study was from October 2016 to October 2019 were included in the study. **Results:** Out of 150 cases of thyroid cytology 09 were diagnosed as anaplastic thyroid carcinoma. The mean age of patients was  $65.7 \pm 6.96$ . Gender distribution was 5/9 (55.6%) males and 4/9 (44.4%) were females. Out of which 05 were confirmed on histopathology 3 patients died within a month and 1 patient refused a biopsy. All of these cases were associated with an increased number of neutrophils on cytology and WBC count is 04 cases showed leucocytosis. All of them presented with rapidly growing mass in long-standing goitre with a median duration of 2 months. Weight loss was seen in 4/9 (44.44%), 3/9 (33.33%) presented with hoarseness of voice while only 1/9 (11.1%) patient presented with superior vena caval syndrome. **Conclusion:** In long-standing goitre rapid increase in size with fever and leucocytosis are suggestive of anaplastic thyroid carcinoma which should be investigated promptly.

**Keywords:** Anaplastic thyroid carcinoma; Leucocytosis; Goitre

**Citation:** Naeem S, Riyaz A, Naz S, Jamil A, Rehman A, Maqbool S, *et al.* Anaplastic thyroid carcinoma with leucocytosis. J Ayub Med Coll Abbottabad 2020;32(Suppl. 1):678–80.

## INTRODUCTION

Anaplastic Thyroid Carcinoma (ATC), an endocrine-related malignancy, is a rare but a belligerent tumour that usually presents at an advanced stage and is associated with poor prognosis.<sup>1,2</sup> ATC has a prevalence of 1.7 to 9.8% and a median prevalence of 3.6% of all thyroid cancers.<sup>3–5</sup> Mortality attributed to ATC is 33–50% of all thyroid cancer related deaths. ATC has disease specific mortality approaching 100%.<sup>3,6,7</sup>

The diagnostic modality for ATC is FNAC. In doubtful cases, the diagnosis is made by histology on the core biopsy.<sup>8</sup> Anaplastic Thyroid Carcinoma is a tumour of follicular cells of the thyroid gland that can have any of the three histologic patterns including Giant cell, Spindle cell and Sarcomatoid histology. Often these three subtypes coexist. An infiltrative growth pattern, necrosis along with the high mitotic rate is commonly seen in all subtypes.<sup>3,4,9–11</sup>

Anaplastic Thyroid Carcinoma has a dismal long-term survival rate (1 year and 10-year disease specific survival are 33% and 3% respectively) and a median survival of 5 months.<sup>3,4,6,7,12</sup> Retrospective multicentre studies have reported 9 months survival in patients with stage IVA disease while 4.8 months in stage IVB disease and stage IVC disease survival was only 3 months, irrespective of various treatment options.<sup>13,14</sup> The American and the British Thyroid Association (BTA) as well as the National

Comprehensive Cancer Network and Practical Guidelines for Anaplastic thyroid cancer, discussed different treatment modalities, like surgery, radiotherapy with or without chemotherapy.<sup>4,8,15</sup> In some patients having regionally confined anaplastic thyroid cancer multimodal and intensive therapy may help in improving local control and survival.<sup>2,3,16</sup>

Thyroid carcinomas staging is according to the 8<sup>th</sup> edition of the American Joint Committee on Cancer (AJCC) TNM classification system which has designated all ATC as Stage IV on diagnosis, with Stage IVA being intra-thyroid tumours, Stage IVB denoting primary tumour with a gross extrathyroidal extension but no metastasis and Stage IVC showing the presence of distant metastasis.<sup>6,17</sup> Major clinical presentations of ATC other than a rapidly enlarging mass in a longstanding goitre, are weight loss, fever, elevated CRP levels, Leucocytosis and compressive symptoms including neck pain, hoarseness, dysphagia and dyspnoea.<sup>3,9,16</sup> This study is conducted and reported with the purpose to highlight the local magnitude of the problem that may help clinicians and pathologists alike in making informed decisions and also to emphasise the role of FNAC in thyroid mass.

## MATERIAL AND METHODS

It is a cross-sectional descriptive study conducted on patients who presented with longstanding goitre with

rapid growth in the thyroid mass to the Pathology Laboratory of Ayub Teaching Hospital Abbottabad and Advance Laboratory Abbottabad for investigation of thyroid malignancy. Data was collected by Non probability consecutive sampling technique for three years, i.e., from October 2016 to October 2019 on a *pro forma* including a total of 150 cases who were investigated through FNAC of the thyroid mass. Data included demography of the patient, history of the illness, clinical examination and relevant investigations. Cases of thyroid mass which were positive for Anaplastic Thyroid Carcinoma on fine needle aspiration cytology were included. The specimens of patients in whom biopsies were taken, were evaluated on Haematoxylin and Eosin-stained sections from paraffin embedded 10% buffered formalin fixed tissue blocks. The relevant clinical data as age and sex were also noted. The study was conducted after Ethical review board approval and written informed parental/ legal guardian permission/ consent under local regulation. Confidentiality of the data was maintained.

Data was analysed on SPSS Version 16.0. Quantitative data was described as mean and SD while the categorical data was expressed as percentages and frequencies.

## RESULTS

Out of 150 cases 09 cases of anaplastic thyroid carcinoma were diagnosed. The age of the patients ranges from 57 to 75 years with a mean age of patients was 65.7±6.96. Gender distribution was 5/9 (55.6%) males and 4/9 (44.4%) were females making a male to female ratio of 1.25:1. Five were confirmed on histopathology; 3 patients died within a month and 1 patient refused a biopsy. All of these cases were associated with an increased number of neutrophils on cytology and WBC count of 4/9 (44.4%) cases showed leucocytosis. Long standing goitre was present in 8/9 (88.8%) patients and they presented with rapidly growing mass in long standing goitre with a median duration of 2 months. Weight loss was seen in 4/9 (44.44%), 3/9 (33.33%) presented with hoarseness of voice while only 1/9 (11.1%) patient presented with superior vena cava syndrome. (Figure-1)

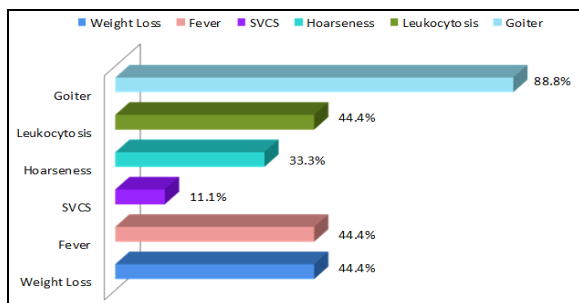


Figure-1: Study Parameters

## DISCUSSION

Out of the 150 patients who presented with thyroid cancers, 9 were diagnosed to be cases of ATC on cytology and five of them were confirmed on histopathology. Three patients died in less than a month time after their diagnosis was established so histopathology could not be done in them and one patient refused for histopathology.

In our study, the age of the patients ranges from 57 to 75 years with a mean age of patients calculated to be 65.7±6.96 years. Our results correlate with literature as it says that ATC is a disease of the elderly with a mean age in mid 60s and a peak incidence in the 6th and 7th decade of life.<sup>3,18,19</sup>

In our study, 55.6% of patients were male and 44.4% of patients were female making Male to Female ratio of 1.25:1. Huang *et al* reported in their population-based study on 735 ATC patients the Male to Female ratio of 1:1.67. Generally, ATC is more prevalent in the female population. The contrast with the gender ratio of our study is due probably to less no of cases of ATC in our study and the cases were from a limited geographical area. Unexplained Leucocytosis has been reported with different malignancies especially the non-small cell carcinoma of the lung.<sup>20</sup> Such tumours itself produces hematopoietic cytokines, i.e., Granulocytes Colony Stimulating Factor (G-CSF), Monocytes Colony Stimulating Factor (M-CSF), Granulocytes Monocytes Colony Stimulating Factor (GM-CSF), which expresses itself as marked leucocytosis.<sup>21</sup> Kusaga *et al* reported that 33 out of the 227 cases of lung cancer, included in their study, presented with tumour related Leucocytosis. The mechanism of Leucocytosis caused by the malignant neoplasms is not understood.<sup>20</sup>

Anaplastic Thyroid Carcinoma is associated with Leucocytosis. Patients with Leucocytosis have significantly shorter survival and poor prognosis than those without Leucocytosis.<sup>10,22</sup> In our study, all the cases were associated with an increased number of neutrophils on cytology and 44.4% cases showed leucocytosis on Complete Blood Picture (CBC). Fever was also present in 44.4% of patients. There are various case reports (Sato *et al*, Sabusawa *et al*, Murabe *et al*) which have mentioned the presence of ATC with leucocytosis and high-grade fever during their clinical course.<sup>23-26</sup> A study reported 47.4% patients to have tumour related leucocytosis. Fever, closely related to leucocytosis, was also reported in 33.3% of patients at the time of their diagnosis.<sup>27</sup>

A review of 24 cases of ATC reported a history of longstanding goitre in (58.3% pts) along with a rapidly growing mass in the neck (83.3%).<sup>27</sup> History of long-standing goitre has been reported in about 80% of patients of ATC. Eight out of 9 (88.8%) patients of our study had a history of longstanding goitre and

rapidly growing mass in the neck. We also noted some other clinical features in our patients. Among those was weight loss noted in 4/9 (44.4%) patients, hoarseness of voice in 3/9 (33.3%) patients and superior vena cava syndrome in 1/9 (11.1%) patients. ATC has been reported to possess such clinical features as rapidly enlarging neck mass, dyspnoea, dysphagia, hoarseness of voice, neck pain and weight loss.<sup>16</sup> Among the strengths, we would report that rigorous measures were taken to collect and report specimens. Analytical study design could have elaborated and quantified risk factors in a better manner. FNAC is a valuable investigation as it guides clinician in proper management of patients.

### AUTHORS' CONTRIBUTION

SN, AR and SN have equally contributed. AJ, AR, SM and HJ contributed in data collection and write-up.

### REFERENCES

1. Siegel RL, Miller KD, Fedewa SA, Ahnen DJ, Meester RG, Barzi A, *et al.* Cancer statistics, 2017. *CA Cancer J Clin* 2017;67(3):177-93.
2. Filetti S, Durante C, Hartl D, Leboulleux S, Locati LD, Newbold K, *et al.* Thyroid cancer: ESMO Clinical Practice Guidelines for diagnosis, treatment and follow-up†. *Ann Oncol* 2019;30(12):1856-83.
3. Garmpis N, Damaskos C, Garmpi A, Liakea A, Mantas D. Anaplastic Thyroid Cancer: A Rare Entity Presented Clinically Only with Fever and Elevated CRP. *Chirurgia (Buchar)* 2019;114(5):659-63.
4. Smallridge RC, Ain KB, Asa SL, Bible KC, Brierley JD, Burman KD, *et al.* American Thyroid Association guidelines for management of patients with anaplastic thyroid cancer. *Thyroid* 2012;22(11):1104-39.
5. Tiedje V, Stuschke M, Weber F, Dralle H, Moss L, Führer D. Anaplastic thyroid carcinoma: review of treatment protocols. *Endocr Relat Cancer* 2018;25(3):R153-61.
6. Ranganath R, Shah MA, Shah AR. Anaplastic thyroid cancer. *Curr Opin Endocrinol Diabetes Obes* 2015;22(5):387-91.
7. O'Neill JP, Shaha AR. Anaplastic thyroid cancer. *Oral Oncol* 2013;49(7):702-6.
8. Haddad RI, Lydiatt WM, Ball DW, Busaidy NL, Byrd D, Callender G, *et al.* Anaplastic thyroid carcinoma, version 2.2015. *J Natl Compr Cancer Netw* 2015;13(9):1140-50.
9. Limaem F, Kashyap S, Giwa AO. Anaplastic Thyroid Cancer. In: StatPearls [Internet]. Treasure Island (FL): StatPearls Publishing; 2019 [cited 2019 Nov]. Available from: <http://www.ncbi.nlm.nih.gov/books/NBK538179/>
10. Hirokawa M, Sugitani I, Kakudo K, Sakamoto A, Higashiyama T, Sugino K, *et al.* Histopathological analysis of anaplastic thyroid carcinoma cases with long-term survival: a report from the Anaplastic Thyroid Carcinoma Research Consortium of Japan. *Endocr J* 2016;63(5):441-7.
11. Baloch ZW, LiVolsi VA. Pathology of anaplastic carcinoma. In: Wartofsky L, Van Nostrand D, editors. *Thyroid Cancer*. New York: Springer, 2016; p. 935-7.
12. Keutgen XM, Sadowski SM, Kebebew E. Management of anaplastic thyroid cancer. *Gland Surg* 2015;4(1):44-51.
13. Haymart MR, Banerjee M, Yin H, Worden F, Griggs JJ. Marginal treatment benefit in anaplastic thyroid cancer. *Cancer* 2013;119(17):3133-9.
14. Wendler J, Kroiss M, Gast K, Kreissl MC, Allelein S, Lichtenauer U, *et al.* Clinical presentation, treatment and outcome of anaplastic thyroid carcinoma: results of a multicenter study in Germany. *Eur J Endocrinol* 2016;175(6):521-9.
15. Perros P, Boelaert K, Colley S, Evans C, Evans RM, Gerrard Ba G, *et al.* Guidelines for the management of thyroid cancer. *Clin Endocrinol* 2014;81(Suppl 1):1-122.
16. Huang NS, Shi X, Lei BW, Wei WJ, Lu ZW, Yu PC, *et al.* An update of the appropriate treatment strategies in anaplastic thyroid cancer: a population-based study of 735 patients. *Int J Endocrinol* 2019;2019:8428547.
17. Tuttle RM, Morris LF, Haugen BR, Shah JP, Sosa JA, Rohren E, *et al.* Thyroid-differentiated and anaplastic carcinoma. *AJCC cancer staging manual*. 8th ed. New York: Springer, 2017; p.873-90.
18. Baloch Z, LiVolsi VA, Tondon R. Aggressive variants of follicular cell derived thyroid carcinoma; the so called 'real thyroid carcinomas'. *J Clin Pathol* 2013;66(9):733-43.
19. Ragazzi M, Ciarrocchi A, Sancisi V, Gandolfi G, Bisagni A, Piana S. Update on anaplastic thyroid carcinoma: morphological, molecular, and genetic features of the most aggressive thyroid cancer. *Int J Endocrinol* 2014;2014:790834.
20. Kasuga I, Makino S, Kiyokawa H, Katoh H, Ebihara Y, Ohyashiki K. Tumor-related leukocytosis is linked with poor prognosis in patients with lung carcinoma. *Cancer* 2001;92(9):2399-405.
21. Saitoh J, Shirai K, Musha A, Mizukami T, Abe T. A Case of Thyroid Anaplastic Carcinoma Presenting Marked Neutrophilia and Eosinophilia due to Co-Production of GM-CSF, M-CSF and IL-6. *Int J Radiol Radiat Ther* 2017;3(2):203-6.
22. Tomisawa Y, Ogasawara S, Kojika M, Hoshikawa K, Nishizuka S. Association between granulocyte colonies stimulating factor (G-CSF) production and leukocytosis in anaplastic thyroid carcinoma. *Thyroid Disord Ther* 2013;2:2.
23. Sato T, Omura M, Saito J, Hirasawa A, Kakuta Y, Wakabayashi Y, *et al.* Neutrophilia Associated with Anaplastic Carcinoma of the Thyroid: Production of Macrophage Colony-Stimulating Factor (M-CSF) and Interleukin-6. *Thyroid* 2000;10(12):1113-8.
24. Sabusawa T, Ishida Y, Harabuchi Y. A Case of Anaplastic Thyroid Carcinoma with Marked Leukocytosis. *Pract Otorhinolaryngol (Basel)* 2017;148:74-5.
25. Murabe H, Akamizu T, Kubota A, Kusaka S. Anaplastic thyroid carcinoma with prominent cardiac metastasis, accompanied by a marked leukocytosis with a neutrophilia and high GM-CSF level in serum. *Intern Med* 1992;31(9):1107-11.
26. Shiraishi J, Koyama H, Seki M, Hatayama M, Naka M, Kurajoh M, *et al.* Anaplastic thyroid carcinoma accompanied by uncontrollable eosinophilia. *Intern Med* 2015;54(6):611-6.
27. Chang TC, Liaw KY, Kuo SH, Chang CC, Chen FW. Anaplastic thyroid carcinoma: review of 24 cases, with emphasis on cytodiagnosis and leukocytosis. *Taiwan Yi Xue Hui Za Zhi*. 1989;88(6):551-6.

Submitted: August 5, 2020

Revised: September 21, 2020

Accepted: November 1, 2020

### Address for Correspondence:

Dr. Shagufta Naeem, Department of Pathology, Ayub Medica College, Abbottabad-Pakistan

Cell: +92 334 895 2197

Email: drshaguftanaeem@yahoo.com