

## PICTORIAL

## AN UNUSUAL CASE OF IPSILATERAL SHOULDER AND ELBOW DISLOCATION

Ashutosh Mohapatra, Priyam Choudhury

Mohapatra Hospital, Ulhasnagar-Maharashtra, India  
Department of Radiology, Mayo Clinic, Florida-United States

A 34 years old male, labourer by occupation was brought to our trauma centre in an inebriated state with a history of fall from a height of approximately 10 feet. He complained of pain in the right elbow. A complete examination of the affected upper limb revealed an ipsilateral anterior shoulder dislocation and a posterior elbow dislocation with no other concomitant injuries. Both the dislocations were reduced conservatively and the patient was successfully managed. The patient is absolutely fine now, 6 months post his dislocation and has resumed back to his work. This case has been presented to highlight the rare and unusual nature of the injury, since ipsilateral dislocation of shoulder and elbow occur infrequently.

**Keywords:** Ipsilateral Dislocation; Shoulder; Elbow

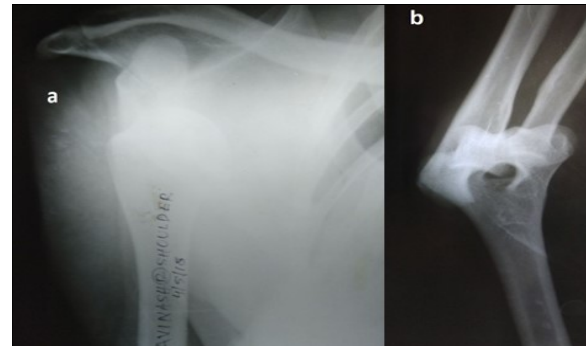
**Citation:** Mohapatra A, Choudhury P. An unusual case of ipsilateral shoulder and elbow dislocation. J Ayub Med Coll Abbottabad 2021;33(4):703-4.

## CASE

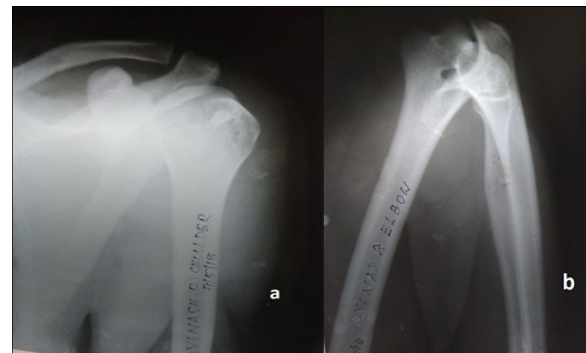
A 34 years old male, labourer by occupation was brought to our trauma centre in an inebriated state with a history of fall from a height of approximately 10 feet. The patient complained of severe pain in right elbow and was supporting his affected right extremity by the left extremity. Examination of the right elbow joint revealed a gross deformity of the joint with oedema and a contused lacerated wound (CLW) measuring approximately 3 cm over the right medial epicondyle area. Neurovascular status was normal. A thorough evaluation of the right upper limb revealed loss of contour of the right shoulder with tenderness over the right shoulder which raised suspicion of a right shoulder dislocation. The ranges of motion of both the joints were restricted too. Our suspicions were confirmed when the radiographic evaluation of the right upper extremity revealed an anterior shoulder dislocation (Figure-1a) and a posterior elbow dislocation (Figure-1b) with no associated fractures.

A complete and thorough evaluation of the body was done clinically and radiographically to rule out any other injuries. In the emergency room, the CLW was thoroughly irrigated and sutured with local anaesthesia. After the patient was transferred to the operating room the elbow joint was reduced initially followed by reduction of shoulder joint by Kocher's method under sedative anaesthesia. Reduction was confirmed clinically. An arm chest bandage strapping was applied for 3 weeks thereby immobilizing both (shoulder + elbow) joints. Post reduction radiographs revealed a complete anatomical reduction of the shoulder joint and elbow joint (Figure-2a & 2b). After 3 weeks the arm chest strapping bandage was removed and rehabilitation exercises of both joints

were started. The elbow range of motion (extension/flexion) was 60°/140° while the shoulder joint had a near total full range of motion. 6 months post reduction; the patient has a complete range of motion of both the joints with no discomfort whatsoever and has resumed work.



**Figure-1: (a) Radiograph showing anterior dislocation of shoulder joint (b) posterior dislocation of elbow joint**



**Figure-3: Post reduction radiograph showing (a) Absolute anatomical reduction of the shoulder joint. (b) Absolute anatomical reduction of the elbow joint.**

## DISCUSSION

Ipsilateral shoulder and elbow dislocation is a rare injury with very few cases been documented in literature. It is difficult to postulate the mechanism of injury in such patients since the patient is unable to recount the position of the affected extremity and the consequent force applied. A possible explanation concerning the mechanism is that the force is transmitted through the forearm with the elbow flexed and shoulder externally rotated.<sup>1</sup> Though this complex injury results from high energy trauma/fall, role of alcohol misuse as a major contributing factor can't be ruled out since the muscle tone considerably decreases for the dislocations to occur.<sup>2</sup> Our patient a labourer by occupation was intoxicated and fell down from a height of approximately 10 feet while at work. The resultant dislocation could have occurred by a combination of the forces transmitted and alcohol misuse. Ali et al mentioned that thorough examination and high degree of suspicion are mandatory for not missing the ipsilateral shoulder dislocation since the inebriated patient may not complain of pain in the affected extremity.<sup>3</sup> Similar incident happened in our case since our patient initially didn't complain of any pain in the affected shoulder joint, but a thorough examination revealed an anterior dislocation of the right shoulder joint. We first reduced the elbow joint to attain a stable distal extremity which made the shoulder reduction convenient and safe. A similar pattern of reduction was followed by the other cases too.<sup>1-3</sup> Shoulder reduction was done by Kocher's method which is as follows: With the patient in supine position, his arm adducted to the body and elbow flexed at 90 degrees. The doctor then externally rotates the arm till resistance is felt. The arm is then lifted, maintaining the external rotation and adducted. Then the arm is internally rotated initiating the reduction.<sup>4</sup> Elbow reduction was achieved by the following steps: initial correction of any medial/lateral displacement, flexion of the elbow to approximately 30 degrees, supination of the forearm and simultaneous traction + countertraction of the upper arm by an assistant.<sup>5</sup> Similar reduction manoeuvres were used in the other reports too.<sup>1-3</sup> Previously both the joints have been immobilised separately by the means of a body bandage/ broad arm sling (shoulder) and a posterior slab (elbow), we used a single modality( arm chest strapping bandage with collar cuff) for the immobilization of both the joints.<sup>1,3</sup> We believe that

the use of two different immobilizing modalities can cause inconvenience to the patient and a single intervention like arm chest strapping bandage also does the job as seen in our patient. Though this double dislocation is a complex trauma, the treatment is surprisingly simple. It involves a conservative approach which yields a satisfying functional outcome. 6 months post his reduction, our patient achieved a complete range of motion of both the joints and resumed back to his work. Return to complete range of motion was also reported in the previous cases.<sup>1,2</sup> Ali *et al.* didn't report the functional outcome of their case.<sup>3</sup> The probability of concomitant injuries like fractures and neurovascular deficit increases with such trauma. There have been reports mentioning antero-medial shoulder dislocation fracture + posterolateral ipsilateral elbow fracture dislocation, shoulder dislocation with humeral head fracture + ipsilateral transolecranon dislocation fracture of the elbow.<sup>6,7</sup> Weakness and hypoesthesia of median nerve distribution in the forearm and hand, hypoesthesia of the ulnar nerve have previously been reported.<sup>1,8</sup> Our patient didn't suffer from any concomitant injuries like fractures or neurovascular deficits which is similar to other reports published.<sup>2,3,9</sup>

## REFERENCES

1. Khan MR, Mirdad TM. Ipsilateral dislocation of the shoulder and elbow. Saudi Med J 2001;22(11):1019-2.
2. Essoh JB, Kodo M, Traoré A, Lambin Y. Ipsilateral dislocation of the shoulder and elbow: a case report. Niger J Surg Res 2005;7(3):319-20.
3. Ali FM, Krishnan S, Farhan MJ. A case of ipsilateral shoulder and elbow dislocation: an easily missed injury. J Accid Emerg Med 1998;15(3):198.
4. Kocher T. Eine neue Reductions methode fur Sschulter verrenkung. Berl Klin Wchnschr 1870;7:101-5.
5. Hobgood ER, Khan SO, Field LD. Acute dislocations of the adult elbow. Hand Clin 2008;24(1):1-7.
6. Songahir Christophe DA, Alexandre K, Sayouba T, Mamoudou S, Hamado K, Anatole Jean Innocent O, *et al.* Bipolar Dislocation of the Arm (Shoulder And Elbow): About One Case in an African Teaching Hospital. Open Orthop J 2018;12:147-52.
7. Behr I, Blint A, Trenhaile S. Ipsilateral fracture dislocation of the shoulder and elbow: A case report and literature review. J Clin Orthop Trauma 2013;4(4):204-9.
8. Cobanoğlu M, Yumrukcal F, Karataş C, Duygun F. Simultaneous shoulder and elbow dislocation. BMJ Case Rep 2014;2014:bcr2014204686.
9. Meena S, Saini P, Rustagi G, Sharma G. Ipsilateral shoulder and elbow dislocation: a case report. Malays Orthop J 2012;6(1):43-5.

### Address for Correspondence:

**Ashutosh Mohapatra**, Mohapatra Hospital, Ulhasnagar, Maharashtra-India  
**Email:** ashutoshmohapatra11.am@gmail.com