

ORIGINAL ARTICLE

OUTCOME OF OPEN INTERLOCKING NAILING IN
CLOSED FRACTURE SHAFT OF FEMUR

Muhammad Adeel, Shoaib Zardad, Shandana Mustafa Jadoon*, Muhammad Younas,
Usman Shah

Department of Orthopaedics, *Department of Gynaecology, Ayub Teaching Hospital Abbottabad-Pakistan

Background: Various treatment modalities have been used in treating femoral shaft fractures, i.e., open intramedullary nailing, plating and external fixators but these does not always produce stable fixation and there is increased risk of infection, closed locked intramedullary nailing technique has being the gold standard and is a routine procedure but it requires proper orthopedic operation table with traction apparatus and the use of image intensifier. The use of open interlocking nailing technique doesn't require any special orthopaedic table nor it requires use of Image intensifier. The objective of this study is to find out and determine the frequency of fracture union and wound infection in open reamed interlocking nailing of close fractures of shaft of femur. **Methods:** This study included fifty-eight patients from either gender, above 14 years of age with closed femoral shaft fracture presenting within 2 weeks. Data was collected on Performa about gender, age, address, date of fracture, date of operation and discharge, type of fracture and follow-up visits. **Results:** Mean age of the patients were 31.24 ± 8.662 . According to Winquist & Hansen, femur shaft fractures were divided into four types. Type I were found in the 16(27.6%), Type II in 21 (36.2%), Type III in 12 (20.7%) and Type IV in 9 (15.5%). Total number of fracture union with regard to Winquist & Hensen Classification of fracture shaft femur were, Type I, 14 (24.1%), Type II, 21 (36.2%), Type III, 12 (20.7%), Type IV, 8 (13.8%) respectively while the rest 3 (5.2%) were found in non-union. Total number of fracture union with regard to gender of the patients were, 41 (70.7%) males and 14 (24.1%) were females while the rest 3 (5.2%) patients fracture union has not occurred. Fracture union was found in 55 (94.8%) out of 58 patients; while fracture union had not occurred in 3 (5.2%) out of 58 patients. The total number of patients who developed wound infection following surgery were 5 (8.6%) out of 58 patients; while the non-infected patients were 53 (91.4%) out of 58 patients. **Conclusion:** The open interlocking nailing technique for close fractures shaft of femur without the use of image intensifier achieved excellent results in terms of fracture union. Results obtained are mostly similar to the results of close interlocking nailing and it also requires less expertise, recourses and without the use of image intensifier.

Keywords: Close Femoral Shaft Fracture; Open Interlocking nail

Citation: Adeel M, Zardad S, Jadoon SM. Outcome of open interlocking nailing in closed fracture shaft of femur. J Ayub Med Coll Abbottabad 2020;32(4):546–50.

INTRODUCTION

Among the fractures of long bones femoral shaft fracture is the most common one. Femur fractures are mostly caused by high energy accidents and mostly associated with multiple systemic injuries.¹ There are various methods of fixation of femur including traction and bracing, Intra Medullary Nails, plates and screws.² Management of these femur fractures has evolved with the period of time during the last ten years. In recent years femur fracture were treated by traction or splinting. Due to supine position of the patient and prolong treatment time which resulted in various complications like poor control of the length and alignment of the fractured bone, pulmonary insufficiency, DVT and joint stiffness.³ Procedure for open femoral shaft fractures which is commonly used is External Fixation, comminuted shaft fractures and unstable operative candidates.⁴ most common complication of external fixation of large bone

fractures like femur resulted in knee joint stiffness post op.⁵

After World War II Internal fixation of femoral shaft gained popularity. Kuntscher of Kiel, during the period Second World War, started intramedullary nailing for fractures of shaft of the femur.⁶ Interlocking for shaft of femur fractures can be performed by close as well as by open techniques.

Plating of the femoral shaft gained wide acceptance in 1970 and remained a method of choice for a long-time various plates and screws were developed by the A.O group of surgeons along with improved surgical technique.

After he found drawbacks in ordinary IMN, Kuntscher designed interlocking nail in late 60th but it gained acceptance in clinical practice after the modification made by Klem which was further modified by Grosse A.⁷

Intramedullary nailing can be performed by open or close techniques through antegrade or retrograde fashion and it depends upon fracture site of femur bone.⁷⁻⁹ The procedure of intramedullary nailing is by passing a guide wire into the medullary canal with the help of image intensifier machine. This is then followed by reaming of the femur and then introduction of the appropriate size nail. This technique is performed with the help of image intensifier machine or C - Arm and special orthopaedic traction operation table. Open Interlocking nailing does not require the use of special orthopaedic traction table, nor it requires image intensifier. The effects of image intensifier on orthopaedics trauma surgery are intense, so the image intensifier is not harmless and the significance of exposure increases over a surgeon's carriers.⁴

The fracture of femoral shaft treated by this important modality has been ignored and its advantages, disadvantages and complications in our province are not highlighted. Only few papers are available on this subject in our literature throughout Pakistan.

The use of this technique for fixation of all kinds of comminuted fractures is very important but there is much need to be understood regarding the results which include less hospital stay, less expertise, less resource's and early rehabilitation of the patient.^{1,4}

MATERIAL AND METHODS

During the year 2018 to 2019, fifty-eight cases of close femoral shaft fracture from Orthopaedics 'B' unit of Ayub Teaching Hospital Complex, Abbottabad were included in the study and the study was conducted from 1st Apr 2018 to 31st Mar 2019. Inclusive Criteria were close fracture shaft of femur, both sexes with Age above 14 years and Fracture presenting within 2 weeks. Exclusive criteria were fracture of femur previously treated by surgical interventions, Pathological fractures and medically unstable patient who is poor anesthetic and surgical risk.

This study was performed in Orthopedic "B" ward of Ayub Teaching Hospital Complex Abbottabad and after permission from the ethical board. The aim of the study and purpose were well explained to the patients involved. The doctors explained the procedure of surgery and consent. Doctors asked complete patient history especially about mechanism of injury and pain. Third generation Cefalosporin antibiotic was given intravenous as prophylactic half an hour before start of procedure. Operation was done under spinal or general anesthesia on operation table without traction apparatus and image intensifier. Fracture site was

minimally open and reduced. Open interlocking nailing was performed and proximal and distal screws were passed with the help its own assembly. Stitches were removed after two weeks during follow up visit. Follow-up visits on 6th, 12th and 24th weeks were done for assessment of Fracture union and complications like wound infection, clinically and with X-rays of femur shaft Antero-posterior and lateral views. All the data was collected on Performa about name, gender, age, type of fracture, date of injury, date of operation and discharge and follow up visits for fracture union and wound infection.

RESULTS

Total of 58 patients were included in this study to determine the frequency of fracture union and wound infections after the close interlocking nailing of close fracture shaft of femur. The study was conducted at Orthopaedics 'B' unit of Ayub Teaching Hospital Abbottabad from 1st Apr 2018 to 31st Mar 2019. The ages of the patients ranged from 15 to 55 years. Mean age of the patients were 31.24±8.662, out of 58 patients. Out of 58 patients, 42 males were in number with the mean age of 31.81±9.264 while the females were 16, with the mean of 29.75±6.875. Total of 58 patients, males were 42 (72%) and female were 16 (28%).

During the follow-up assessment at 2nd week, wound infection was found in 5(8.6%) out of 58 patients, as they had purulent discharge from the operation site. Follow-up at 6th week showed, infection in only 2 (3.4%) patients, while it was further reduced to only 1 (1.7%) patient at 12th week. At 24th week follow-up visits no patients were found infected. The total number of patients who developed wound infection following surgery were 5 (8.6%) out of 58 patients; while the non-infected patients were 53 (91.4%) out of 58 patients.

During the follow-up assessment at 6th week, fracture union was found in 43 (74.1%) out of 58 patients, when bridging callus and partial obliteration of the fracture site occurred as seen radiologically. At 12th week of follow-up visit, fracture union was found in the remaining 9 (15.5%) out of 15 patients; finally, at 24th week, union was found in the remaining 3 (5.2%) patients out of 6 patients. Fracture union was found in 55 (94.8%) out of 58 patients; while fracture union had not occurred in 3 (5.2%) out of 58 patients.

According to Winquist & Hansen, femur shaft fractures were divided into four types. Type I were found in the 16 (27.6%), Type II in 21 (36.2%), Type III in 12 (20.7%) and Type IV in 9 (15.5%). Total number of fracture union with regard to Winquist & Hensen Classification of fracture shaft femur were, Type I, 14 (24.1%), Type II, 21 (36.2%),

Type III, 12 (20.7%), Type IV, 8 (13.8%) respectively while the rest 3 (5.2%) were found in non-union. (Table-1) Total number of fracture union with regard to gender of the patients were, 41 (70.7%) males and 14 (24.1%) were females while the rest 3 (5.2%) patients were found as non-union in fracture.

Frequency distribution with regard to the hospital stay, patients who remained admitted in the ward, below 4 days 12 (20.7%), 4–8 days 44 (75.9%), 8–12 days 1 (1.7%) and above 12 days were 1 (1.7%) respectively.

Table-1: Total No. of Unions * Winquist & Hensen Classification of fracture shaft femur Cross-tabulation

Total No. of Unions	Winquist & Hensen Classification of fracture shaft femur				Total
	Type I	Type II	Type III	Type IV	
Yes	14	21	12	8	55
	24.1%	36.2%	20.7%	13.8%	94.8%
No	2	0	0	1	3
	3.4%	.0%	.0%	1.7%	5.2%
Total	16	21	12	9	58
	27.6%	36.2%	20.7%	15.5%	100.0%

Table-2: Time of Fracture Union

DURATION	No. of patients	Percentage
At 6 weeks	43	74.10
06 to 12 weeks	09	15.50
12 to 24 weeks	03	5.20

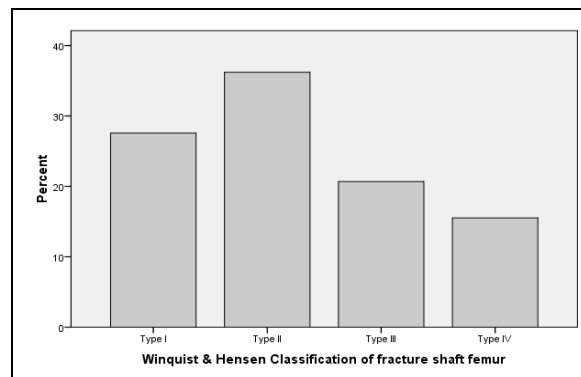


Figure-1: Type of fractures according to Winquist & Hensen Classification of fracture shaft femur

DISCUSSION

Comminuted femoral shaft fracture remained a challenge for decades for Orthopaedic Surgeons. Despite various modifications in its treatment this problem could not be solved. The advent of interlocking nail revolutionized the management of both open and closed fractures of femur shaft.

Although locking of the intramedullary nail was started by the Kuntchner in 1940^{1,2} after World War II but it was popularized in early years of 8th decade of last century.

The aim of this study was to evaluate the results of close interlocking nail in terms of fracture union and wound infection, which we come across during the treatment of such fractures. Furthermore, very few studies were available in our country on this important treatment modality of treating comminuted fractures of femoral shaft. Furthermore, no such

study has been ever performed in our hospital on this important treatment modality.

Most of the cases were young males ranging from 15 to 55 years of age. As majority of the young people are prone to road traffic accidents and fall from height injuries. There is an increase in number of vehicles on the roads and the rise in urban population, the frequency of comminuted fractures has increased over the last 15 to 20 years. The majority of victims of who had history of falls from were labourer working in the under-construction buildings, and farm workers who got their injuries due to fall from hills or from trees.

Males were more affected than females. This is because of the male dominated society and less active participation of females in day to day life activities in our province. Out of total 58 patients, 42 males were in number with the mean age of 31.81±9.264 while the females were 16, with the mean of 29.75±6.875. Total of 58 patients, males were 42 (72%) and female were 16 (28%).

Majority of the patients that we received in our emergency department are referred from other district hospitals where initial management of these fractures are performed like giving back slabs and wound wash. Due to non-availability of these expensive machines like C- Arm and traction tables, these patients are referred to tertiary hospitals for better management.

Fractures were classified according to Winquist and Hanson. According to this classification, femur shaft fractures were divided into four types. Type I were found in the 16 (27.6%), Type II in 21 (36.2%), Type III in 12 (20.7%) and Type IV in 9 (15.5%).⁸ Most of the patients with these fractures present within first twenty-four hours but because of huge burden of patients in our hospital, their operations are delayed and performed after a week staying in the hospital. This all results in huge burden on hospital

resources. Where as in the west due to good facilities in every hospital these surgeries are performed early to improve patient outcome.

Most of the previous studies show union of these fractures in four to five months.^{9,10} There is no fix time for the fractured bones union. After the surgery most of the patients start bearing weight so time for fracture union was difficult in them to access.¹¹ Clawson et al in his study have reported an average time for appearance of bridging callus at 6 weeks with partial obliteration of fracture site as the time of union.² In this study nature of bridging callus with partial obliteration of fracture site has been used as time for union. Assessment on return to work cannot be taken as a sign for progress of fracture healing since the majority of patients involved in the present series were labourer and before they can go back to work in contrast to the western countries where patients usually have sedentary jobs and hence can be put to work earlier as compared to our harsh environment for labourers who will require solid union.^{10,11}

During the follow-up assessment at 6th week, fracture union was found in 43 (74.1%) out of 58 patients, when bridging callus and partial obliteration of the fracture site has started as seen radiologically. At 12th week of follow-up visit, fracture union was found in the remaining 9 (15.5%) out of 58 patients. Finally, at 24th week of discharge, union was found in the remaining 3 (5.2%) while in 3(5.2%) patients it has not occurred yet.

Fracture union was found in 55 (94.8%) out of 58 patients; while fracture union had not occurred in 3 (5.2%) out of 58 patients. In such one previous study, fracture union after close inter locking nailing of close fracture shaft of femur was 93%, 42 out of 46 patients.¹¹

We routinely use pre and post-operative antibiotics in all of our patients in whom we use implants. In close fractures shaft of femur, we use 1 gm of 1st generation cephalosporin per operatively followed by 1 gm of 1st generation cephalosporin and 500 mg Amikicin for three days. Patients are then switched over to oral quinolones for 10 days. This was the reason for low infection rates at our unit. During the follow-up assessment at 2nd week, wound infection was found in 5 (8.6%) out of 58 patients, as they had purulent discharge from the operation site. At 6th week post operatively, infections were found in 2 (3.4%) patients and this decreased to only 1 (1.7%) patient at 12 weeks of follow up. At 24th week follow-up visits no patients were found infected. The total number of patients who developed wound infection following surgery were 5 (8.6%) out of 58 patients; while the non-infected patients were 53(91.4%) out of 58 patients.

Frequency distribution with regard to the hospital stay, patients who remained admitted in the ward, below 4 days were 12 (20.7%), 4–8 days were 44 (75.9%), 8–12 days were 1 (1.7%) and above 12 days were 1 (1.7%) respectively.

CONCLUSION

From the above results we concluded that open interlocking nailing technique for close fractures shaft of femur without the use of image intensifier achieved excellent results in terms of fracture union. Results obtained are comparable to the results of close interlocking nailing. This method requires no need for expensive operation theatre equipment's like image intensifier and orthopaedic traction table. Closed fractures can be treated effectively by this method of treatment, which is currently recommended all over the world especially in developing countries. It provides early mobilization of the patient decreases Hospital stay and thus total cost on the treatment of patient. Early rehabilitation and early returned to work make it more important and economical for the patients.

AUTHORS' CONTRIBUTION

MA: concept of the study, proof reading, data collection, data analysis and interpretation along with writeup. MSZ, MY, US: data collection and literature search. SMJ: Data analysis and interpretation.

REFERENCES

1. Court-Brown CM, Heckman JD, McQueen MM, Ricci WM, Tornetta P, McKee MD. Rockwood and Green's fractures in adults. 8th ed. Philadelphia: Lippincott Williams & Wilkins; 2015.
2. Canale ST, Azar FM, Beaty JH, Campbell WC. Campbell's operative orthopaedics. 13th ed. Philadelphia, PA: Elsevier, Inc; 2017; p.4.
3. Chapman MW, Mahory M. The role of early internal fixation in the management of open fractures. Clin Orthop 1979;138:120–31.
4. Winquist RA, Hansen ST Jr, Clawson DK. Closed intramedullary nailing of femoral fractures: A report of five hundred and twenty cases. J Bone Joint Surg Am 1984;66(4):529–39.
5. Grosse A, Christie J, Taglang G, Court-Brown, MC Queen M. Open adult femoral shaft fractures treated by early Interlocking Nail. J Bone Joint Surg 1993;75(4):562–5.
6. Brumback RJ, Relilly PJ, Poka A, Lakatos RP, Bathon HG, Burgess RA. Intramedullary Nailing of Femoral shaft Fractures. J Bone Joint Surg 1998;70(10):1453–62.
7. Canale ST, Beaty JH, Campbell WC, Daugherty K, Burns B. Campbell's operative orthopaedics: get full access and more at ExpertConsult.com. 12. ed., internat. ed. Philadelphia, Pa: Elsevier, Mosby; 2013.
8. Bailey and Loves, Short Practice of Surgery. General Principles of fractures and dislocation 24th ed. Churchill living stone; 2012.
9. Grover J, Wiss DA. A prospective study of the fractures of the femoral shaft treated with a static, Intramedullary

- Interlocking Nail comparing one versus two distal screws.
Orthop Clin North Am 1995;26(1):139-46.
10. Brien WW, Kuschner SH, Brien EW, Wiss DA. The management of gunshot wounds to the femur. Orthop Clin North Am 1995;26(1):133-8.
11. Meena RC, Kundnani V, Hussain Z. Fracture of the shaft of the femur: Close vs. open interlocking nailing. Indian J Orthop 2006;40(4):243-6.

Submitted: March 4, 2020

Revised: --

Accepted: September 27, 2020

Address for Correspondence:

Dr. Muhammad Adeel, Department of Orthopaedics, Ayub Medical college, Abbottabad-Pakistan

Cell: +92 333 504 9004

Email: smadeel99@gmail.com