

## CASE REPORT

# FAHR'S DISEASE IN A PATIENT PRESENTING WITH STATUS EPILEPTICUS

Shah Khalid, Shahbaz Ali Khan, Abdul Hameed Khan, Gul Muhammad, Ahsan Aurnagzeb Khan

Department of Neurosurgery, Ayub Medical College, Abbottabad-Pakistan

Fahr's disease is a rare disease in which there is symmetrical bilateral intracranial calcification. We are presenting a 50-year-old female patient who presented with status epilepticus. She had history of generalized tonic clonic fits for the last fifteen years. Her CT scan revealed widespread bilateral and symmetrical intracranial calcification in cerebellum, thalamus, basal ganglia and in white matter of the cerebral hemisphere. Most of the secondary causes were ruled out to make the clinical diagnosis of Fahr's disease.

**Keywords:** Fahr's disease, Fahr's Syndrome; Intracranial Calcifications; Status Epilepticus; Seizures; Striopallido dentate calcinosis

**Citation:** Khalid S, Khan SA, Khan AH, Muhammad G, Khan AA. Fahr's disease in a patient presenting with status epilepticus. J Ayub Med Coll Abbottabad 2020;32(2):280-2.

## INTRODUCTION

Fahr's syndrome or Fahr's disease was first reported in 1930 by German neurologist Karl Theodor Fahr. It is a rare disease that is characterized by abnormal calcified deposits in various parts of the brain most commonly in basal ganglia.<sup>1</sup>

The disease usually manifests in age of 40-60 years with a variety of symptoms including dementia, speech disorders, Parkinsonian features, cerebellar symptoms, convulsive seizures, as well as various neuro-psychiatric symptoms like hallucination and delusions.<sup>2</sup>

The pathogenesis is considered to be idiopathic but may be due to impairment of blood brain barrier or to a neuronal calcium phosphoric metabolism disorder. Some studies also suggest that it has an autosomal dominant inheritance pattern.<sup>3</sup>

Histologically the calcified deposits which contain proteins and polysaccharide are found in the tunica media of small vessels and perivascular space.<sup>4</sup>

CT scan of the brain is most helpful in diagnosis of Fahr's disease. It usually reveals calcification in various parts of the brain most commonly in basal ganglia. It also involves other structures like thalamus, white matter and cerebellum.<sup>5</sup>

The diagnostic criteria include bilateral basal ganglia calcification on neuroimaging, family history consistent with autosomal dominant inheritance, age of onset is usually 4<sup>th</sup> to 5<sup>th</sup> decade or manifested earlier, absence of biochemical abnormalities, infectious, toxic or traumatic cause, progressive neurologic dysfunction or neuropsychiatric manifestation.<sup>3</sup>

## CASE REPORT

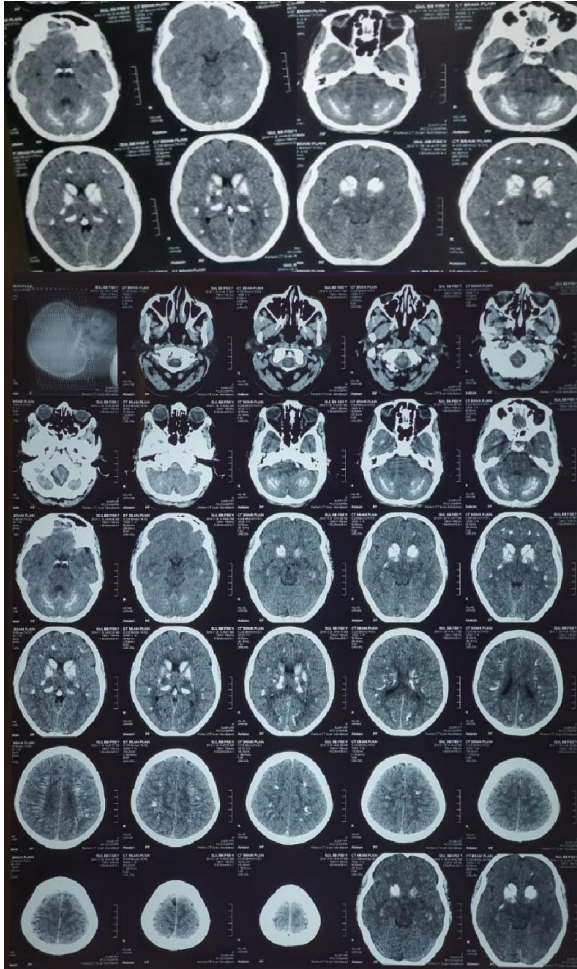
A 50-year-old female was brought by attendants to our unit in status epilepticus. Patient had history of tonic clonic seizures for past 15 years that was not properly investigated. Patient had been taking anti-epileptic medications but was non-compliant. There was no significant family history of epilepsy. On examination her GCS was 11/15, BP. 150/90, pulse 82, temperature 101 °F, respiratory rate of 16 breath/min. Initial laboratory results were within normal limits except for high TLC (13000). ECG was unremarkable. EEG was advised but was not possible because of patient's condition.

CT brain of the patient was done after stabilizing the patient that showed widespread intra cerebral calcifications involving basal ganglia, cerebellum, thalamus and white matter.

On arrival she was given intra venous (IV) diazepam and then started on IV valproic acid, IV levitracetam. Since the patient was not responding the patient was started on Phenytoin at loading dose of phenytoin 1g in 500 ml normal saline followed by maintenance dose of 200 mg in 100 ml normal saline Q12H.

On third day of admission her GCS dropped to 7. Her oxygen dropped, she became tachycardiac, and with decreased respiratory effort the patient was put on ventilator support.

On day 4<sup>th</sup> she was weaned off the ventilator, on day 06 she got single episode of fits in the morning and during this episode patient collapsed. She was again put on ventilator support and resuscitation was started. But the patient did not respond and died.



**Figure-1: CT brain showing bilateral calcification in basal ganglia, cerebrum and cerebellum**

## DISCUSSION

Fahr's syndrome is also known as bilateral striopallido dentate calcinosis or idiopathic basal ganglia calcification. It is characterized by abnormal deposition of calcium (calcium carbonate and calcium phosphate) in various parts of the brain most commonly basal ganglia followed by cerebellum. As shown by CT brain of our case (Figure-1) calcification is typically bilateral and symmetrical, not only involving basal ganglia but also involve cerebral white matter, cerebellar subcortical white matter and thalamus. Disease typically manifest itself in 3<sup>rd</sup> to 4<sup>th</sup> decade of life as evidenced from our case with a variety of neurologic and neuropsychiatric symptoms. Neuropsychiatric symptoms range from difficulty with memory and concentration to changes in behaviour or personality to dementia and psychosis.<sup>6</sup> Patients with widespread calcification usually exhibit a higher frequency of psychiatric disorders than those with limited one. Psychiatric symptoms like compromised memory and attentional functions may occur in patients who remained neurologically asymptomatic. Fahr's syndrome can

manifest with a wide range of neurologic signs and symptoms. Epileptic seizures and loss of consciousness have been reported in adult with hypothyroid hypocalcaemia. But can occur in patient with normal serum thyroid, parathyroid hormones and normal serum calcium level as evidenced in our case. Other neurologic manifestation includes chorea, tremors, myoclonus, dystonia, dementia, speech impairment, spasticity, gait disorder and parkinsonism. Despite bilateral calcification neurologic manifestation may be confined to one side of the body.<sup>7</sup> Kernig reported that one half of the patient with Fahr's syndrome exhibit neurologic symptoms while Kazic reported a figure of 33.8%.<sup>8</sup> Some patients of Fahr's syndrome may present with movement disorders including elusiveness, fatigability, dysarthria, involuntary movement, unsteady gait, muscle cramps and slow or slurred speech. The exact prevalence is not known. Molecular genetics is not clearly understood but may be transmitted as an autosomal dominant, autosomal recessive trait or it may occur sporadically.<sup>9</sup> Calcification usually starts in the vessels wall and perivascular space ultimately extending into the neurons. Tissue damage can occur due to defective iron transport and free radical formation which lead to initiation of calcification. Mineralization of the basal ganglia compress and occlude vessels wall, initiating a cycle of impaired blood flow, neuronal damage and deposition of minerals. CT brain is most useful in diagnosing Fahr's disease. It is preferable in localizing and assessing the extant cerebral calcification. Calcification is gradual and progressive with the lenticular nucleus being most commonly affected. MRI give low signal on T2 and low to high signal on T1 weighted images in area of basal ganglia.<sup>10</sup> Due to reactive gliosis or degenerating tissues with in calcified areas there may be a chance of high signals in both T1 and T2 weighted images.<sup>11</sup> On plain skull radiograph calcification appears as clusters of punctate densities, distributed symmetrically lateral to midline. Cerebellar and subcortical calcifications appear wavy. Early diagnosis and treatment may subside calcification process. Anti-epileptics are used for seizures, oxybutynin for urinary incontinence. dystonia, depression, anxiety and parkinsonism should be treated accordingly. Lithium can increase further risk of seizures. Gait disturbance may be exacerbated by barbiturates, carbamazepine and benzpinine.<sup>12</sup>

## CONCLUSION

Fahr syndrome should be suspected in patients presenting with seizures, loss of consciousness or those with status epilepticus with bilateral symmetrical calcification of basal ganglia on neuroimaging. CT brain should be done in all cases

presenting with seizures, episodic loss of consciousness or those with status epilepticus once stabilized. Secondary causes of cerebral calcification should be ruled out by proper investigations. Family history as included in the diagnostic criteria is not always present as evidenced in our case. There is no relation between seizures and serum calcium, PTH and thyroid hormone in case of Fahr's disease.

## REFERENCES

1. Fahr T. Idiopathische verkalkung der hirngefäße. *Zentrabl Allg Pathol* 1930;50:129–33.
2. Saleem S, Aslam HM, Anwar M, Anwar S, Saleem M, Saleem A, *et al.* Fahr's syndrome: Literature review of current evidence. *Orphanet J Rare Dis* 2013;8:156.
3. Mufaddel AA, Alhassani GA. Familial idiopathic basal ganglia calcification (Fahr's disease). *Neurosciences* 2014;19(3):171–7.
4. Malik R, Pandya VK, Naik D. Fahr's disease: A rare neurodegenerative disorder. *Indian J Radiol Imaging* 2004;14(4):383–4.
5. Manyam BV, Bhatt MH, Moore WD, Devleschoward AB, Anderson DR, Calne DB. Bilateral striopallidodentate calcinosis: cerebrospinal fluid, imaging, and electrophysiological studies. *Ann Neurol* 1992;31(4):379–84.
6. Geschwind DH, Loginov M, Stern JM. Identification of a locus on chromosome 14q for idiopathic basal ganglia calcification (Fahr disease). *Am J Hum Genet* 1999;65(3):764–72.
7. Arias Mayorga J, González Martin T, Escorial Miguel C, Marañón Cebello A. Intracranial calcifications in the differential diagnosis of epileptic disease. *Rev Clin Esp* 1991;189(9):425–7.
8. Kazis AD. Contribution of CT scan to the diagnosis of Fahr's syndrome. *Acta Neurol Scand* 1985;71(3):206–11.
9. Yamada N, Hayashi T. Asymptomatic familial basal ganglia calcification with autosomal dominant inheritance: a family report. *No To Hattatsu* 2000;32(6):515–9.
10. Kobari M, Nogawa S, Sugimoto Y, Fukuuchi Y. Familial idiopathic brain calcification with autosomal dominant inheritance. *Neurology* 1997;48(3):645–9.
11. Avrahami E, Cohn DF, Feibel M, Tadmor R. MRI demonstration and CT correlation of the brain in patients with idiopathic intracerebral calcification. *J Neurol* 1994;241(6):381–4.
12. Sobrid SH MJ, Geschwind DH. Familial Idiopathic Basal Ganglia Calcification: GeneReviews™ [Internet]. Seattle (WA): University of Washington, Seattle; 2004. Updated 2007 Sep 20. [cited 2020 Feb]. Available from: <http://canglish1.tripod.com/Calcification.htm>

Submitted: February 22, 2020

Revised: March 2, 2020

Accepted: May 12, 2020

## Address for Correspondence:

Shah Khalid, Department of Neurosurgery, Ayub Medical College, Abbottabad-Pakistan

Email: shahkhalid23230@gmail.com