

ORIGINAL ARTICLE

PROXIMAL FEMUR HISTO-MORPHOLOGICAL CHANGES AMONG HIP FRACTURE IN ELDERLY PATIENTS

Wajid Akbar, Humaira Imtiaz*, Amna Halima, Sumaira Javed*, Ayesha Naureen*, Usman Ali

Department of Anatomy, Bacha Khan medical College, Mardan, *Department of Anatomy, Ayub Medical College, Abbottabad-Pakistan

Background: Hip fracture causes high morbidity in elderly. Decreased bone mineral density is associated with hip fracture risks. The study is conducted to identify relationship of histo-morphological changes in proximal femur in the cases of hip fractures in elderly with histo-morphological changes in proximal femur. **Methods:** A total of 30 elderly patients with hip fracture were studied in this case series. The study was carried out in Orthopaedic and Pathology departments at Mardan Medical Complex from May 2014 to October 2014. Specimen during surgery, were collected for histopathological study. **Results:** Bone biopsy of hip fracture cases revealed cortical thinning, reduced number of osteocytes, thinning and fragmentation of trabeculae. **Conclusion:** This study concluded that bone micro architectural changes seems to be associated with the risk of hip fracture.

Keywords: Proximal femur; Histo-morphology; Hip fracture

Citation: Akbar W, Imtiaz H, Ali U, Javed S, Halima A, Naureen A . Proximal femur histo-morphological changes among hip fracture in elderly patients. J Ayub Med Coll Abbottabad 2020;32(1):91–3.

INTRODUCTION

Hip fracture causes morbidity and mortality in old age. The global incidence of hip fracture is on a constant rise and is estimated to increase from 1.9 million in 1990 to 6.26 million in 2050.¹ The frequency of hip fracture in elderly reported as 3 fractures per 10,000 populations per year.² In men the age related sub-periosteal growth is more prominent as compared to women, while cortical thinning is the opposite.³ Bone mineral density (BMD) quality and microarchitecture, are responsible for bone strength. The two predominant parameters that can indirectly judge bone durability are bone mineralization and porosity.⁴⁻⁵

Since 1960 histological cross-sections of specimen have been utilizing for the scrutiny of bone microarchitecture, trabecular design and porosity as well as cellular pathway of cortico-trabecular bone.^{6,7} With increasing age, 6.4% of cortical thinning takes place per year especially in superior location of femoral neck. It is more prominent in superior-posterior octant of the head of femur in females. Age and sex have significant consequence on cortical porosity, with advanced age cortical pore calibre dilates with no compelling alteration in pore number. A study explained that women have higher cortical porosity and greater pore diameter in contrast to men.^{8,9} There is apparent dissymmetry in trabecular bone arrangement in the proximal femur, characterized by five groups of trabeculae; principal compressive, principal tensile secondary tensile, secondary compressive and greater trochanteric trabeculae. Trabecular connectedness is associated

with a decrease in bone mineral density, their loss or disconnectedness rises the risk of hip fracture commonly in postmenopausal women with osteoporosis.¹⁰

This study is conducted to observe histological changes in both cortical and trabecular bone of hip fracture in elderly Pakistani population. The study also identifies relationship of histo-morphological changes in proximal femur in the cases of hip fractures in elderly with histo-morphological changes in proximal femur.

MATERIAL AND METHODS

This case series was conducted in the departments of Pathology and Orthopaedics Mardan Medical Complex during the year 2014 from May to October. Total of 30 patients (male and female) with hip fracture and planned arthroplasty were included in the study.

Patients gave Informed consent and detail history was taken. During the arthroplasty of the fracture site, the curetted bone samples were obtained for histological examination. The bone tissue fragments taken from head and neck of the femur, were decalcified in 5% nitric acid and then cut with a diamond blade. Five mm section from the sample, containing both cortical and cancellous bone were sectioned and were subjected to pass through a series of alcohol washes in order to be defatted. The sample was than embedded in paraffin, and section of 5–7 micrometre using microtome were cut, slides were stained with haematoxylin and Eosin. Data was analysed using SPSS 20.0.

RESULTS

Hip fracture biopsies showed variable osteoporotic changes. These changes were different from one area to another in the same bone. Bone disruption was seen with few thin, parted bone rods. (Figure-1)

Cortical bone showed thin parallel osseous lamellas. Number of osteocytes were reduced. Osseous tissue had different tinctroality from one bone fragment to another. (Figure-2)

Uneven decalcification of bone was due to variation in mineral salt content in different area of the same bone; bone distribution was seen with few thin parted bone rods. Trabecular bone showed few empty osteoplast as shown in Figure-3

Necrosis was seen causing thinning and fragmentation of trabeculae. Areolar spaces were large irregular filled with red or yellow osseous marrow (Figure-3). Inflammation was not present.

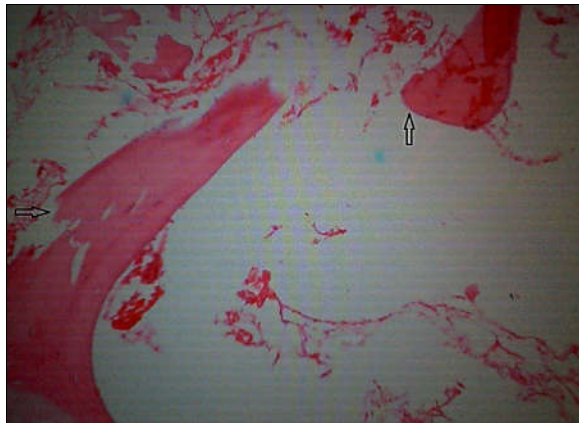


Figure-1: A photomicrograph of biopsy section of bone, arrows showing bone disruption with thin, parted bone rods (Haematoxylin-Eosin stain, X100)

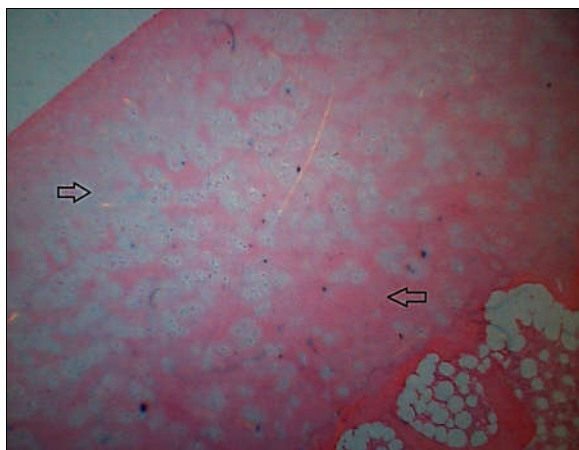


Figure-2: A photomicrograph of biopsy section of bone, arrows showing different staining in bone tissue can be seen (Haematoxylin-Eosin stain, X100)

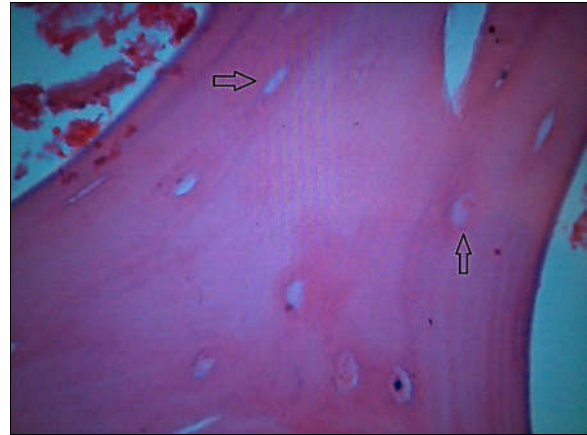


Figure-3: A photomicrograph of biopsy section of bone, arrow showing trabecular bone with few, empty osteoplasty. (Haematoxylin-Eosin stain, X100)

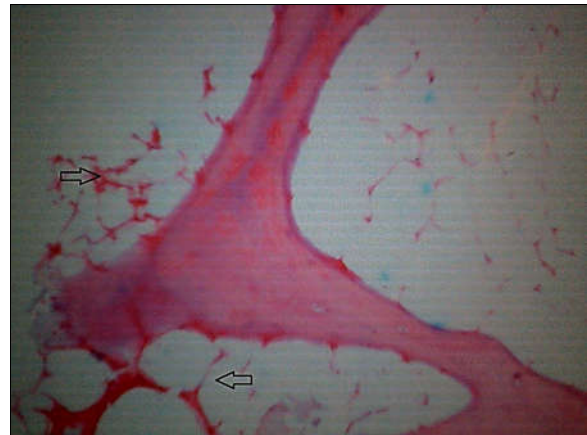


Figure-3: A photomicrograph of biopsy section of bone, arrow showing large areolar spaces filled with osseous marrow (Haematoxylin-Eosin stain, X100)

DISCUSSION

Hip fracture contributes to high morbidity and fatality among people mostly in old age. Reduction of bone mass leads to deteriorations of bone microarchitecture and fragility, therefore bone mineral density is a risk factor for fracture which is an added cause of risk estimation. The gold standard to conclude the vicinity of osteoporosis and osteomalacia is bone histomorphology. In our study the biopsies of cases with hip fracture showed cortical thinning, red creased number of osteocytes, less dense and disintegration of trabeculae, which is consistent with the results of Indo-Pak subcontinent study of 26 hip fracture patients, which reported increase percentage (65%) of sever osteoporosis amid hip fracture cases.¹¹ A study conducted in Japan reported that stroke patients with osteomalacia are probably more prone to hip fracture than patients with no osteomalacia.¹² More such studies are

required with different design to study the phenomenon in detail in our population.

CONCLUSION

Osteoporotic alterations in bone biopsy taken from elderly patient with risk of hip fracture imply a valuable factor in the assessment of hip fracture risks. However further studies needed to clarify this conclusion.

AUTHORS' CONTRIBUTION

WA: Literature search, Conceptualization. HI, SJ: Conceptualization of study design, data collection and analysis. Amna, AN, UA: Data interpretation, write-up and proof reading.

REFERENCES

1. Cooper C, Cole ZA, Holroyd CR, Earl SC, Harvey NC, Dennison EM, *et al.* Secular trends in the incidence of hip and other osteoporotic fractures. *Osteoporos Int* 2011;22(5):277–88.
2. Adnan RM, Zia MI. Frequency of femoral fractures; comparison in patients less than and more than 40 years of age. *Professional Med J* 2012;19(1):911–4.
3. Farmer ME, White LR, Brody JA, Baily KR. Race and sex differences in hip fracture incidence. *Am J Public Health* 1984;74(12):1374–80.
4. Heaney RP. Is there a role for bone quality in fragility fractures? *Calcif Tissue Int* 1993;53(Suppl 1):S3–6.
5. Schnitzler CM. Bone quality: a determinant for certain risk factors for bone fragility. *Calcif Tissue Int* 1993;53(Suppl 1):S27–31.
6. Parfitt AM, Mathews CH, Villanueva AR, Kleerekoper M, Frame B, Rao DS. Relationships between surface, volume and thickness of iliac trabecular bone in aging and in osteoporosis. *J Clin Invest* 1983;72(4):1396–409.
7. Poole KES, Mayhew PM, Rose CM, Brown JK, Bearcroft PJ, Loveridge N, *et al.* Changing structure of the femoral neck across the adult female lifespan. *J Bone Miner Res* 2010;25(3):482–91.
8. Mayhew PM, Thomas CD, Clement JG, Loveridge N, Beck TJ, Bonfield W, *et al.* Relation between age, femoral neck cortical stability, and hip fracture risk. *Lancet* 2005;366(9480):129–35.
9. Chappard C, Bensalah S, Olivier C, Gouttenoire PJ, Marchadier A, Benhamou C, *et al.* 3D characterization of pores in the cortical bone of human femur in the elderly at different locations as determined by synchrotron micro-computed tomography images. *Osteoporos Int* 2013;24(3):1023–33.
10. Compston JE, Mellish RW, Garrahan NJ. Age-related changes in the iliac crest trabecular microanatomic bone structure in man. *Bone* 1978;8(5):289–92.
11. Hafeez F, Ahmad M, Hasan S, Kurshid R. Bone strength and its determinants in peri-and postmenopausal women. *Pak J Physiol* 2011;7(1):37–9.
12. Tucker GS, Middha VP, Sural A, Sagreiya K. Incidence of osteomalacia in fractures of the proximal end of femur. *Injury* 1988;19(2):89–92.

Submitted: 22 August, 2019

Revised: 28 September, 2019

Accepted: 18 December, 2019

Address for Correspondence:

Dr. Wajid Akbar, Asstt. Prof. Anatomy Department, Bacha Khan Medical College, Mardan-Pakistan

Cell: +92 3009176437

Email: drwajidakbar@yahoo.com