

CASE REPORT

ECTOPIC WARTHIN'S TUMOUR MASQUERADING AS INFECTED BRANCHIAL CYST

Nadeem Ahmed Sheikh, Syeda Saadia Gilani, Nouman ul Haq Raja*, Kanwal Nadeem**

Department of ENT, Combined Military Hospital, Abbottabad, *Tehsil Headquarters Hospital, Kallar Syedan, Rawalpindi, **Army Burn Hall College (for girls), Abbottabad-Pakistan

Salivary gland tumours are relatively uncommon but they present globally regardless of age. Most of these tumours are benign and involve the parotid gland. Though strictly confined to the parotid gland, Warthin's tumours can exceptionally present at an ectopic site of head and neck. Of particular significance is its striking similarity with a lymph node, an inclusion cyst, branchial cyst or a malignant mass, especially when it presents in the upper cervical region.

Keywords: Salivary gland; Branchioma; Head and neck neoplasms, Warthin's Tumour

Citation: Sheikh NA, Gilani SS, Raja NH, Nadeem K. Ectopic Warthin's tumour masquerading as infected branchial cyst. J Ayub Med Coll Abbottabad 2019;31(3):459-60.

INTRODUCTION

Warthin's tumour also known as papillary cystadenoma lymphomatosum or adenolymphoma is the second commonest benign salivary gland tumour after pleomorphic adenoma, usually involving the parotid gland. Salivary gland tumours comprise 3-4% of all head and neck tumours, with 70% involvement of the parotid gland.¹ Minor salivary glands and the submandibular glands follow in order of 22% and 8%, respectively.² Warthin's tumors make 14% of all parotid lumps and 0.8% of submandibular gland masses.³ Regional demographic data corresponds to international literature.⁴ Very rare heterotopic appearances of this tumour in the parathyroid, thymus, larynx and the nasopharynx have been reported in western literature.^{5,6} Concurrently, sparse regional and nation-wide knowledge is available highlighting serendipitous detection of these heterotopic salivary gland tumours.

CASE REPORT

We received a 50-year-old married lady in outpatient on account of a lump in the right side of her upper neck for over past 6 years. It was of the size of an egg and caused her a dull aching pain. Without any known predisposing factor, the lump insidiously grew in size. On examination, we found a solitary, firm, ovoid lump in the right carotid triangle. It did not move with swallowing or tongue protrusion. The overlying and surrounding skin were normal. Temperature felt normal and the lump was non-tender. It had smooth contours and ill demarcated margins. The swelling was not tethered to overlying skin and underlying structures. It was non-pulsatile, non-fluctuant, incompressible and irreducible. It measured 4.5×3 cm in maximum dimensions. No bruit was audible over the lump. A provisional diagnosis of right sided branchial cyst was established and necessary investigations were

ordered. Fine needle aspiration cytology revealed the possibility of infected branchial cyst with squamous metaplasia and reactive atypia; inflamed epidermal inclusion cyst or a cystic squamous cell carcinoma.

We performed surgical exploration for complete extirpation of the lump through a right sided submandibular incision placed over the horizontal axis of swelling. Sub-platysmal dissection was continued and sternocleidomastoid muscle was retracted posteriorly. We continued the dissection around the lump, whereupon, the lump was found to be arising from the carotid sheath. The latter was carefully opened to reveal the right internal jugular vein. The lump was excised in toto and sent for histopathology. We placed a drain and closed the wound in layers. The patient was released from hospital on 2nd post-operative day.

Post-operative histopathology confirmed the mass to be a right upper cervical Warthin's tumour. Microscopically the specimen was found to be encapsulated with cystic and solid areas composed of epithelial and lymphoid components.

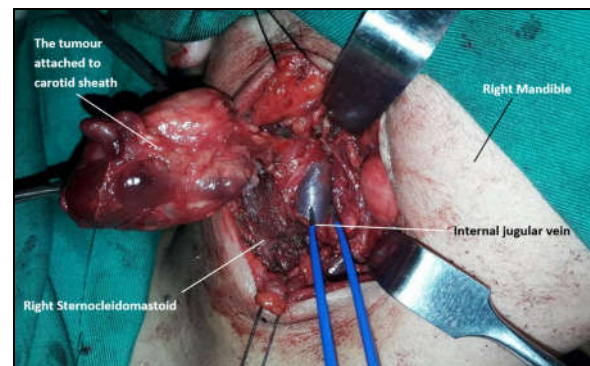


Figure-1: Tumour attached to right carotid sheath

DISCUSSION

The 'multi-cellular' theory of origin of salivary tumours postulates that any of the cellular

components of the salivary gland can undergo anomalous transformation.⁷ Whereas later on, a more accepted consensus developed on embryologic migration and entrapment of salivary epithelial cell rests from the oral mucosa into peri and intra-parotid lymph nodes in 6–8th gestational week. Warthin's tumour is assumed to be originating from these epithelial inclusions. And this perhaps is the only sound description of extra-parotid and multi-centric location of these tumours.

First coined by Aldred Scott Warthin in 1929, Warthin's tumours are slow growing benign masses arising in the tail of parotid in elderly males. 10% are bilateral but metachronous. Heterotopic Warthin's tumours have been narrated by Xu *et al*, Berrocal *et al*, Iwa T *et al*, Synderman and Johnson, and Pelucchi *et al*. In some of these accounts, the tumour was found to be present as multifocal ipsilateral or contralateral cervical lump or in the nasopharynx.^{6,8} Kotrotsos and Giotaki mentioned a solid tumour in the left laryngeal ventricle without mucosal invasion in an 80 years old male.⁵ Very infrequently they may co-exist with an internal or external laryngocele.⁹ Gleeson and Cawson contested the possibility of ectopic Warthin's tumour at other sites of head and neck by representing them as a misdiagnosis.¹⁰ But histologic circumscription with a characteristic eosinophilic glandular epithelial component with lymphocytic stroma in the shape of follicles and cysts in these unusual masses is indicative.

Foregoing in view, a possibility of lymph node, inclusion cyst or malignancy must always be borne in mind. This report aims at bringing around awareness amongst medical practitioners about the

rare heterotopic presentation of this common salivary gland tumour in the neck, thereby instilling a new perspective of rightly diagnosing and managing these cervical masses.

REFERENCES

1. Zaman S, Majid S, Chugtai O, Hussain M, Nasir M. Salivary gland tumours: a review of 91 cases. J Ayub Med Coll Abbottabad 2014;26(3):361–3.
2. Bradley PJ. Frequency and histopathology by site, major pathologies, symptoms and signs of salivary gland neoplasms. In: Salivary Gland Neoplasms. Karger Publishers, 2016; p.9–16.
3. Kalita L, Nath AK. Pattern of salivary gland tumours in a tertiary care hospital in North Eastern India. J Evol Med Dent Sci 2016;5(66):4699–703.
4. Khattak MS, Ahmad S, Noman N. The histopathological pattern of salivary gland tumors. Gomal J Med Sci 2016;14(4):203–7.
5. Kotrotsos IN, Giotakis EI. Multifocal Occurrence of Warthin's Tumor in Both Parotid Glands and in the Larynx. J Otolaryngol ENT Res 2015;2(3):00023.
6. Xu W, Lu H, Zhu Y, Ruan M, Zhang C, Yang W, *et al*. Warthin's tumour in oral and maxillofacial regions: an 18-year retrospective study of 1084 cases in an eastern-Chinese population. Int J Oral Maxillofac Surg 2018;47(7):913–7.
7. Alali F, Kochaji N. Proliferative Activity of Myoepithelial Cells in Normal Salivary Glands and Adenoid Cystic Carcinomas Based on Double Immunohistochemical Labeling. Asian Pac J Cancer Prev 2018;19(7):1965–70.
8. Ory M, Eran A. Synchronous parotid and nasopharyngeal Warthin tumor. Head Neck 2016;38(3):E71–2.
9. Nisa L, Landis BN, Salmina C, Ailianou A, Karamitopoulou E, Giger R. Warthin's tumor of the larynx: a very rare case and systematic review of the literature. J Otolaryngol Head Neck Surg 2015;44(1):16.
10. Gleeson M, Cawson R. Benign salivary gland tumours. In: Gleeson M, editor. Scott-Brown's Otorhinolaryngology Head and Neck Surgery, 7th ed. London: Hodder Arnold, 2008; p.2475–91.

Submitted: 15 May, 2019

Revised: --

Accepted: 17 June, 2019

Address for Correspondence:

Nadeem Ahmed Sheikh, Asstt. Prof. Department of ENT, Combined Military, Hospital, Abbottabad-Pakistan

Email: nadeem_ent75@yahoo.com