

ORIGINAL ARTICLE

COMPARISON OF MICROVASCULAR FREE TISSUE TRANSFER IN ADULT AND PAEDIATRIC PATIENTS

Haroon Ur Rashid, Mamoon Rashid, Ishtiaq Ur Rehman, Shumaila Yousaf, Nasir Khan, Aqsa Akhtar, Farhan Ahmad Eitezaz

Department of Plastic Surgery, Shifa International Hospital, Islamabad-Pakistan

Background: Free tissue transfer is a routine practice in adults with good success rates. Further advances in techniques and microsurgical skills have proved that free tissue transfer in paediatric population is feasible, reliable and safe. **Methods:** This study is conducted to compare anastomosis duration, total general anaesthesia duration, hospital stay and outcomes of flaps (survival, partial loss, complete loss, complications) in paediatric group (age <15 years) and adult group (15–70 years age). All patients with large soft tissue defects, congenital defects, traumatic defects and post tumour extirpation were included in this study from December 1st 2017 to May 30th 2018. These patients underwent different microsurgical procedures, the reconstructive armamentarium included use of Latissimus dorsi flap, Anterolateral thigh flap, Fibula flap, Radial forearm flap, functioning Gracilis muscle, iliac crest flap, deep inferior epigastric artery perforator flap and Rectus abdominis muscle flap. Post-traumatic defects were the commonest indication of free tissue transfer in Paediatric population while post tumour extirpation defects were commonest defects encountered in adult population. **Results:** On average the total anaesthesia duration is slightly shorter in paediatric group than in adult patients while anastomosis duration is slightly shorter in adults than in paediatric patients. The overall complication rate is comparable in both groups and all the flaps survived well. **Conclusion:** Microsurgical free tissue transfer can be confidently attempted in children and their results are comparable with those of adult group.

Keywords: Free tissue transfer; Paediatric free flaps; Comparison of free flaps; Free flaps in younger; Adults versus paediatric free flaps.

Citation: Rashid H, Rashid M, Rehman I, Yousaf S, Khan N, Akhtar A, *et al.* Comparison of microvascular free tissue transfer in adult and paediatric patients. J Ayub Med Coll Abbottabad 2019;31(2):156–61.

INTRODUCTION

In an ideal situation a most updated reconstructive surgeon would prefer free tissue transfer because it gives durable and pliable wound coverage, superior functional and aesthetic results, with low donor site morbidity, and the luxury to customize vascularized tissue from distant parts of the body and which are away from zone of injury. The possibility of free tissue transfer in children was first described in 1970s by Harii and Ohmori.^{1,2} The basic principles of microsurgery in any age group are same but children should not be treated as miniature adults.³ Free flap reconstruction in children is often undertaken with trepidation due to a variety of perceived technical difficulties and variable reports of success. The main concerns include small calibre vessels, short length pedicle, prolonged surgery, per operative blood loss and post-operative morbidities. However different authors have reported success and complication rates in paediatric group comparable with the adult group. The feasibility and reliability of free tissue transfer in children was demonstrated well by free perforator-based flaps in 2005.⁴ Replantation of big toe in a 3 months old child has been reported and toe survived.⁵ Shifa international hospital is a tertiary care hospital

where largest number of patients received every month which are candidates for free tissue transfer. This series compares the use of free tissue transfer in children versus adults and demonstrates that free flaps are equally efficacious in children in providing the majority of these patients with a successful one stage reconstruction with morbidity similar to that reported for adult patients.

MATERIAL AND METHODS

Thirty adults (females n=19, males n=11 above 15 years age) and twenty children (females n=11, males n=9 under the age of 15 years) were treated in Shifa International Hospital Islamabad, Plastic and reconstructive surgery department from 1st December 2017 to 30th May 2018. All those cases in which double free flap was done or in cases where more than 2 teams involved were excluded from study. The indications for free tissue transfer included traumatic defects, congenital defects, post tumour extirpation and acquired defects after debridement. All microsurgical procedures were performed by same team and under general anaesthesia. Angiograph was obtained in complex trauma wounds and congenital anomalous conditions for recipient vessels status.

Pre-operative prophylactic systemic low molecular weight was given subcutaneously to all patients 3–4 hours before surgery. Magnification loupes of 4x were used in all cases. One artery and two veins were anastomosed in 23 (paediatric n=4 and adult n=19) patients. We employed interrupted sutures in all anastomosis. Ethilon 9–0 and 10–0 suture was used in anastomosis. Intraoperative heparin was infused according to body weight before pedicle division after flap harvest. We compared the total anaesthesia duration, anastomosis duration and outcomes in both groups. Operating room temperature was set to 26 degrees Celsius throughout the procedure to avoid any vasoconstriction. A peripheral venous line, an arterial line and urinary catheter were passed in all patients undergoing free tissue transfer procedures. Per-operative blood loss, urine output and electrolyte balance were critically monitored by an anaesthetist. Perioperative antibiotic and appropriate analgesia provided to all patients. Aspirin was started the same day according to patient's body weight. Post-operatively flap was monitored by on call resident every one-hour intervals initially for first 3–4 days, clinical indicators like flap colour, temperature and scratching with 27' gauge needle were the mainstay protocols for monitoring. In cases where anastomosis site was in subcutaneous plains, hand held doppler was also used for monitoring.

DISCUSSION

The basic principles of microvascular free tissue transfers for adult and paediatric patients are same but the absence of associated comorbidities and other risk factors in children (e.g. advanced age, diabetes, hypertension, ageing heart, drug abuse and other systemic conditions) also favours healthy recovery of these young patients. In children hypothermia risk, blood loss, fluid and electrolytes imbalance need much efforts to be monitored and managed. Another challenge is the length of the pedicle that should be good enough to reach recipient vessels. In children vessels have adequate size, although previously believed to be near impossible to anastomose due to their size and repeated spasms.⁶⁻⁹

Selection of vessels for anastomosis is crucial for successful outcome and to avoid complications. Gilbert stated that lower limit of vessel size for anastomosis is 0.7 mm, and smaller than that should be avoided but there are multiple reports of successful anastomosis of vessels with size as small as 0.3 mm.¹⁰ In our study of paediatric patients' vessels size and pedicle length was adequate enough to be anastomosed precisely and away from the zone of injury, or reach the recipient vessels. The difficulty experienced during anastomosis was inversely proportional to the age of the patient, but sizable vessels (≥ 0.8 mm) were found in all

cases of paediatric population. These findings were comparable with Van Landuyt *et al* who demonstrated in his study that the vessel size in children is larger as compared to their physique, and compared with adults making anastomosis more feasible.⁴ Serletti *et al* stated that patients aged between 13–17 years had vessel properties closer to that of adults.¹¹

At times after selection of appropriate vessels for anastomosis, surgeon may face another hurdle in the form of vasospasm. Vasospasm, if occurs also make the anastomosis difficult and so increases anastomosis duration. Gentle atraumatic handling of vessels is key to avoid vasospasms. The muscularis layer of vessels in paediatric group are not well developed and so less chance of vasospasm.⁶ In our study we experienced only 3 (out of 20 paediatric) cases in which there was transient vasospasm, although plenty of local vasodilator solution (lidocaine 2 %, papaverin) irrigated during anastomosis. In adult group 26 (out of 30) patients had vasospasm preoperatively. Yucel *et al* noted the same characteristics in their study, as the vessel were more muscular and elastic in older children, and vessels in younger children were more thin jelly like and relatively low muscle maturity in vessel wall hence decreasing the chances of vasospasm.¹²

In our study the time taken for anastomosis of vessels in both adult and paediatric groups is comparable. Mean anastomosis duration in paediatric group was 12.60 ± 2.349 while in adults it was 14.07 ± 3.095 minutes (with $p=0.078$). The mean anaesthesia duration in paediatric group was $415.85 \pm 55,865$ minutes that was comparable with adult group 433.93 ± 59.78 minutes ($p=0.288$). This is comparable with international studies, such as Pinder *et al* who recorded total anaesthesia duration ranged from 170–570 minutes (median of 330 minutes).¹³

To keep the procedure smooth and familiar for operating room staff, same anaesthetist was appointed in all cases and same assisting technicians for both adult and paediatric free flaps. The overall operation room was kept warmed to maintain body core temperature of patients and avoid vasospasms. Children can tolerate longer anaesthesia than adults.¹⁴ Before surgery all paediatric and adult patients were seen by an anaesthetist and all the required preop assessment was done.

Post operatively all patients especially children were kept warm, pain free and comfortable, because these are the prime factors affecting flap behaviour and so outcome. All patients were accompanied by anaesthetist while shifting to floor or intensive care unit and adjusting their analgesia needs critically. Invasive monitoring continued for first two days, and lines and catheters were removed after 48 hours. All patients were mobilized on 1st post-operative day. Parents and attendants were familiarized with the care of patient and

flap, so that can be useful when patient is released from hospital.

One of the main considerations in paediatric free tissue transfer is the growth of tissues being harvested and transferred. Chiang *et al* observed no significant difference in growth rate between cutaneous, myocutaneous and muscle only flaps.¹⁵ All the tissues continue to grow in children with subtle lag as compared to normal expected growth. There are various studies which state that the growth pattern is in normal range.¹⁶⁻¹⁸ So far in 6 months of follow up our paediatric population had no retardation or discrepancy in growth of tissues transferred and no donor site morbidity noticed, on the other hand adult group population had 3 cases with mild contractures of grafted sites and 2 cases with scar ulceration at weight bearing areas. This can be attributed to Horowitz *et al* who stated that children are capable of early rehabilitation by adopting to new weight bearing surfaces and so rarely they develop ulcerations.¹⁹ Parry SW and Kontilla E found that the results of free tissue transfer in children and adults were almost similar.^{6,20} In all 22 cases of Parry *et al* noted shorter duration of surgery and early functional recovery, with no vasospasm in any paediatric patient per operatively.⁶

Yildirim *et al* presented a series of 25 patients with different reconstructive procedures in children, in which the survival rate in free tissue transfer was 93% (13 of 14 patients), one free latissimus dorsi flap failed due to arterial occlusion. Anastomosis was revised but no reflow phenomenon observed.²¹ In another study performed by Keith E. Blackwell, the survival of free flaps in adults was 99.2%.²² In our study two of the flaps got congested from both groups and were salvaged by removing thrombus from vein and anastomosis was revised. We set protocols for flap monitoring and in case of congestion, initially release of few of the tension sutures and opening of dressings were done, otherwise flap re-exploration was done. In our series of patients flap survival was 100% both in adult and paediatric groups. Timely diagnosing and shifting patient to operating room raises survival chances. In cases where vessels anastomosis were revised per op and post op heparin was infused according to patient's body weight for next 5 days. In our study secondary day care procedures like flap debulking (adult n=3, paediatric n=2), scar revisions (adult n=2, paediatric n=2), contractures release (adult n=1, paediatric n=0) and muscle tension re-adjustment (adult n=2) was done.

El-Gammal *et al* in 2013 published his experience of 42 paediatric patients (reconstruction was done with ALT flap) in which he had 2 partially lost flaps and 1 completely lost flap, with minor complications.²³ Similarly Acar *et al* in his series of 11 (reconstruction was done with ALT flap) paediatric patients only had one partial loss of flap.²⁴ In addition to

these other studies also show that free tissue transfers in children are comparable to that of adult group in terms of success rate, safety and effectiveness.^{25,26} Our study also follows the same pattern of outcomes. The indications for free tissue transfer in paediatric group is not same as in adults, in this series the most common indication was post tumour extirpation in adult group while in paediatric patients post traumatic defects were the most common. Refinement in microsurgical instruments and techniques has led to satisfactory results in free tissue transfer in paediatric patients.^{12,27-29} Children tolerate longer anaesthesia durations and have a superior wound healing and functional recovery compared to adults.^{14,25,26}

RESULTS

Over the last 6 months a total of 50 microsurgical procedures were done which included 30 adults (females n=19, males n=11 above 15 years age) and 20 children (females n=11, males n=9 under the age of 15 years) shown in table-1. In paediatric group three patients (15%) underwent free tissue transfer as emergency procedures and seventeen patients (85%) underwent elective free tissue transfer while in adult group all patients underwent elective surgeries. The age of paediatric group ranged from 4 to 14 years with mean age 9.3 ± 3.097 years. The age of adult patients ranged from 18 to 68 years with a mean of 40.23 ± 13.467 years. The most common free flap in adult age group was Radial forearm flap (n=15) and in children Anterolateral thigh flap (n=10) was the most frequent. In adults the most common indications were head and neck carcinomas and soft tissue sarcomas while in children post trauma limb defects were common scenarios. The mean hospital stay in paediatric patients was 5.3500 ± 0.815 days while in adult group 5.2667 ± 0.9444 days ($p=0.646$). The mean total anaesthesia duration in adult patients was 433.93 ± 59.789 minutes and in paediatric patients mean anaesthesia duration was 415.85 ± 55.865 minutes ($p=0.288$). Mean anastomosis duration in paediatric group was 12.60 ± 2.349 while in adults it was 14.07 ± 3.095 minutes (with $p=0.078$) as shown in table-2. In adult free flaps complications included partial graft loss (n=1), neck hematoma (n=1), donor site hematoma (n=1), tendon exposure with partial graft loss (n=1), venous thrombosis (n=1) and urethral dehiscence (n=1) in a phalloplasty patient. In paediatric free flaps patient's donor site hematomas (n=1), wound infection (n=2), wound dehiscence around flap (n=1), partial graft loss (n=1) and venous thrombosis (n=1) shown in figure-1. All the complications were conservatively managed except for the congested flaps which were re-explored and salvaged by revising venous anastomosis. Two of the thirty adult patients were shifted in intensive care unit immediately after surgery for close monitoring due to

raised blood pressures, which were optimized in a day. All of the paediatric patients had smooth recovery from anaesthesia. All the patients were closely followed for a month every weekly. In paediatric group the maximum follow-up was 6 months and minimum follow up was 1 week, while

in adult group the maximum follow-up was 6 months and minimum follow up was 10 days. In patients where vascularized bone flap was used, there was satisfactory union at flap and native bone junction.

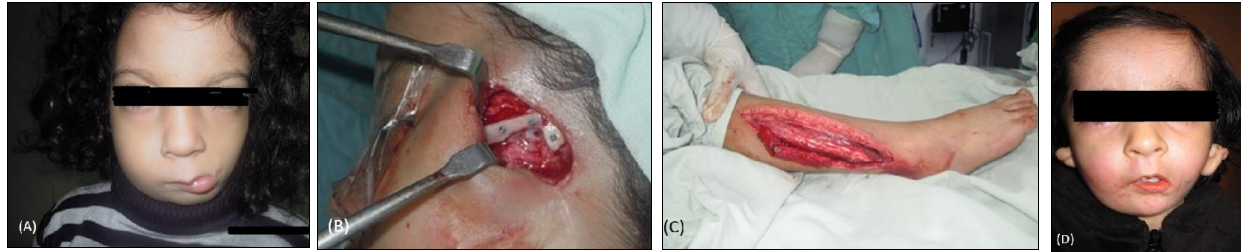

Figure-1: (A) 4-year-old girl with left sided Pruzansky's type III mandibular hypoplasia (B) Temporomandibular joint reconstruction with rib cartilage graft. (C) Free fibula flap harvest for mandibular reconstruction. (D) Post operatively good symmetry achieved.

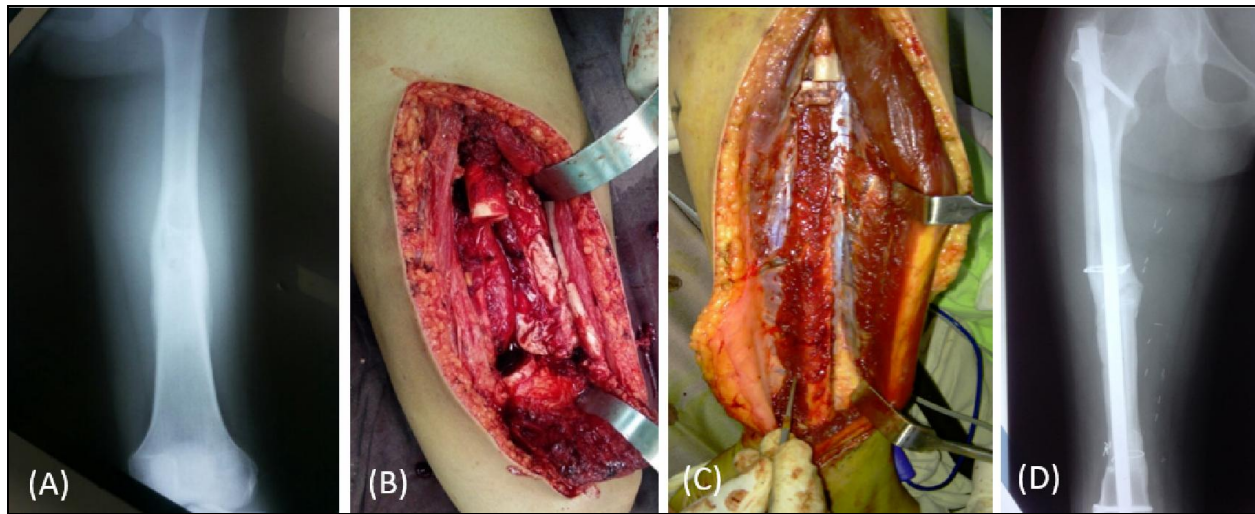


Figure-2: A 12-year-old girl with osteosarcoma right femur (B) Wide local excision of tumour and resultant defect in femur (C) Free fibula flap for femur middle segment reconstruction (D) Radiograph at 6 months follow up, good union of bone ends

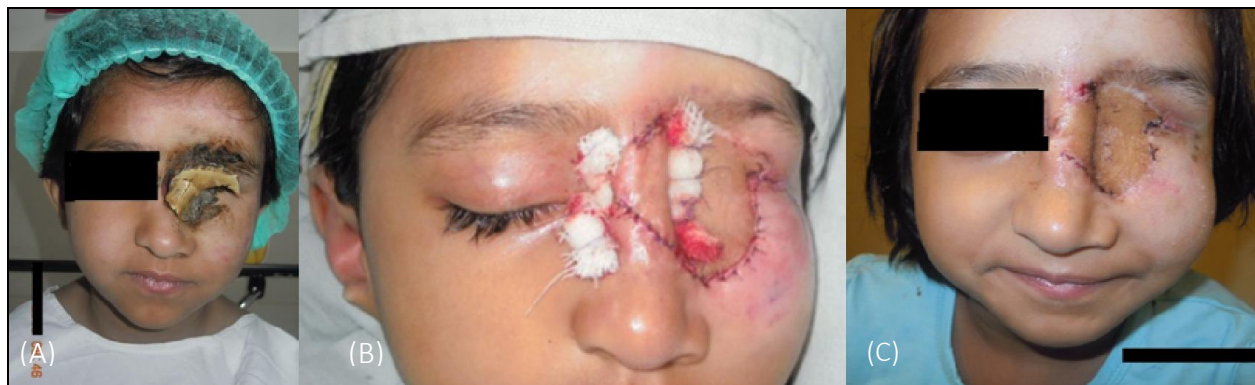

Figure-3: (A) A 7-year-old girl with left orbital mucormycosis secondary to ALL. (B) Radial forearm free flap and rib cartilage graft for redix of nose and lid reconstruction. (C) Early follow up picture with good contour and ready for socket creation surgery.

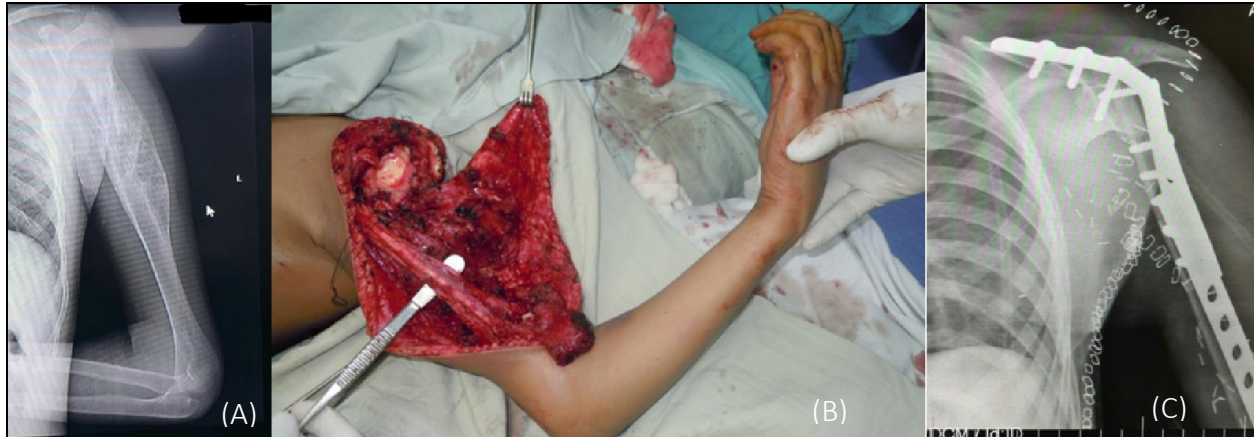

Figure-4: (A) Radiograph of a 12-year-old boy with left humerus Ewings Sarcoma. (B) Wide local excision of tumour and salvage of neurovascular bundle (C) Free fibula flap for humours reconstruction, good union at 5 months follow up.

Table-1: The population data.

		Paediatric group	Adult group
Total number of cases		20	30
Mean age (years)± SD		9.3±3.097	40.23±13.467
Gender n (%)	Male	9 (45%)	11 (36%)
	female	11 (55%)	19 (63%)

Table-2: Comparison of outcomes of paediatric group and adult group.

		Paediatric group (n=20)	Adult group (n=30)	p- value
Mean hospital stay (days)		5.3500±0.812	5.2667±0.9444	0.646
Mean anaesthesia duration (minutes)		415.85±55.865	433.93±59.789	0.288
Mean anastomosis duration (minutes)		12.60±2.349	14.07±3.095	0.078
Complications (minor)	Present	6 (30%)	6 (20%)	0.417
	Absent	14 (70%)	24 (80%)	
Flap survival		20 (100%)	30 (100%)	

CONCLUSION

The outcomes of free tissue transfer at the extreme of ages are comparable to those in general population, although there is an increase in post-operative medical complications in the elderly. Microsurgical free tissue transfer can now be confidently attempted in children and their results are comparable with those of adult group.

Moreover, the use of free tissue transfer for paediatric reconstruction has shown to provide a durable and aesthetically superior treatment of difficult problems due to their recuperative abilities.

AUTHORS' CONTRIBUTION

AA: Data collection. NK, FE: Literature search. HR: Data analysis & interpretation. SY, IR: Study design. MR, HR: Write-up & Proof reading.

REFERENCES

1. Harii K, Ohmori K. Free groin flaps in children. *Plast Reconstr Surg* 1975;55(5):588–92.

2. Ohmori K, Harii K, Sekiguchi J, Torii S. The youngest free groin flap yet? *Br J Plast Surg* 1977;30(4):273–6.

3. Claes K. Systematic review: free flaps for lower limb reconstruction in children. [Internet]. [cited 2018 May]. Available from: https://lib.ugent.be/fulltxt/RUG01/002/350/465/RUG01-002350465_2017_0001_AC.pdf

4. Van Landuyt K, Hamdi M, Blondeel P, Tonnard P, Verpaele A, Monstrey S. Free perforator flaps in children. *Plast Reconstr Surg* 2005;116(1):159–69.

5. Yildirim S, Aköz T. Big-toe replantation in a three-month-old child: case report. *J Reconstr Microsurg* 2004;20(5):373–5.

6. Parry SW, Toth BA, Elliott LF. Microvascular free-tissue transfer in children. *Plast Reconstr Surg* 1988;81(6):838–40.

7. Devaraj VS, Kay SP, Batchelor AG, Yates A. Microvascular surgery in children. *Br J Plast Surg* 1991;44(4):276–80.

8. Van Beek AL, Wavak PW, Zook EG. Microvascular surgery in young children. *Plast Reconstr Surg* 1979;63(4):457–62.

9. Banic A, Wulff K. Latissimus dorsi free flaps for total repair of extensive lower leg injuries in children. *Plast Reconstr Surg* 1987;79(5):769–75.

10. Gilbert A. Reconstruction of congenital hand defects with microvascular toe transfers. *Hand Clin* 1985;1(2):351–60.

11. Serletti JM, Schingo JV Jr, Deuber MA, Carras AJ, Herrera HR, Reale VF. Free tissue transfer in pediatric patients. *Ann Plast Surg* 1996;36(6):561–8.

12. Yucel A, Aydin Y, Yazar S, Altintas F, Senyuva C. Elective free-tissue transfer in pediatric patients. *J Reconstr Microsurg* 2001;17(1):27–36.
13. Pinder RM, Hart A, Winterton RI, Yates A, Kay SP. Free tissue transfers in the first 2 years of life—A successful cost effective and humane option. *J Plast Reconstr Aesthet Surg* 2010;63(4):616–22.
14. Wilson RC, Yates AP. Paediatric microvascular surgery: anaesthetic experience of 27 toe to hand transfers. *Pediatr Anesth* 1993;3(4):209–15.
15. Chiang YC, Jeng SF, Yeh MC, Liu YT, Chen HT, Wei FC. Free tissue transfer for leg reconstruction in children. *Br J Plast Surg* 1997;50(5):335–42.
16. Moghari A, Emami A, Sheen R, O'Brien BM. Lower limb reconstruction in children using expanded free flaps. *Br J Plast Surg* 1989;42(6):649–52.
17. Canales F, Lineaweaver WC, Furnas H, Whitney TM, Siko PP, Alpert BS, *et al.* Microvascular tissue transfer in paediatric patients: analysis of 106 cases. *Br J Plast Surg* 1991;44(6):423–7.
18. Mast BA, Newton ED. Aggressive use of free flaps in children for burn scar contractures and other soft-tissue deficits. *Ann Plast Surg* 1996;36(6):569–75.
19. Horowitz JH, Nichter LS, Kenney JG, Morgan RF. Lawnmower injuries in children: lower extremity reconstruction. *J Trauma* 1985;25(12):1138–46.
20. Konttila E, Koljonen V, Kauhanen S, Kallio P, Tukiainen E. Microvascular reconstruction in children—a report of 46 cases. *J Trauma* 2010;68(3):548–52.
21. Yildirim S, Calikapan GT, Akoz T. Reconstructive microsurgery in pediatric population—a series of 25 patients. *Microsurgery* 2008;28(2):99–107.
22. Blackwell KE. Unsurpassed reliability of free flaps for head and neck reconstruction. *Arch Otolaryngol Head Neck Surg* 1999;125(3):295–9.
23. El-Gammal TA, El-Sayed A, Kotb MM, Saleh WR, Ragheb YF, El-Refai O, *et al.* Dorsal foot resurfacing using free anterolateral thigh (ALT) flap in children. *Microsurgery* 2013;33(4):259–64.
24. Acar MA, Güleç A, Aydin BK, Erkoçak ÖF, Yilmaz G, Şenaran H. Reconstruction of foot and ankle defects with a free anterolateral thigh flap in pediatric patients. *J Reconstr Microsurg* 2015;31(3):225–32.
25. Shenaq SM, Dinh TA. Pediatric microsurgery. Replantation, revascularization, and obstetric brachial plexus palsy. *Clin Plast Surg* 1990;17(1):77–83.
26. Duteille F, Lim A, Dautel G. Free flap coverage of upper and lower limb tissue defects in children: a series of 22 patients. *Ann Plast Surg* 2003;50(4):344–9.
27. Lickstein LH, Bentz ML. Reconstruction of pediatric foot and ankle trauma. *J Craniofac Surg* 2003;14(4):559–65.
28. Rinker B, Valerio IL, Stewart DH, Pu LL, Vasconez HC. Microvascular free flap reconstruction in pediatric lower extremity trauma: a 10-year review. *Plast Reconstr Surg* 2005;115(6):1618–24.
29. Lin CH, Mardini S, Wei FC, Lin YT, Chen CT. Free flap reconstruction of foot and ankle defects in pediatric patients: long-term outcome in 91 cases. *Plast Reconstr Surg* 2006;117(7):2478–87.

Submitted: 20 June, 2018

Revised: --

Accepted: 18 November, 2018

Address for Correspondence:

Haroon Ur Rashid, Department of Plastic Surgery, Shifa International Hospital, Islamabad-Pakistan

Cell: +92 333 528 2095

Email: haroonpmc@hotmail.com