

## CASE REPORT

## CHONDROBLASTOMA OF THE LUMBAR VERTEBRA

Tahir Mehmood Shakir, Wenfei Li\*, Huiping Wang\*\*, Chen Niu, Ming Zhang

Department of Radiology, First Affiliated Hospital of Xi'an Jiaotong University, Xi'an, Shaanxi, \*Department of Radiology, First Affiliated Hospital of Qinhuangdao, Qinhuangdao, Hebei, \*\*Department of Radiology, People's Hospital of Pingyao, Shanxi-China

Chondroblastoma is an uncommon and benign bone tumour. No more than 10 cases of lumbar chondroblastoma have been reported in the past 20 years. To describe the clinical presentations and radiological features of a rare case of chondroblastoma of the lumbar spine, this study reports one case involving the third lumbar vertebrae. A 22-year-old female presented with left lower back pain and numbness. CT revealed tumour infiltration of the third lumbar vertebrae and left psoas major displacement, which was found to be a chondroblastoma by surgery. Lumbar chondroblastomas are very rare which seem to be aggressive on imaging findings; with soft tissue extension, thin sclerotic rim and bony destruction. When encountering a vertebral lesion that seems to be aggressive on imaging findings, we must be aware of the possibility of chondroblastoma.

**Keywords:** Chondroblastoma; Lumbar Vertebra; CT

**Citation:** Shakir TM, Li W, Wang H, Niu C, Zhang M. Chondroblastoma of the Lumbar Vertebra. J Ayub Med Coll Abbottabad 2018;30(4):608–10.

## INTRODUCTION

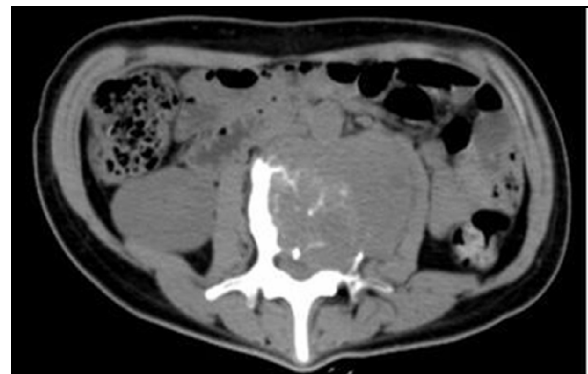Chondroblastoma is a rare benign tumour of bone, accounting not more than 3% of primary bone tumors.<sup>1</sup> Usually, it arises in the epiphyses of long bones, such as in the humerus, femur and tibia.<sup>2</sup> Patients present with complaint of local pain.<sup>1</sup> Less than 10 cases of chondroblastoma have been reported within the lumbar region in the previous literatures.<sup>1-4</sup> We reported a case of lumbar chondroblastoma retrospectively, which has exceedingly rare location and analysed eight case reports published in English, focusing on providing a deeper knowledge of lumbar chondroblastoma.

## CASE PRESENTATION

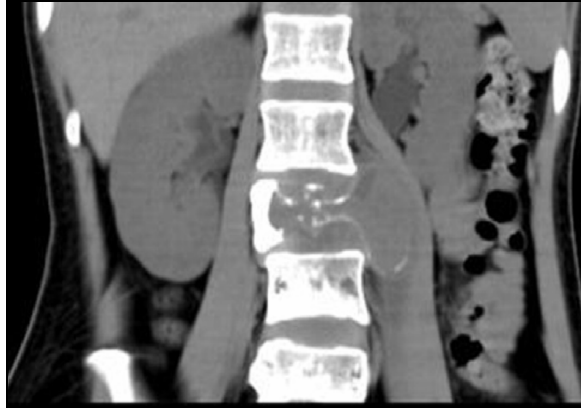A 22-year-old female surviving with mild numbness and lower back pain of the left lower extremity presented in March 2015. After physical therapy and infusion treatment the signs didn't get better. CT discovered that, there is a tumour situated in the third lumbar vertebrae. The doctor well thought out tumour arising from the lumbar vertebra and probability belongs to malignant tumour, which was found to be a chondroblastoma by surgery. A written informed consent was obtained from the participants for this study. Also, the local ethical institutional committee on human research approved this study, and the clinical data were acquired following the guidelines of the Department of Neurosurgery, Xian Jiaotong University, Xian, China. CT results show a lumbar vertebral body with wide spread tumour infiltration of lumbar appurtenance, surrounding by a sharply thin rim. A large soft tissue density mass occupied the spinal canal and effected the nerve root on the left

(Figure 1-2). CT also show that there is a destructive morphologic topographies and bone destruction having calcification. However, the radiological analysis recommended the probability of a benign bone tumour; but metastasis should include this probability in the differential diagnosis. The patient did not undergo for MRI examination.

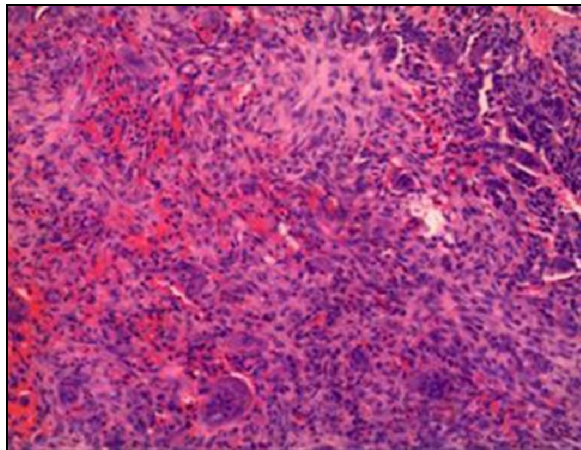
The resected sampling enclosed dispersed benign massive cells and same round cells (possibly, chondrocytes), as well as bone matrix, calcified cartilage, and connective tissue (Figure-3). Associated with the earlier studies, calcification like chicken-wire outline was not seen in our case. We see the identical mononuclear round tumour cells with a massive amount of eosinophilic cytoplasm, mixed with randomly distributed osteoclast kind massive cells.



**Figure-1: The shape of third lumbar vertebrae is irregular, bone destruction and calcification were pronounced in axial CT. A large soft tissue density mass occupied the spinal canal and effected the nerve root on the left.**



**Figure-2: Sclerotic margins in the vertebral body involving the posterior elements and vertebral body, without involving the intervertebral disc. The vertebral density is uneven, visible on the left side of the vertebral bodies; soft tissue density is uneven, with shifting of left psoas major**



**Figure-3: The resected specimen contained scattered benign giant cells and same round cells (chondrocytes), as well as connective tissue, calcified cartilage and bone matrix.**

**Table-1: Summary of the 8 cases of lumbar chondroblastoma reported in the literature**

Author	Year	No. of cases	Age /sex	Spinal level
Bloem	1985	1	NR	L-3
Kurt	1989	1	NR	L-3
Campanacci	1980	1	NR	L-4
Leung	2001	1	54/F	L-5
Chung	2003	1	54/M	L-5
Ilaslan	2003	1	NR	NR
Vialle	2005	2	55/F and 23/F	L-4 and L-3
Silvia	2011	1	30/F	L-4

\* NR = not reported;

## DISCUSSION

Chondroblastoma is a kind of cartilage benign tumour; in 1942, it was firstly discovered by Jaffe and Lichtenstein<sup>2</sup>. Usually, chondroblastoma is found in the epiphysis of the bones; however, this tumour

also matures hardly in the lumbar area. It is stated that the sex proportion of female and male is approximately 1:2.<sup>1</sup> Approximately the Chondroblastoma is accounting for 1–3% of major benign bone cancer.<sup>5</sup>

In our best knowledge, approximately 10 studies on the vertebral regions of chondroblastoma have been reported in the last twenty (20) years. Ilaslan *et al*, reported 856 chondroblastoma in their study, out of the only one case was found in the lumbar vertebral.<sup>2</sup> Vialle *et al*, stated that 28 tumours situated in the spinal column, out of these only two arise in the lumbar vertebra.<sup>4</sup> Chung described a case in 54-year old adult (male) with left sciatica and lower back pain having a tumour penetration of the 5th lumbar vertebra; by repetitive open surgeries it was found to be a chondroblastoma.<sup>7</sup> A recent study reported that the vertebral chondroblastoma diagnosed by aspiration cytology.<sup>1</sup> Our study is very similar to previously reported study<sup>1</sup> in terms of age range and sex but differs in aspect of localization. The patient age was in the range of 22 years, which reasonably narrowly with the mean age of the published case reports in the age range of 29.9 years. The localization of patients in the various case reports were predominantly in L3-L5 (Table-1), the predominant clinical manifestation reported is lower back pain.

The destruction of bone with a spinal cord compression and large soft tissue mass are common radiological appearances of lumbar vertebral chondroblastoma. One investigation on CT imaging indicated that almost all cases of lumbar vertebra chondroblastoma appear destructive. Radiologically, the chondroblastoma located in a long tubular bone was an osteocyte lesion that generally is delimited suddenly from the adjacent normal bone by a thin rim<sup>8-10</sup>, Blancas described that, 18 patients (having 12 men and 6 women; mean age in the range of 19 years) detected with chondroblastoma, calcification was observed in 50% of the cases and a periosteal reaction was seen in 44%.<sup>11</sup> Our patient on axial CT imaging represents a large soft tissue mass and spinal canal invasion, as well as consistent with the combined findings of the previously case reports.

According to this tumour image, the injury of Aneurysm bone cyst (ABC) and giant cell tumour repeatedly seem more destructive with an overstatement of bone expansion and cortical thinning following cortical deficit. The lesion presented similar to ABC, giant cell tumour and metastatic tumour, which could cause misdiagnosis. The giant tumour cell of bone was found in individual having 20~40 years old. Furthermore,

there was no hardened edge and calcification in the lesion. Also, comparison with the chondroblastoma, the edge of giant tumour cell is not clear. Aneurysmal bone cysts are more frequent in the cervical and thoracic spine than in a lumbar localization. Liquid-liquid levels suggestive of aneurysmal bone cyst on CT scan and MRI.<sup>12</sup> In addition, tuberculosis and metastatic tumours also need to be added in differential diagnosis. Intervertebral disc was frequently invaded by the tumour; the incidence of paravertebral abscess with calcification in spinal tuberculosis was higher than that in vertebral chondroblastoma, clinical feature also helpful for difference. Intervertebral disc was not frequently involved, more than one vertebral body invasion seen in metastases.

The histological features of the tumour include "chicken wire" or "picket fence" appearance with intercellular distribution of calcification.<sup>13,14</sup> Although calcification in a chicken-wire pattern is not seen in our case, microscopic examination showed typical polygonal-shaped chondroblasts. The resected specimen contained scattered benign giant cells and same round cells (chondrocytes), as well as connective tissue, calcified cartilage and bone matrix.

## CONCLUSION

Lumbar chondroblastomas are very rare. This case is typical for the imaging characteristics of tumour. Lumbar chondroblastomas seem to be aggressive on imaging findings; with soft tissue extension, thin sclerotic rim and bony destruction. When encountering a vertebral lesion that seems to be aggressive on imaging findings, we must be aware of the possibility of chondroblastoma. Lumbar

chondroblastomas are more likely to present at the L3-L5 level vertebra. We emphasize the role of CT findings in the disease diagnosis.

## REFERENCES

- Hernandez Martinez SJ, Campa Nunez H, Ornelas Cortinas G, Garza Garza R. Chondroblastoma of the fourth lumbar vertebra diagnosed by aspiration biopsy: case report and review of the literature. *Acta Cytol* 2011;55(5):473-7.
- Ilaslan H, Sundaram M, Unni KK. Vertebral chondroblastoma. *Skeletal Radiol* 2003;32(2):66-71.
- Leung LY, Shu SJ, Chan MK, Chan CH. Chondroblastoma of the lumbar vertebra. *Skeletal Radiol* 2001;30(12):710-3.
- Vialle R, Feydy A, Rillardon L, Tohme-Noun C, Anract P, Colombat M, *et al.* Chondroblastoma of the lumbar spine. Report of two cases and review of the literature. *J Neurosurg Spine* 2005;2(5):596-600.
- Attar A, Ugur HC, Caglar YS, Erdogan A, Ozdemir N. Chondroblastoma of the thoracic vertebra. *J Clin Neurosci* 2001;8(1):59-60.
- Ben Maitigue M, Osman W, Ouni F, Boughammoura H, Nawar N, Mtaoumi M, *et al.* Chondroblastoma of bone. *Tunis Med* 2012;90(7):571-8.
- Chung OM, Yip SF, Ngan KC, Ng WF. Chondroblastoma of the lumbar spine with cauda equina syndrome. *Spinal Cord* 2003;41(6):359-64.
- Unni KK. Benign chondroblastoma. In: Unni KK, editor. *Dahlin's Bone Tumors*. 5th ed. Philadelphia, PA: Lippincott-Raven; 1996.
- Zaspa OA. Giant chondroblastoma of the femur. *Arkh Patol* 2014;76(6):61-3.
- Xu H, Nugent D, Monforte HL, Binitie OT, Ding Y, Letson GD, *et al.* Chondroblastoma of bone in the extremities: a multicenter retrospective study. *J Bone Joint Surg Am* 2015;97(11):925-31.
- Blancas C, Llauger J, Palmer J, Valverde S, Bague S. Imaging findings in chondroblastoma. *Radiologia* 2008;50(5):416-23.
- Dekeuwer P, Odent T, Cadilhac C, Journeau P, Langlais J, Padovani JP, *et al.* Aneurysmal bone cyst of the spine in children: a 9-year follow-up of 7 cases and review of the literature. *Rev Chir Orthop Reparatrice Appar Mot* 2003;89(2):97-106.
- Viswanathan S, Jambhekar NA, Merchant NH, Puri A, Agarwal M. Chondroblastoma of bone--not a "benign disease": clinico-pathologic observations on sixty cases. *Indian J Pathol Microbiol* 2004;47(2):198-201.
- Dutt L, Schade VL, Manoso MW. Calcaneal chondroblastoma with pathologic fracture and recurrence. *J Foot Ankle Surg* 2015;54(2):258-67.

Received: 13 April, 2018

Revised: 16 April, 2018

Accepted: 21 June, 2018

### Address for Correspondence:

**Ming Zhang**, Department of Radiology, First Affiliated Hospital of Xi'an Jiaotong University, Yanta west road, Xi'an, Shaanxi, 710061-People's Republic of China

**Email:** zmmri@163.com