

## ORIGINAL ARTICLE

## PROTECTIVE EFFECT OF VITAMIN C ON MONOSODIUM GLUTAMATE INDUCED CHANGES IN THE OVIDUCT OF RATS

Sumaira Abbasi, Saima Mumtaz Khattak, Sana Malik

Department of Anatomy, Federal Medical and Dental College, Islamabad-Pakistan

**Background:** This study was conducted to evaluate the effect of Vitamin C on Monosodium Glutamate induced histopathological changes in oviduct of adult female Sprague Dawley rats. The duration of study was 6 months. It was an analytical experimental randomized control trial.

**Methods:** In this experimental study, 45 female adult Sprague Dawley rats of 10–14 weeks were used and divided into 3 groups. Each group contains 15 rats. Control group (C) received standard laboratory diet. Experimental group A, was given Monosodium Glutamate (0.08 mg/kg body weight/ day) whereas experimental group B, was served on both MSG and Vitamin C (250 mg/kg body weight/day). All groups received diet for a period of 4 weeks. After 4 weeks all rats were sacrificed and oviducts were obtained. For the study of tissue under light microscopy, tissue processing was done by using Haematoxylin and Eosin stain and 5micrometer thick sections were taken from the ampullary part of oviduct. **Results:** After administration of MSG, group A showed vacuolization of epithelial cells, infiltration of RBCs in lumen with substantial decrease in the diameter of oviduct in group A. Protective effects were seen in vitamin C supplemented group B, with decrease in epithelial vacuolization and RBCs infiltrate along with increase in diameter of oviduct. **Conclusion:** Vitamin C has protective effect on Monosodium Glutamate induced histological changes in oviduct of rats.

**Keywords:** Diameter of oviduct; MSG; RBC; Vitamin C; Vacuolization

**Citation:** Abbasi S, Khattak SM, Malik S. Protective effect of vitamin c on monosodium glutamate induced changes in the oviduct of rats. J Ayub Med Coll Abbottabad 2018;30(4):592–5.

### INTRODUCTION

Fertility is defined as ability to conceive and reproduce while infertility on the other hand represents the inability to conceive. According to World Health Organization, infertility is the inability of a couple to conceive even after a period of twenty-four months of unprotected coitus.<sup>1</sup>

The American Society of Reproductive Medicine consider infertility as a disease in which there is a disturbance in the normal structure or function of any part of reproductive system.<sup>2</sup> Estimate indicates that in 40% to 50% of the couples, infertility is due to female problems which include reduced or abnormal production of oocyte, fallopian tube dysfunction and atypical implantation of embryo.<sup>3</sup>

Global rate of infertility in reproductive age is about 10–15% and out of 7 billion world population, around 140 million of people have infertility.<sup>2</sup> Even though, the population growth rate of Pakistan is about 2% but it also has high infertility rate that is about 21.9% out of which 3.5% are due to primary reasons and 18.4% are due to secondary causes like age, hormonal imbalance and use of certain medication.<sup>1,4</sup>

The female reproductive system is vulnerable by harmful environmental factors which include industrial toxins, environmental chemicals and food additives.<sup>5-7</sup> One of the commonly used food additive

is Monosodium glutamate generally known as Ajinomoto.<sup>6,7</sup> Free radicals generated by MSG plays a critical role in the normal function of reproductive system and also in the pathogenesis of female infertility by impairing the oocyte maturation and folliculogenesis.<sup>8-10</sup> Vitamin C defends the human body against oxidative damage by its antioxidizing and a powerful reducing property, by preventing oxidative damage to DNA, proteins and lipids.<sup>11,12</sup> In females, it regulates the menstrual cycle and ovarian function.<sup>13</sup> Monosodium Glutamate (MSG) is commonly used in restaurants (especially mixed in noodles), packaged food industries including chips, salads, soups and canned foods.<sup>13,14,15</sup> Thus it is important to investigate the protective effect of Vitamin C on MSG induced changes in oviducts.

### MATERIAL AND METHODS

The current study was a randomized experimental control trial. Rats were obtained from animal house of NIH, Islamabad where they were kept under standard laboratory conditions. Forty-five female Sprague Dawley rats with the age between 10–14 weeks and weight of 250–350 g was included in the study. Male rats, pregnant female rats and rats with any distinct pathology were also excluded.

Rats were randomly divided into 3 groups and each group is composed of 15 rats. The control group C

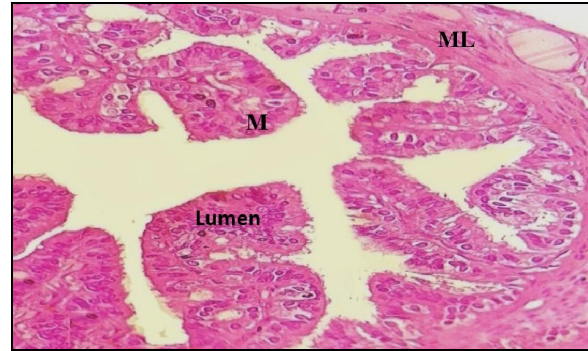
received their standard pellet diet and water. The experimental group A was fed on MSG with the dose of 0.08 mg/kg body weight /day for a period of 4 weeks to induce degenerative changes.<sup>7</sup> The experimental group B was not only kept on MSG but vitamin C with the dose of 250mg/kg body weight/day was also given for a period of 4 weeks.<sup>14</sup> Four weeks later, oviduct was dissected out and cut transversely from their ampullary part, after tissue processing embedding was done in paraffin wax to form blocks. Blocks were mounted on rotary microtome to obtain 5µm thick sections. Haematoxylin and Eosin stains were used for histological study. Presence or absence of epithelial cell vacuolization and RBC's in lumen were observed under the magnification of X40.

Linear micrometre was used to calculate the diameter of ampullary part of oviduct. The scale of the eye piece micrometre was placed on the oviduct. Number of divisions of the eye piece from the apical part of the epithelial cells to the opposite epithelial cells of oviduct were counted and multiplied by 3 and the same method repeated again for the oviduct at right angle. The definite diameter of oviduct in microns was taken by calculating the mean of two diameters. SPSS version 20.0 was used for statistical analysis. Qualitative data that is epithelial vacuolization and infiltration of RBCs was assessed in percentages and compared by applying Pearson Chi Square test. Quantitative data that is diameter of oviduct was interpreted as Mean±S.D. For intergroup comparison One-way ANOVA with Post Hoc Tukey test was applied. *p*-value of <0.05 was acknowledged as statistically significant.

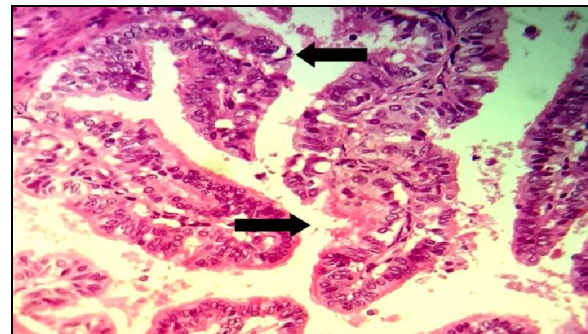
## RESULTS

In control group C, none of the oviduct showed epithelial cell vacuolization and RBCs in lumen (Figure-1). In experimental group A, 10 rats showed epithelial vacuolization (66.7%) and 14 rats (93.3%) demonstrated RBCs in the lumen (Figure-2, 3), while in experimental group B, only 3 rats (20%) demonstrated epithelial vacuolization and RBCs in the lumen of oviduct (Figure-4). The difference in all three groups with respect to vacuole formation and RBC was significant with a *p*-value <0.001.

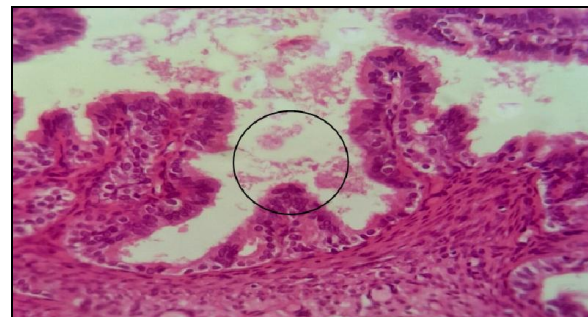
Control group had significantly higher mean diameter of oviduct as compared to experimental group A (*p*<0.001). When control group was compared with the experimental group B, control group had significantly higher mean diameter (*p*<0.001). Similarly, experimental group A had lower mean diameter of oviduct when compared to experimental group B (*p* = 0.006) which is highly significant. (Table-1 and 2)



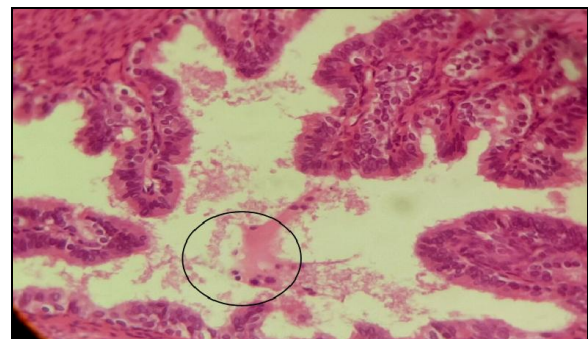**Figure-1: Photomicrograph showing lumen, mucosa (M), muscular layer (ML) in animal rat no. C4. H & E, X40.**



**Figure-2: Photomicrograph showing epithelial vacuolization in animal rat no. A1(demarcated by an arrow). H & E, X40.**



**Figure-3: Photomicrograph showing RBCs in lumen in animal rat no. A7(demarcated by a circle). H & E Stain, X40.**



**Figure-4: Photomicrograph showing RBCs in lumen in animal rat no. B3(demarcated by a circle). H & E Stain, X40**

**Table-1: Mean diameter of ampullary part of oviduct in all groups.**

Groups	Mean±S.D (µm)	SEM	p-value
Group C	105.6±0.3	0.08	< 0.001
Group A	80.7±10.7	2.6	
Group B	90.2±7.2	1.9	

**Table-2: Comparison of mean diameter of oviduct by One Way ANOVA with Post hoc Tukey test**

Groups	Mean difference	p-value
C vs A	24.9	<0.001
C vs B	15.4	<0.001
A vs B	-9.5	0.006

## DISCUSSION

Collected information indicated a strong link between female reproductive pathology and the use of MSG which is commonly present in our house hold kitchen and restaurants.<sup>7,15</sup> The effect of MSG on the female reproductive system causes degenerative histological changes in oviduct by causing cellular hypertrophy which results in narrowing of diameter.<sup>7,18</sup> Pathological changes in oviducts of group A clearly demonstrate the adversarial effects of high intake of MSG.<sup>7</sup>

Although vitamin C is a micronutrient but it plays an important role in almost every biochemical reaction of body.<sup>18,19</sup>

The current is similar to the study carried out by Eweka *et al* on the histological studies on the effect of MSG induced changes in the fallopian tube of adult Wistar rats where vacuolization in the oviduct was attributed to the consumption of MSG.<sup>7</sup>

According to Soujanya, vitamin C can work both inside and outside the cell and plays a fundamental role in neutralizing free radicals, which will seek out for electron for the maintenance of their stability. Vitamin C suppresses the reactivity of free radical by donating electron.<sup>12, 21.</sup>

In the present study, oviducts of group A and B shows epithelial vacuolization. Formation of vacuolization is due to the oxidative stress which stimulates the breakdown of proteins by multicatalytic proteasome complex.<sup>22</sup> The results of this study is in harmony with similar study by Eweka *et al*<sup>7</sup> and Wahdan *et al*<sup>14</sup> in which MSG was administered for a period of 2 weeks.

In the current study, rats of group A and group B shows red blood cells in the lumen. This is a sign of haemorrhage, which can be explained as increase in the vascular permeability and impairment of endothelial function as a result of increased oxidative stress and formation of free radicals.<sup>11</sup> Results of this study is an agreement to the study done previously by Eweka *et al* in Nigeria.<sup>7</sup> These results are similar with Hosam *et al*<sup>20</sup>, who also added vitamin C to reverse the pathological changes induced by vitamin C in liver.

Because of the antioxidant, membrane stabilizing and antihypertensive properties of vitamin C, percentage of red blood cells in the lumen decrease.<sup>15</sup>

Oviduct diameter was measured in the current study which showed difference in group A and B. The constriction of oviduct can be due to hyperplasia or hypertrophy of epithelial cells. Similar findings were also reported by Wahdan *et al*<sup>14</sup> and Eweka *et al*<sup>7</sup>. Similar study was carried out for 2 weeks by administrating MSG, by Zia *et al* in Pakistan which also shows increase in the height of epithelial cells.<sup>13</sup>

The logic behind the hypertrophy of epithelial cells is that there is an increase production of free radicals. The high levels of antioxidant may nullify these hypertrophic changes.<sup>21,22</sup>

## CONCLUSION

Results indicate that the supplementation of vitamin C can be considered as an appropriate dietary strategy to reduce the risk of infertility caused by MSG. Administration of vitamin C to those rats who were fed on MSG showing that vitamin C has protective role against MSG induced deleterious effects on oviducts of rats.

## AUTHORS' CONTRIBUTION

SA: Results and discussion. SMK: Review of literature and introduction. SM: Review of literature and references.

## REFERENCES

1. Shaheen R, Subhan F, Sultan S, Subhan K, Tahir F. Prevalence of infertility in a cross section of Pakistani population. Pak J Zool. 2010;42(4):389–93.
2. Esteves SC, Schattman GL, Agarwal A. Definitions and Relevance of Unexplained Infertility in Reproductive Medicine. In: Unexplained Infertility: Springer, 2015; p.3–5.
3. Showell MG, Brown J, Clarke J, Hart RJ. Antioxidants for female subfertility. The Cochrane Library. 2013.
4. Sami N, Ali TS, Wasim S, Saleem S. Risk factors for secondary infertility among women in Karachi, Pakistan. PLoS One 2012;7(4):e35828.
5. Husarova V, Ostatnikova D. Monosodium Glutamate Toxic Effects and Their Implications for Human Intake. JMED Res 2013;2013:1–12.
6. Ali AA, El-Seify GH, El Haroun HM, Soliman M. Effect of monosodium glutamate on the ovaries of adult female albino rats and the possible protective role of green tea. Menoufia Med J 2014;27(4):793.
7. Eweka AO, Eweka A, Om'Iniabohs FA. Histological studies of the effects of monosodium glutamate of the fallopian tubes of adult female Wistar rats. N Am J Med Sci 2010;2(3):146–9.
8. Waseem N, Butt SA, Hamid S. Amelioration of lead induced changes in ovary of mice, by garlic extract. J Pak Med Assoc 2014;64(7):798–801.
9. Waseem N, Hamid S, Butt SA. Effect of lead acetate on follicular count of mice and the protective role of garlic extract. Pak Armed Forces Med J 2014;64(1):61–5.
10. Agarwal A, Allamaneni SS. Role of free radicals in female reproductive diseases and assisted reproduction. Reprod Biomed Online 2004;9(3):338–47.

11. Zia M, Qamar K, Butt S. Effect of Monosodium Glutamate on the Epithelial Height of Fallopian Tube of Rat and its Prevention with Diltiazem. *Pak Armed Forces Med J* 2013;1(3):11.
12. Paulsen G, Cumming KT, Hamarsland H, Børsheim E, Berntsen S, Raastad T. Can supplementation with vitamin C and E alter physiological adaptations to strength training? *BMC Sports Sci Med Rehabil* 2014;6(1):28.
13. Zia M, Qamar K, Butt S. Effect of Monosodium Glutamate on the Epithelial Height of Fallopian Tube of Rat and its Prevention with Diltiazem. *Pak Armed Forces Med J* 2013;1(3):11.
14. Wahdan RA, Alazouny ZM. Effect of monosodium glutamate on the fallopian tubes of adult albino rats and the possible protective role of vitamin C: a histological and immunohistochemical study. *Egypt J Histol* 2015;38(1):68–76.
15. Juraschek SP, Guallar E, Appel LJ, Miller ER 3rd. Effects of vitamin C supplementation on blood pressure: a meta-analysis of randomized controlled trials. *Am J Clin Nutr* 2012;95(5):1079–88.
16. Huang HY, Appel LJ, Choi MJ, Gelber AC, Charleston J, Norkus EP, *et al.* The effects of vitamin C supplementation on serum concentrations of uric acid: results of a randomized controlled trial. *Arthritis Rheum* 2005;52(6):1843–7.
17. Barton-Schuster D. Improve your fertility with Vitamin C. [Internet]. [cited 2018 Mar]. Available from: <http://natural-fertility-info.com/vitamin-c-to-improve-fertility.html>
18. Mustafa SJ. Effect of Monosodium Glutamate on Mice Ovaries and Possible Protective Role of Vitamin C. *Ann Appl Bio-Sci* 2015;2(4):A100–5.
19. Fracassetti D, Costa C, Moulay L, Tomás-Barberán FA. Ellagic acid derivatives, ellagitannins, proanthocyanidins and other phenolics, vitamin C and antioxidant capacity of two powder products from camu-camu fruit (*Myrciaria dubia*). *Food Chem* 2013;139(1-4):578–88.
20. Osman HEH, Elshama SS, El- Kenaway AE. Study of the role of antioxidant (vitamin c) on modulation toxicity of chronic use of monosodium glutamate in liver of albino rats. *Ain Shams J Forensic Med Clin Toxicol* 2012;19:75–87.
21. Soujanya S, Lakshman M, Anand Kumar A, Reddy A. Histopathological and ultrastructural changes induced by imidacloprid in brain and protective role of vitamin C in rats. *J Chem Pharma Res* 2012;4(9):4307–18.
22. Bendich A, Machlin LJ, Scandurra O, Burton GW, Wayner DD. The antioxidant role of vitamin C. *Adv Free Radic Biol Med* 1986;2(2):419–44.

Received: 9 April, 2018

Revised: 19 October, 2018

Accepted: 2 November, 2018

**Address for Correspondence:**

**Sumaira Abbasi**, Department of Anatomy, Federal Medical and Dental College, Islamabad-Pakistan

**Email:** [sumaira.abbasi@gmail.com](mailto:sumaira.abbasi@gmail.com)