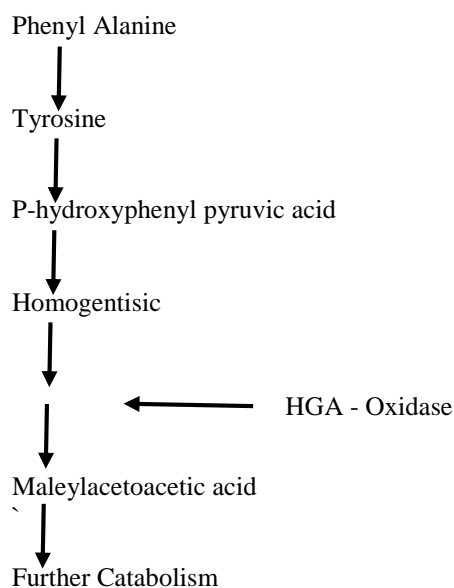


CASE REPORT

ALKAPTONURIA

Mohammad Javed, Imranullah Khan, Nadeem Afzal

Alkaptonuria, also termed ochronosis is a rare metabolic disorder due to a deficiency of the enzyme homogentisic acid oxidase¹².



The result of HGA oxidase deficiency is an accumulation of homogentisic acid in the body and its deposition preferentially in the cartilages, tendons and other tissues as a blue-black or a brown black pigment. HGA is also excreted in the urine turning it black if left to stand for a while.

A patient with Alkaptonuria may present:

- (a) In early life with dark urine or brown staining of urine soiled clothes.
- (b) In adult life with ochronotic arthritis.
- (c) To the dermatologist with abnormal pigmentation.
- (d) With a false positive test for glycosuria.
- (e) With characteristic features in the spine on an abdominal X-ray.

An acquired form of ochronosis is encountered in patients in whom phenol dressings are applied to chronic cutaneous ulcers, or with the use of hydroquinone bleaching creams.³

From Ayub Medical College, Abbottabad.

MOHAMMAD JAVED, MBBS, MRCP, Assistant Professor, Department of Medicine.

IMRANULLAH KHAN, MBBS, DDV (Vienna), Assistant Professor, Department of Dermatology.

NADEEM AFZAL, MBBS, FCPS, Medical Officer, D.H.Q. Hospital, Abbottabad.

FIGURE - 1

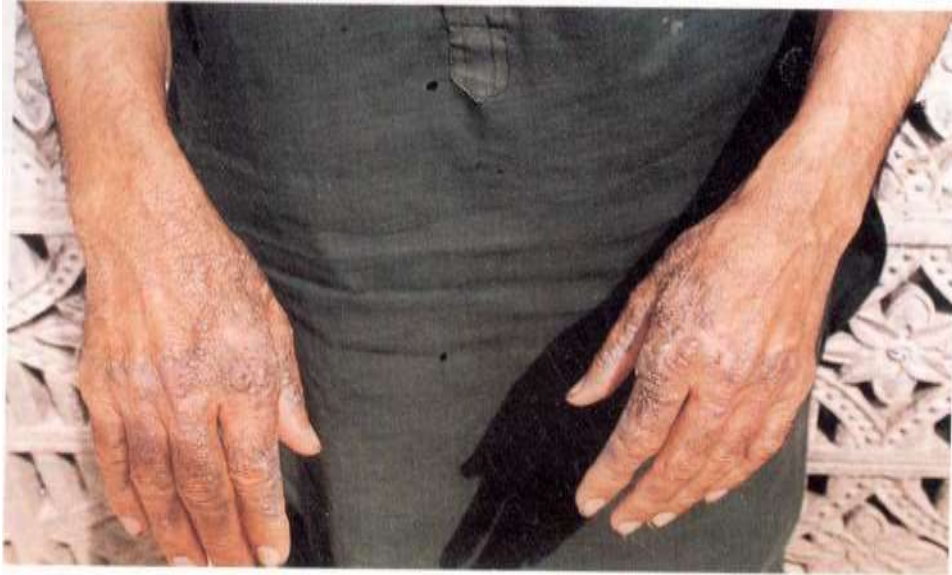

FIGURE - 2



CASE REPORT:

A 40-year-old farmer from Balakot presented to the Medical Out Patients with pain in both the knees. On examination he had dark brown lesions over the dorsum of both hands (Fig-1). These were itchy and some of them were secondarily infected. Similar lesions were found over both the ear lobes. Movements at the right knee joint were restricted and painful. Crepitus was present in both the knee joints. The rest of the clinical examination was unremarkable.

Clinically, the diagnosis of ochronosis was suspected. His urine turned black on standing Fig-2 (freshly voided urine turns black if alkali is added to it). X-ray of the spine revealed typical changes and with calcification in the intervertebral discs (Fig-3).

DISCUSSION:

Alkaptonuria is inherited as autosomal recessive. It has been reported in an Egyptian mummy from the year 3500 BC.⁴

A high index of suspicion is required in patients presenting with arthritis manifestations. A careful examination should usually reveal the typical pigmentation.

No specific therapy is available through joint manifestations can be decreased by dietary restriction of phenylalanine and tyrosine.⁵ Ascorbic acids might help by decreasing oxidation and polymerization of HGA.

Management of this disorder so far is mainly supportive.

REFERENCES

1. Watts, R.W.E. Inborn errors of Amino Acid metabolism. Weastherall D.J., Redingham JGG and Warell, D.A. Oxford Textbook of Medicine 1985, 9.89-9, 91.
2. Zilva, F., Pannal P.R. Inborn errors of metabolism. Clinical Chemistry in diagnosis and treatment 94th ed) London Lloyd-Luke - 1985,395.
3. Horshaw, R.A., Zimmerman, K.G., Menter, A Ochronosis like pigmentation from hydroquinone bleaching creams i American blacks. Arch. Dermatol, 1985; 121: 105-8.
4. Lee, S.L., Stenn, F.F. Characterization of mummy bone ochronotic pigment JMA, 1978; 240: 136.
5. Rosenberg, L.E. Storage diseases of Amino Acid metabolism Wilson J.D: Braunwald E. Harrison's principles of internal medicine 12th Ed. 1991: 1875-77.