

## CASE REPORT

# TESTICULAR LIPOMATOSIS IN COWDEN DISEASE

**Dawar Khan, Wasim A. Memon, Saad Siddiqui**

Department of Radiology, The Aga Khan University, Karachi-Pakistan

Cowden disease is a genetic syndrome resulting in formation of multiple premalignant hamartomas in different parts of the body with classical radiological features. In this report a case of Testicular Lipomatosis as a result of Cowden disease resulting in primary infertility.

**Keywords:** Cowden disease, testicular lipomatosis, primary infertility, hamartomas, testis

J Ayub Med Coll Abbottabad 2015;27(4):925-6

## INTRODUCTION

Multiple Hamartoma Syndrome also known as Cowden disease or Cowden syndrome is an autosomal dominant condition caused by mutation of PTEN tumour suppressor gene on arm 10 q. It has a variable expression and usually results in hamartomatous neoplasms affecting almost all parts of the body with predilection for skin and mucosal linings of Gastrointestinal, Genitourinary and central nervous system.<sup>1</sup> These hamartomas have a very high predisposition for malignant transformation. Being autosomal dominant it affects both genders with equal predisposition however complications of malignant transformation vary among genders. Thyroid cancer being the most common cancer in males and Breast cancer being the most common malignant neoplasm in females occurs with this disorder.<sup>1</sup>

The gold standard for the diagnosis remains to be genetic testing of affected individual for PTEN deletions. Radiological modalities play an important role in the diagnosis, follow-up and treatment of multiple hamartoma syndromes. CT scan imaging and ultrasonography are usually the first modalities to discover abnormalities suggestive of multiple hamartomas in tissues of Breast, gastrointestinal and genitourinary tract. Follow up with mammography and magnetic resonance imaging (MRI) is an integral part in management of multiple hamartoma syndrome. Similarly vascular and interventional radiological procedures are often used in management of complications related with multiple hamartoma syndrome e.g., acute haemorrhage from arteriovenous malformation.<sup>2,3</sup>

## CASE

A 29 years old gentleman was referred to radiology department for scrotal ultrasound to evaluate Primary infertility for past 4 years. Clinical suspicion of varicocele was raised and imaging ordered for further evaluation. He was also being managed and evaluated for chronic kidney Disease secondary to bilateral pelvi-ureteric junction obstruction at time of presentation.

On presentation he was found to have multiple small raised hamartomatous lesions on face, arms and in the genital region.

His laboratory investigations at time of presentation revealed raised serum creatinine measuring 2.0 mg/dL. Serum levels for testosterone, Prolactin, Follicle stimulating hormone (FSH) and Lieutenizing Hormone (LH) were within normal limits. Urine Detailed report revealed proteinuria with a value of 1g/L along with microscopic hematuria. Semen report revealed azoospermia suggesting a primary gonadal failure.

Ultrasound examination of the scrotum revealed normal size, shape and smooth surface of both testis. Numerous hyperechoic lesions were identified infiltrating the parenchyma of both testes (see figure). There was increased vascularity in both testes on colour doppler examination. Both epididymal heads were normal in size with an epididymal head cyst noted on the left side. No extra-testicular mass was seen. Moderate varicocele was also seen on the left side. The findings of ultrasound examination, clinical history and laboratory investigations were highly suggestive of multiple hamartoma syndromes. On follow up visit after 3 months, the patient was having stable chronic kidney disease and did not undergo any additional genetic testing for confirmation of Cowden syndrome.

## DISCUSSION

Cowden disease, synonymously known as Cowden syndrome or multiple hamartoma syndrome is a rare inherited disorder. It is an autosomal dominant condition with variable expression resulting from mutation in PTEN gene on arm 10 q. This condition results in hamartomatous neoplasms of skin, mucosal linings and soft tissues. Skin is involved in almost all cases while the second most common involvement is of Thyroid gland.<sup>1</sup>

About 300 cases of Cowden disease have been published worldwide. Usual complications of this disease include malignant transformation in any of involved organ. Thyroid cancer is the most common malignancy in men while breast followed by endometrial cancer are the most common

malignancies in women affected by this condition. Morbidity due to complications of primary hamartoma like mass effect, bleeding and infiltration of normal tissue also occurs. The same condition was noted in our case that had developed azoospermia as a result of infiltration of testis by multiple hamartomas.<sup>4</sup>

Imaging plays an important role in diagnosis and management of Cowden disease. Annual screening mammograms are required to monitor affected patients for development of malignancy. Contrast studies like Barium meal, Barium enema and intravenous pyelography are indicated for diagnosing Gastrointestinal and Genitourinary neoplasms. Magnetic resonance imaging of brain is highly sensitive in diagnosing intracranial lesions in affected patients with CNS symptoms.<sup>1</sup>

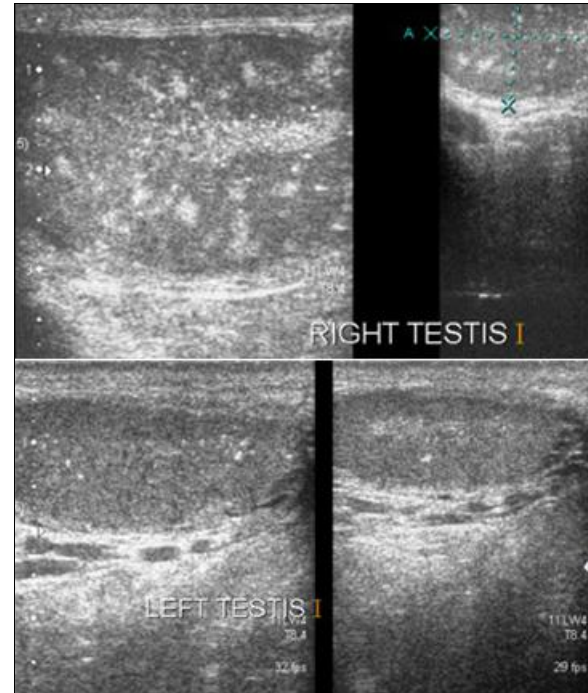
Ultrasound of testes in patient with Cowden disease usually reveals multiple bilateral lesions which are usually representing hamartomas as they are having fat component on Magnetic resonance imaging. Ultrasound findings of intertesticular lipomatosis secondary to Cowden disease are usually pathognomonic. The typical imaging features as described include multiple avascular hyperechoic foci of approximately 1–6mm size. These lesions are usually small, well distributed and do not cause acoustic shadows. Similar findings were also seen in our case. However these lesions should be differentiated from testicular microlithiasis and lesions resulting secondary to lymphoma, sarcoidosis and metastatic disease. Associated findings of epididymal cysts or masses can also be found in case of Cowden disease.<sup>5</sup>

Differential diagnosis of similar appearance on scrotal ultrasound include testicular microlithiasis, germ cell tumours, sex cord stromal tumours, leukemia, lymphoma, metastases, granulomatous disease (sarcoidosis and tuberculosis) and Leydig cell hyperplasia.

Almost half of the patients with Cowden disease progress to least one primary malignant tumour, however multiple primary malignant tumours may also be present in a patient. Close surveillance, follow up and a multidisciplinary treatment of lesions form the crux of management in patients affected with Cowden disease.

## CONCLUSION

Use of multiple radiological modalities and multidisciplinary approach ensures early diagnosis and close surveillance of patients with Cowden disease. It is warranted for early detection of malignancies in these patients.



**Figure-1: Axial and Longitudinal sections from testis showing multiple hyper-echoic lesions representing lipomatosis**

## REFERENCES

1. Patil PB, Sreenivasan V, Goel S, Nagaraju K, Vashishth S, Gupta S, *et al.* Cowden syndrome- Clinico-radiological illustration of a rare case. *Contemp Clin Dent* 2013;4(1):119–23.
2. Gold BM, Bagla S, Zarrabi MH. Radiologic manifestations of Cowden disease. *AJR Am J Roentgenol* 1980;135(2):385–7.
3. Dogra VS, Bhatt S. Testicular hamartomas. *Ultrasound Q* 2009;25(2):67–8.
4. Lindsay C, Boardman L, Farrell M. Testicular hamartomas in Cowden disease. *J Clin Ultrasound* 2003;31(9):481–3.
5. Venkatanarasimha N, Hilmy S, Freeman S. Case 175: Testicular lipomatosis in Cowden disease. *Radiology* 2011;261(2):654–8.

## Address for Correspondence:

**Dr. Saad Siddiqui**, Department of Radiology, The Aga Khan University, Stadium Road, Karachi 74800-Pakistan.

**Cell:** +92 321 906 3099

**Email:** saadsiddiqui.5@gmail.com