

CASE REPORT

AN UNUSUAL CAUSE OF MALABSORPTION IN AN IMMUNOCOMPETENT HOST

Sachdev Atul, Duseja Ajay, Nada Ritambhara*, Mohan Harsh*, Bhalla Ashish

Departments of Medicine & *Pathology, Government Medical College & Hospital, Chandigarh – 160 030, India

Gastrointestinal tract infestation with *Strongyloides stercoralis* is common in the tropical and subtropical areas of the world. In an immunocompetent person, disease is generally asymptomatic. However, it has the potential to cause serious life threatening disease in an immunocompromised patient. We report a 55 years old immunocompetent person who presented with malabsorption secondary to *strongyloides stercoralis* infestation. Unusual infestations like *strongyloides* should also be considered while investigating malabsorption.

Key words: Malabsorption, Strongyloidiasis, immunocompetent

INTRODUCTION

Strongyloides stercoralis is a nematode that infests the human intestine especially in tropical and subtropical regions, most of these infections being asymptomatic. However, it can cause substantial intestinal disease and can disseminate widely to extra intestinal sites such as lungs, kidney or brain (the *hyper infection* syndrome), especially in the immunocompromised host¹. In immunocompetent hosts, these parasites cause a low grade, chronic infection, which has been seen even up to 40 years after exposure². Presentation as malabsorption in an immunocompetent host is an uncommon event. We report a case of a 55-year-old immunocompetent male who presented with features of malabsorption because of *strongyloides stercoralis* infestation.

CASE HISTORY

A 55-year-old male labourer from Bihar, presented with complaints of chronic diarrhoea of 1 year duration. The stools were bulky, frothy, foul smelling & it contained undigested food particles. There was no history of passage of blood, mucus or pus in stool. Patient noticed 12 kg weight loss in the past one year. There was no history of fever, pain abdomen or steatorrhoea. Examination revealed an emaciated man with glossitis, cheilitis and angular stomatitis. There was no lymphadenopathy, clubbing or lymphadenopathy. Significant pedal oedema was noted. Systemic examination including abdominal examination was unremarkable. Investigations revealed hemoglobin of 7.0g% with a normal leukocyte and platelet count but there were 8% eosinophils on differential leukocyte count. His total serum proteins were 5.5g% with an albumin content of 2.8g% and globulins of 2.7g%. Urine examination, renal function tests, chest x-ray, abdominal x-ray and ultrasound of abdomen were normal. He had a positive Mantoux test. Stool examination done on three occasions showed larvae of *strongyloides stercoralis*. His D-Xylose test was abnormal and had a value of 0.7g/5g after 5 hours of urine collection. Barium meal follow through examination revealed thickened duodenal and Jejunal folds with irritability, decreased transit time with pattern of malabsorption. Endoscopic biopsy from third part of the duodenum showed the larvae of *strongyloides stercoralis* infiltrating the surface and crypt epithelium (Fig. 1 & 2). His HIV serology (HIV 1 & 2) determined by ELISA was negative.

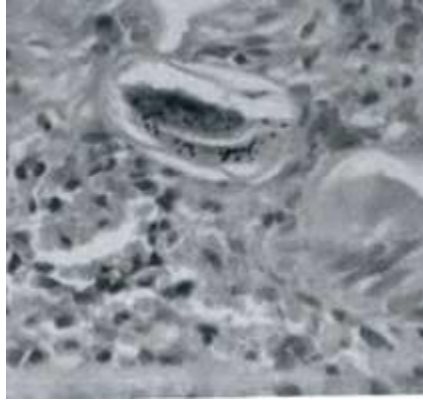


Fig-1: Strongyloides stercoralis larvae (arrow) infiltrating the crypt epithelium (H&E x 40)

He was treated with albendazole 10mg/kg/day for three days but the stool examination done after seven days showed the persistence of larvae. He was treated again with Thiabendazole 25 mg/kg/day for three days. Repeat stool examination done after one week was negative for the larvae. On follow-up his diarrhoea had subsided and he had started gaining weight.

DISCUSSION

Strongyloidiasis primarily presents with dermatological and gastroenterological (GI) disease. Skin manifestations are usually in the form of urticarial eruptions or 'larva currens.' None of these were present in our patient. GI manifestations are usually in the form of indigestion, cramping lower abdominal pain, pruritis ani and intermittent or persistent diarrhoea.³ Various uncommon GI manifestations have also been described,³ malabsorption being one of them.⁴ Our patient had malabsorption as was evident on characteristic history, physical examination, abnormal D-Xylose test and findings on barium meal follow through examination. Strongyloides stercoralis infestation was demonstrated by the presence of larvae in the stool and endoscopic biopsies.

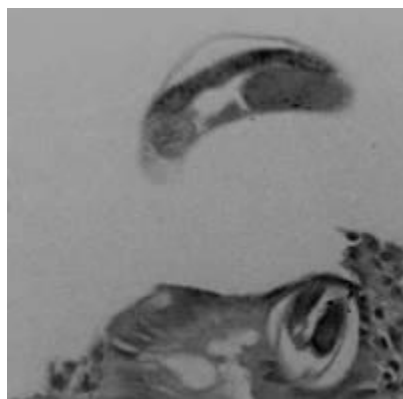


Fig-2: *Strongyloides stercoralis* larvae, seen in the intestinal crypt epithelium in D2 biopsy, in an immunocompetent patient with malabsorption. The patient responded to therapy with thiabendazole.

In most of the earlier reports of Strongyloidiasis, patients presenting as chronic diarrhoea or malabsorption had either an associated immunosuppressive illness or were on immunosuppressive treatment.⁵ In patients, who did not have any associated immunosuppressive disease or medication, HIV was not excluded, it being a pre HIV era.⁵ Our patient did not have any associated illness suggestive of immunosuppression and was not on any immunosuppressive treatment. He did not have history suggestive of congenital immune deficiency, and had normal cell counts, normal serum globulins, a positive mantoux test and a negative HIV serology.

Malabsorption in an immunocompetent patient because of *strongyloides stercoralis* is an unusual manifestation and that makes this case interesting.

REFERENCES

1. Gotuzzo E, Terashima A, Alvarez H. *Strongyloides stercoralis* hyper infection associated with human T cell lymphotropic virus type I infection in Peru. *Am J Trop Med Hyg* 1999; 60:146-9.
2. Gill GV, Bell DR. *Strongyloides stercoralis* infection in former far East prisoners of war. *Br Med J* 1979; 2:572-4.
3. Grove DI. Strongyloidiasis: A conundrum for gastroenterologist. *Gut* 1994; 35:437-40.
4. O'Brien W. Intestinal malabsorption in an acute infection with *Strongyloides stercoralis*. *Trans R Soc Trop Med Hyg* 1989; 150:92-3.
5. Milder JE, Walzer PD, Kilgore G, Rutherford I and Klein M. Clinical features of *Strongyloides stercoralis* infection in an endemic area of the United States. *Gastroenterology* 1981; 80:1481-8.

Address for Correspondence:

Dr. Atul Sachdev, Professor & Head, Department of Medicine, House No.1208 , Medical College Campus, Sector 32, Chandigarh 160 030. Phone No.0172-662128 Fax: 0172-608488

Email: atulsachdev@glide.net.in