

## ORIGINAL ARTICLE

## RELIABILITY AND VALIDITY OF MAXILLARY AND SPHENOID SINUS MORPHOLOGICAL VARIATIONS IN THE ASSESSMENT OF SKELETAL MATURITY

Hafiz Taha Mahmood, Attiya Shaikh, Mubassar Fida

Section of Dentistry, Department of Surgery, The Aga Khan University Hospital, Karachi-Pakistan

**Background:** The present study aimed at assessing the relationship between growth changes in maxillary (MS) and sphenoid sinus (SS) and cervical vertebral maturation (CVM) and to evaluate their reliability and validity in assessing the skeletal maturity of an individual. **Methods:** A cross-sectional study was conducted on the pretreatment lateral cephalograms of 224 patients (males=116, females=108) aged 8–17 years. MS and SS heights, widths and indices were evaluated. The subjects were classified according to six stages based on CVM using Baccetti's method. Kruskal-Wallis test was applied to compare MS and SS measurements at different cervical stages for each gender. Kappa statistics, positive predictive value, negative predictive value, sensitivity and specificity were calculated to test the diagnostic accuracy of MS and SS indices. **Results:** The MS and SS indices varied significantly ( $p<0.001$ ) at different cervical stages for both gender. Kappa statistics showed significant agreement using MS ( $p<0.001$ ) and SS indices ( $p<0.05$ ). The diagnostic performance of MS index (Sensitivity  $\geq 71\%$ ) was found to be better than SS index (Sensitivity  $\geq 65\%$ ). **Conclusions:** The MS height, width and index in genders and SS height, width and index in males and only SS width and index in females were significantly associated with the CVM stages. The validity of MS and SS indices were comparable for females; whereas, the MS index offers significant advantage over SS index for the assessment of growth status of males.

**Keywords:** Maxillary Sinus; Sphenoid Sinus; Cervical Vertebral Maturation

**Citation:** Mahmood HT, Shaikh A, Fida M. Reliability and validity of maxillary and sphenoid sinus morphological variations in the assessment of skeletal maturity. J Ayub Med Coll Abbottabad 2018;30(3):360–5.

### INTRODUCTION

The approach of the contemporary orthodontists is to treat the underlying skeletal malocclusion rather than camouflaging it with dental compensations.<sup>1</sup> The dilemma with the treatment of skeletal malocclusion is to decide whether growth modification, camouflage or orthognathic surgery would be the treatment of choice. The decision is usually made with the knowledge of the magnitude, duration and timing of growth.<sup>2–4</sup>

Over the years, researchers have found out different indicators to assess the level of growth potential of an individual. These include body height,<sup>5</sup> body weight,<sup>6</sup> voice changes in males and menarche period in females,<sup>7</sup> tooth development and calcification stages<sup>8,9</sup> and skeletal development<sup>10,11</sup>. The skeletal maturity of an individual can be determined by evaluating the ossification of different bones of hand and wrist, and elbow on radiographs.<sup>12,13</sup>

Due to evolving concerns over radiation exposure and the increased cost involved, researchers are constantly looking for different modalities to evaluate the skeletal maturity of a patient using structures that are present on lateral cephalogram. In this attempt, Lamparski<sup>14</sup> first assessed the cervical

vertebrae on lateral cephalograms and later different researchers<sup>15,16</sup> redefined and revised this method and verified that CVM correlates well with the skeletal maturation. However, this method carries certain limitations as it is difficult to classify the vertebral bodies of C3 and C4 as trapezoidal, rectangular horizontal, square or rectangular vertical and also to identify the concavities in the lower border of the vertebra.<sup>17</sup>

In this context, many authors have evaluated the paranasal sinuses morphology on lateral cephalogram.<sup>18,19</sup> They reported that the enlargement of sinuses is related with the mandibular growth and that the sinus morphology may be used to predict the growth of the mandible. However, to our knowledge no study has yet reported the relevancy of maxillary (MS) and sphenoid sinus (SS) morphological variations with other skeletal maturity indicators. Hence, with this aim in mind, we planned to evaluate the changing morphology of MS and SS with the CVM. Moreover, this study also assessed the reliability and validity of MS and SS indices for the assessment of skeletal maturity.

### MATERIAL AND METHODS

A retrospective cross-sectional study was conducted from the pretreatment lateral cephalograms of

patients who presented to dental clinics, Aga Khan University Hospital from January 2013 to January 2016 for the orthodontic treatment. An ethical exemption (4278-Sur-ERC-16) was obtained prior to conducting the study. The sampling technique used was non-probability purposive sampling.

The sample size was calculated in OpenEpi software (version 3.0) using the findings of Patil and Revankar<sup>20</sup> who showed a mean difference in the sinus index values at different skeletal maturation stages of 0.25 with a standard deviation of 0.26. The power was set as 80% and alpha was taken as 0.05 to calculate the sample size that showed that we need a sample size of 42 in each group. Since we have a total of 6 groups, the total sample size would be  $42 \times 6 = 252$ . However, 28 lateral cephalograms were excluded due to magnification error, inability to find sphenoid and/or maxillary sinus borders and margins and failure to capture the first four cervical vertebrae.

A total of 224 lateral cephalograms were included in the study based on the following inclusion criteria: patients of Pakistani origin, aged between 8–17 years and having good quality standardized lateral cephalograms. Patients with any paranasal sinus abnormalities, diseases affecting the growth and development of an individual and anomalies affecting the craniofacial region were excluded from the study.

All the cephalograms were taken with rigid head fixation and a 165 cm film to tube distance using Orthoralix R 9200 (Gendex-KaVo, Milan, Italy). The morphology of the MS and SS were analyzed using the digital images of the lateral cephalogram on Rogan Delft View Pro-X (Rogan Delft B.V., Veenendaal, Netherlands) software. For the assessment of SS morphology, the cephalogram was oriented with the sella-nasion line horizontally and the sinus height and width were analyzed in the same way as described by Ertuk<sup>21</sup> (Figure-1). For the assessment of MS, the sinus height and width were measured as described by Endo *et al*<sup>22</sup> (Figure-2). The sinus height to width ratio was taken as the sinus index.

The CVM stages were assessed on the lateral cephalograms by Baccetti's method<sup>16</sup> and were used to divide the sample into six stages (Figure-3). A cut-off limit of 89% for MS index and 41% for SS index was set to further divide the sample into two groups, i.e., pre-pubertal (CS1–CS3) and post-pubertal (CS4–CS6). The diagnostic validity of MS and SS indices in the assessment of pubertal growth spurt was assessed against the CVM method.

Data were analyzed using SPSS-19.0. The Kolmogorov-Smirnov test was used to assess the normality of the measurements. The test showed

non-normal distribution; hence non-parametric tests were performed. To compare MS and SS measurements in males and females, a Mann-Whitney U test was used. Kruskal-Wallis test was used to compare MS and SS measurements at different cervical stages for both males and females. *Post-hoc* Dunnett T3 test was performed to compare MS and SS indices values at adjacent cervical stages. Kappa statistics were used to assess the level of agreement between the diagnostic interpretation of MS and SS indices and the CVM. Positive predictive value (PPV), negative predictive value (NPV), sensitivity and specificity were calculated for MS and SS indices. A *p*-value  $\leq 0.05$  was considered as statistically significant.

For assessing the intra-examiner reliability of the measurements, 30 cephalograms were randomly selected and reassessed by the principal investigator. The intra-class correlation coefficient was used and it showed that the repeated measurements were highly correlated. The errors in the measurements were calculated according to the Dahlberg's<sup>23</sup> equation and the coefficient of reliability was calculated according to Houston's<sup>24</sup> formula (Table-1). The measurement errors were found to be small and ranged from 0.00003 to 0.477 mm, and the coefficients of reliability varied from 0.96 to 0.99.

## RESULTS

The study sample comprised of 116 males and 108 females. The MS and SS height, width and indices were compared between males and females, which showed significant differences in MS height and width and SS height between the genders (Table-2). Therefore, further analyses were made separately for the gender.

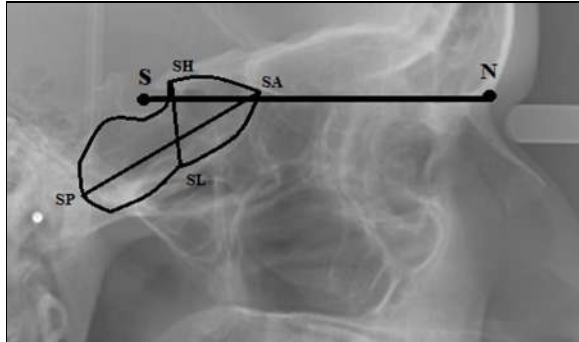
The MS height, width and index varied significantly ( $p < 0.001$ ) at different cervical stages for both males and females. The SS width and index were found to be statistically significant at different cervical stages in both males and females ( $p < 0.001$ ). Whereas, SS height was found to be significant ( $p = 0.016$ ) in males only (Tables-3) (Figures-4 and 5).

*Post-hoc* Dunnett T3 test showed no significant difference in the MS and SS indices at adjacent cervical stages in both males and females (Table-4) (Figure 4 and 5).

When the sample was divided into two groups, i.e., pre-pubertal and post-pubertal, Kappa statistics showed that the agreement in the diagnosis of adolescent growth stages using SS index and CVM was significant for both males ( $k = 0.293$ ;  $p = 0.002$ ) and females ( $k = 0.407$ ;

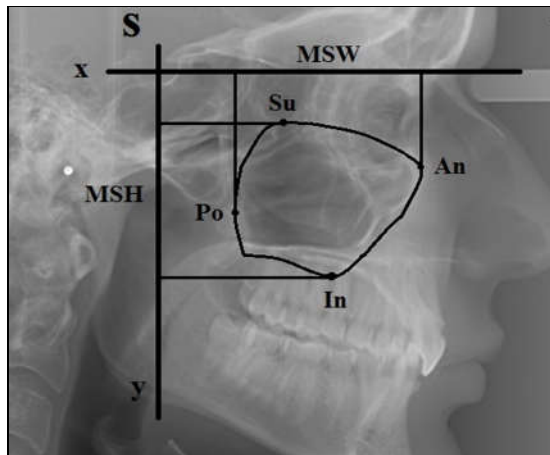
$p < 0.001$ ) (Tables-4, 6). Similarly, the MS index and CVM also showed a moderate agreement in males ( $k=0.534$ ;  $p < 0.001$ ) and females ( $k=0.407$ ;  $p < 0.001$ ) (Tables-7, 8)

Generally, the diagnostic performance of MS index (Sensitivity 74% in males, 71% in females; Specificity 79% in males, 70% in females) was found to be better than SS index (Sensitivity 65% in males, 73% in females; Specificity 64% in males, 68% in females) (Tables 5–8).



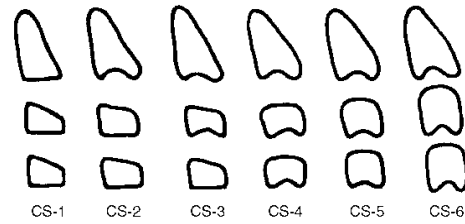
**Figure-1: Assessment of sphenoid sinus morphology on lateral cephalogram using Ertuk<sup>27</sup> method**

The lateral cephalogram was oriented with the sella-nasion line horizontal. SH: the highest point on sphenoid sinus. SL: the lowest point on sphenoid sinus. SP: posterior point on sphenoid sinus. SA: anterior point on sphenoid sinus. SSH: line joining points SH and SL denoting maximum sphenoid sinus height. SSW: line joining points SP and SA denoting maximum sphenoid sinus width. S: anatomical center of sella turcica. N: deepest point in the midline at the frontonasal suture



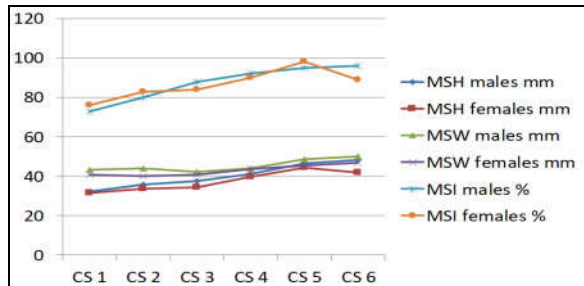
**Figure-2: Assessment of maxillary sinus morphology on lateral cephalogram using Endo et al<sup>28</sup> method.**

The x-axis parallel to the Frankfort horizontal plane and y-axis perpendicular to the Frankfort horizontal plane; were made through sella point. An: anterior point on maxillary sinus. Po: posterior point on maxillary sinus. Su: superior point on maxillary sinus. In: inferior point on maxillary sinus. MSH: line projected on y-axis, joining points Su and In, denoting maximum maxillary sinus height. MSW: line projected on x-axis, joining points Po and An, denoting maximum maxillary sinus width. S: anatomical center of sella turcica



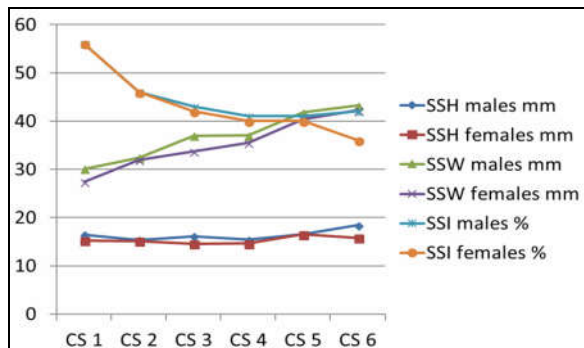
**Figure-3: CVM stages according to Baccetti's method.**

CS 1: The inferior borders of the bodies of all cervical vertebrae are flat. The superior borders are tapered from posterior to anterior. CS 2: A concavity develops in the inferior border of the second vertebrae. The anterior vertical height of the bodies increases. CS 3: A concavity develops in the inferior border of the third vertebrae. One vertebral body has trapezoidal or wedge shaped. CS 4: A concavity develops in the inferior border of the fourth vertebrae. Concavities in the lower border of the fifth and sixth vertebra are beginning to develop. The bodies of all cervical vertebra are rectangular in shape. CS 5: Concavities are well defined in the lower borders of the bodies of all cervical vertebra. The bodies are nearly square and the spaces between the bodies are reduced. CS 6: All concavities have deepened. The vertebral bodies are now higher than they are wide.



**Figure-4: Graph showing relationship between MS height, width and index and CVM stages in males and females**

MSH males mm: maxillary sinus height in males in millimeter; MSH females mm: maxillary sinus height in females in millimeter; MSW males mm: maxillary sinus width in millimeter; MSW females mm: maxillary sinus width in females in millimeter; MSI males %: maxillary sinus index in males in percentage and MSI females %: maxillary sinus index in females in percentage.



**Figure-5: Graph showing relationship between SS height, width and index and CVM stages in males and females.**

SSH males mm: sphenoid sinus height in males in millimeter; SSH females mm: sphenoid sinus height in females in millimeter; SSW males mm: sphenoid sinus width in millimeter; SSW females mm: sphenoid sinus width in females in millimeter; SSI males %: sphenoid sinus index in males in percentage and SSI females %: sphenoid sinus index in females in percentage.

**Table-1: Assessment of reliability of measurements**

Variables	1 <sup>st</sup> reading (n=30)	2 <sup>nd</sup> reading (n=30)	ICC	Dahlberg's calculations	Houston's coefficient of reliability	
MS	Height (mm)	44.78±5.45	44.59±5.45	0.993	0.385	0.98
	Width (mm)	46.26±4.47	46.47±4.42	0.991	0.344	0.97
	Index	0.96±0.10	0.96±0.10	0.990	0.0002	0.96
SS	Height (mm)	14.72±2.91	14.84±2.94	0.994	0.094	0.98
	Width (mm)	39.50±5.54	39.50±6.03	0.993	0.477	0.97
	Index	0.36±0.06	0.36±0.05	0.995	0.00003	0.99

n = 30 ICC = Intra-class Correlation Coefficient

**Table-2: Comparison of MS and SS measurements in males and females**

Sinus Parameters		Male (n=116) (Mean±SD)	Female (n=108) (Mean±SD)	p-value
MS Measurements	Height (mm)	40.26±8.52	37.60±6.42	0.009*
	Width (mm)	45.42±4.88	42.99±4.42	<0.001**
	Index	0.87±0.13	0.87±0.12	0.425
SS Measurements	Height (mm)	16.40±4.09	15.35±2.80	0.051*
	Width (mm)	36.91±6.68	35.28±6.87	0.100
	Index	0.45±0.12	0.44±0.09	0.811

n= 224; SD – Standard Deviation; Mann-Whitney U test. \*p<0.05; \*\*p<0.001

**Table-3: Comparison of MS and SS measurements at different cervical stages**

CS Stages	Gender	CS 1	CS 2	CS 3	CS 4	CS 5	CS 6	p-value
MS Height (mm)	Males	32.09±6.23	35.66±4.29	37.74±5.33	40.99±7.27	46.38±9.16	48.33±5.54	<0.001**
	Females	31.37±5.73	33.48±3.55	34.34±2.65	39.69±5.38	44.38±4.16	42.00±3.99	<0.001**
MS Width (mm)	Males	43.11±4.85	44.05±2.68	42.32±4.18	44.07±4.21	48.79±4.74	50.00±3.10	<0.001**
	Females	40.82±4.70	40.17±2.19	40.95±3.44	43.68±3.77	45.30±3.96	46.92±3.66	<0.001**
MS Index	Males	0.73±0.11	0.80±0.08	0.88±0.10	0.92±0.13	0.98±0.14	0.96±0.10	<0.001**
	Females	0.76±0.12	0.83±0.09	0.84±0.09	0.90±0.09	0.98±0.12	0.89±0.05	<0.001**
SS Height (mm)	Males	16.47±5.16	15.36±2.91	16.14±2.86	15.40±4.79	16.56±4.82	18.41±3.00	0.016
	Females	15.26±4.09	15.15±2.45	14.57±2.89	14.66±1.92	16.51±2.43	15.80±2.39	0.245
SS Width (mm)	Males	30.08±7.07	32.43±3.39	36.95±4.25	37.00±5.08	41.77±5.18	43.22±3.55	<0.001**
	Females	27.40±6.60	31.90±4.65	33.68±5.01	35.48±3.63	40.33±4.02	42.24±4.06	<0.001**
SS Index	Males	0.56±0.17	0.46±0.08	0.43±0.06	0.41±0.11	0.41±0.15	0.42±0.06	<0.001**
	Females	0.56±0.13	0.46±0.08	0.42±0.05	0.40±0.03	0.40±0.06	0.36±0.04	<0.001**

n= 224; SS - Sphenoidal Sinus; MS - Maxillary Sinus; SD – Standard Deviation; Kruskal-Wallis test; \* p<0.05; \*\*p<0.001

**Table-4: Comparison of MS and SS indices between adjacent cervical stages**

Indices	Gender	CS1 vs CS2 p-value	CS2 vs CS3 p-value	CS3 vs CS4 p-value	CS4 vs CS5 p-value	CS5 vs CS6 p-value
MS Index	Males	0.392	0.130	0.998	1.000	1.000
	Females	0.671	1.000	0.672	0.288	0.042
SS Index	Males	0.445	0.815	1.000	1.000	1.000
	Females	0.135	0.706	0.986	1.000	1.000

n = 224; SS - Sphenoidal Sinus; MS - Maxillary Sinus; p ≤ 0.05; Post-hoc Dunnett T3 test

**Table-5: Diagnostic performance of SS index in males**

		Cervical Vertebral Maturation		Kappa	p-value
		Pre-pubertal (CS1 – CS3) (n = 58)	Post-pubertal (CS4 – CS6) (n = 58)		
SS Index	Pre-pubertal (≥ 41%) (n = 59)	38	21	0.293	0.002
	Post-pubertal (<41%) (n = 57)	20	37		

n = 116; SS - Sphenoidal Sinus; Sensitivity - 65.52%; Specificity - 63.79%; PPV - 64.41%; NPV - 64.91%

**Table-6: Diagnostic performance of SS index in females**

		Cervical Vertebral Maturation		Kappa	p-value
		Pre-pubertal (CS1 – CS3) (n = 55)	Post-pubertal (CS4 – CS6) (n = 53)		
SS Index	Pre-pubertal (≥ 41%) (n = 57)	40	17	0.407	< 0.001
	Post-pubertal (<41%) (n = 51)	15	36		

n = 108; SS - Sphenoidal Sinus; Sensitivity - 72.73%; Specificity - 67.92%; PPV - 70.18%; NPV - 70.59%

**Table-7: Diagnostic performance of MS index in males**

		Cervical Vertebral Maturation		Kappa	p-value
		Pre-pubertal (CS1 – CS3) (n = 58)	Post-pubertal (CS4 – CS6) (n = 58)		
MS Index	Pre-pubertal (≥ 89%) (n = 55)	43	12	0.534	< 0.001
	Post-pubertal (< 89%) (n = 61)	15	46		

n = 116; MS - Maxillary Sinus; Sensitivity - 74.14%; Specificity - 79.31%; PPV - 78.18%; NPV - 75.41%

**Table-8: Diagnostic performance of MS index in females**

		Cervical Vertebral Maturation		Kappa	p-value
		Pre-pubertal (CS1 – CS3) (n = 55)	Post-pubertal (CS4 – CS6) (n = 53)		
MS Index	Pre-pubertal (≥ 89%) (n = 55)	39	16	0.407	< 0.001
	Post-pubertal (< 89%) (n = 53)	16	37		

n = 108; MS - Maxillary Sinus; Sensitivity - 70.91%; Specificity - 69.81%; PPV - 70.91%; NPV - 69.81%

## DISCUSSION

The development of the paranasal sinuses commences during the prenatal growth period. The MS being the largest of the paranasal sinuses is usually evident radiographically 5 months after birth. It continues to pneumatize both laterally and inferiorly during the growth periods from birth to 3 years of age and then from 7 to 12 years of age. The pneumatization of MS is completed by the age of 20 years.<sup>25,26</sup> The SS is evident radiographically as early as 2 years of age and pneumatize inferiorly and posterolaterally towards sphenoccipital synchondrosis and attains its mature size by the age of 14 years.<sup>27</sup>

The current study investigated the association between the MS and SS morphology and the CVM in a sample of growing children. MS height generally follows a linear pattern and successively increased from CS 1 through CS 6. However, a substantial increase in the MS width was seen after CS3. SS height did not vary significantly at different cervical stages signifying that the vertical growth of the sphenoidal air cells is usually completed before the onset of adolescent growth spurt. Similar results have been reported by previous studies<sup>28,29</sup> suggesting the use of different SS landmarks as the stable points for the superimposition of lateral cephalograms. Nevertheless, a linear increase in the SS width was noticed during pubertal growth spurt, changing the overall morphology of the sinus.

Growth is a continuous process thus dividing it into different discrete stages, as in CVM method, may not be justifiable.<sup>15</sup> In this context, use of SS and MS indices may be more appropriate. Use of sinus indices eliminates the bias associated with the use of mere length or width as they may vary according to patient's physical size and gender.<sup>30</sup> In addition, it eliminates the possible magnification errors in cephalometry and provides a more objective assessment of the adolescent growth spurt in contrary to a subjective CVM method.<sup>31</sup>

A gradual increase in the MS index was noticed from CS1 to CS6 depicting a relatively greater

increase in the MS height as compared to width (Figure 4). However, *post-hoc* analyses showed that the variations in the MS index cannot characterize adjacent cervical stages. The differential growth in the SS height and width resulted in significant variations in the SS index at different cervical stages. However, the SS index failed to recognize adjacent cervical stages (Figure-5), although the SS index varied significantly at different CVM stages.

In the current study, the sample was further divided into pre-pubertal peak and post-pubertal peak groups only and the diagnostic validity of MS and SS indices were evaluated. It showed that the SS index performed comparable to the MS index for female sample. For males, the MS index may be used as a more valid indicator as compared to SS index in correctly identifying the pubertal growth stage of an individual.

These results, based on only pre-pubertal and post-pubertal peak groups, may have a limited application since in clinical scenario the selection of a treatment modality is usually based on the different stages of adolescent growth spurt. Moreover, the current study tested the validity of SS and MS indices against the CVM method which itself has been shown to have dubious validity by a few studies.<sup>15,17,32</sup> Thus, implementation of a longitudinal study design and use of a more reliable indicator of skeletal maturity, such as hand and wrist radiographs, cannot be overemphasized.<sup>11</sup>

The limitations of the current study include the assessment of paranasal sinuses on lateral cephalograms which are three dimensional structures and their growth changes are best visualized using a volumetric imaging technique. Though the use of CBCT images offers this advantage, increase radiation exposure and cost remain the main drawbacks of this technique. Individual variations and structural superimpositions may result in errors associated with landmark identification for the assessment of sinus morphology on the lateral cephalogram.

## CONCLUSIONS

MS height, width and index are significantly associated with the CVM stages in males and females. SS height, width and index in males and only SS width and index in females are significantly associated with the CVM stages. A fair to moderate level of agreement is present between the MS and SS indices and CVM in assessing the pre-pubertal peak and post-pubertal peak growth status. The validity of SS and MS indices are comparable for females; whereas, the MS index offers a significant advantage over SS index for the assessment of growth status of males.

## AUTHORS' CONTRIBUTION

HTM: participated in study conception, data collection, statistical analysis and manuscript formatting. AS: participated in study conception and manuscript formatting. MF: participated in study conception and manuscript formatting. The final manuscript was read and approved by all the authors.

## REFERENCES

1. Proffit WR, Jackson TH, Turvey TA. Changes in the pattern of patients receiving surgical-orthodontic treatment. *Am J Orthod Dentofacial Orthop* 2013;143(6):793–8.
2. Broadbent JM. Crossroads: acceptance or rejection of functional jaw orthopedics. *Am J Orthod Dentofacial Orthop* 1987;92(1):75–8.
3. DiBiase AT, Cobourne MT, Lee RT. The use of functional appliances in contemporary orthodontic practice. *Br Dent J* 2015;218(3):123–8.
4. Singer J. Physiologic timing of orthodontic treatment. *Angle Orthod* 1980;50(4):322–33.
5. Hunter WS. The correlation of facial growth with body height and skeletal maturation at adolescence. *Angle Orthod* 1966;36(1):44–54.
6. Green LJ. The interrelationships among height, weight, and chronological, dental, and skeletal ages. *Angle Orthod* 1961;31(3):189–93.
7. Hagg U, Taranger J. Menarche and voice changes as indicators of the pubertal growth spurt. *Acta Odontol Scand* 1980;38(3):179–86.
8. Coutinho S, Buschang PH, Miranda F. Relationships between mandibular canine calcification stages and skeletal maturity. *Am J Orthod Dentofacial Orthop* 1993;104(3):262–8.
9. Kumar S, Singla A, Sharma R, Virdi MS, Anupam A, Mittal B. Skeletal maturation evaluation using mandibular second molar calcification stages. *Angle Orthod* 2011;82(3):501–6.
10. Grave KC, Brown T. Skeletal ossification and the adolescent growth spurt. *Am J Orthod* 1976;69(6):611–9.
11. Fishman LS. Radiographic evaluation of skeletal maturation: a clinically oriented method based on hand-wrist films. *Angle Orthod* 1982;52(2):88–112.
12. Houston WJ. Relationships between skeletal maturity estimated from hand-wrist radiographs and the timing of the adolescent growth spurt. *Euro J Orthod* 1980;2(2):81–93.

13. Cavanese F, Charles YP, Dimeglio A. Skeletal age assessment from elbow radiographs. Review of the literature. *Chir Organi Mov* 2008;92(1):1–6.
14. Lamparski DG. Skeletal age assessment utilizing cervical vertebrae [master's thesis]. Pittsburgh, Penn: Department of Orthodontics, The University of Pittsburgh; 1972.
15. Hassel B, Farman AG. Skeletal maturation evaluation using cervical vertebrae. *Am J Orthod Dentofacial Orthop* 1995;107(1):58–66.
16. Baccetti T, Franchi L, McNamara Jr JA. The cervical vertebral maturation (CVM) method for the assessment of optimal treatment timing in Dentofacial orthopedics. *Semin Orthod* 2005;11(3):119–29.
17. Nestman TS, Marshall SD, Qian F, Holton N, Franciscus RG, Southard TE. Cervical vertebrae maturation method morphologic criteria: poor reproducibility. *Am J Orthod Dentofacial Orthop* 2011;140(2):182–8.
18. Kumar S, Tripathi T, Sindhu MS, Grover S, Diwaker R. Sphenoid sinus as a mandibular growth prediction - Is it valid? *Indian J Dent Sci* 2015;7(1):54–5.
19. Mahmood HT, Shaikh A, Fida M. Association between frontal sinus morphology and cervical vertebral maturation for the assessment of skeletal maturity. *Am J Orthod Dentofacial Orthop* 2016;150(4):637–42.
20. Patil AA, Revankar AV. Reliability of the frontal sinus index as a maturity indicator. *Indian J Dent Res* 2013;24(4):523–3.
21. Ertuk N. Teleroentgen studies on the development of the frontal sinus. *Fortschr Kieferorthop* 1968;29(2):245–8.
22. Endo T, Abe R, Kuroki H, Kojima K, Oka K, Shimooka S. Cephalometric evaluation of maxillary sinus sizes in different malocclusion classes. *Odontology* 2010;98(1):65–72.
23. Dahlberg, G. *Statistical Methods for Medical and Biological Students*. New York, NY: Interscience, 1940; p.122–32.
24. Houston WJ. The analysis of errors in orthodontic measurements. *Am J Orthod* 1983;83(5):382–90.
25. Graney DO, Rice DH. *Anatomy*. In: Cummings CW, Fredrickson JM, Harker LA, Krause CJ, Schuller DE, editors. *Otolaryngology: head and neck surgery*, 2nd ed. St. Louis: Mosby Year Book, 1993; p.901–6.
26. Sharan A, Madjar D. Maxillary sinus pneumatization following extractions: A radiographic study. *Int J Oral Maxillofac Implants* 2008;23(1):48–56.
27. Scuderi AJ, Harnsberger HR, Boyer RS. Pneumatization of the paranasal sinuses: normal features of importance to the accurate interpretation of CT scans and MR images. *AJR Am J Roentgenol* 1993;160(5):1101–4.
28. Arat M, Köklü A, Ozdiler E, Rübendüz M, Erdoğan B. Craniofacial growth and skeletal maturation: a mixed longitudinal study. *Eur J Orthod* 2001;23(4):355–63.
29. Arat ZM, Rübendüz M, Arman Akgül AA. The displacement of craniofacial reference landmarks during puberty: a comparison of three superimposition methods. *Angle Orthod* 2003;73(4):374–80.
30. Shapiro R, Schorr S. A consideration of the systemic factors that influence frontal sinus pneumatization. *Invest Radiol* 1980;15(3):191–202.
31. Grummons DC, Kappeyne van de Coppello MA. A frontal asymmetry analysis. *J Clin Orthod* 1987;21(7):448–65.
32. Santiago RC, de Miranda Costa LF, Vitral RW, Fraga MR, Bolognese AM, Maia LC. Cervical vertebral maturation as a biologic indicator of skeletal maturity: a systematic review. *Angle Orthod* 2012;82(6):1123–31.

Received: 19 September, 2017

Revised: 8 April, 2018

Accepted: 6 May, 2018

### Address for Correspondence:

**Dr. Hafiz Taha Mahmood**, Section of Dentistry, Department of Surgery, The Aga Khan University Hospital, P.O Box 3500, Stadium Road, Karachi 74800-Pakistan

**Cell:** +92 332 256 3940

**Email:** taha.mahmood@aku.edu, dr.tahamahmood@gmail.com