

A RETROSPECTIVE STUDY OF OVARIAN TUMOURS AND TUMOUR-LIKE LESIONS

Samina Zaman, Sarosh Majid*, Mahvish Hussain, Omer Chughtai**, Javed Mahboob**,
Sohail Chughtai**

Department of Histopathology, Institute of Child Health and Children's Hospital, *Postgraduate Medical Institute, **Chughtai's
Laboratory, Lahore, Pakistan

Background: Ovaries are common site of non-neoplastic and neoplastic lesions. They can present from the neonatal period to post menopause. Most are functional in nature and resolve with minimal treatment. Objective of the study was to determine the nature of various ovarian lesions and to ascertain the frequency and distribution of the various non-neoplastic and neoplastic lesions. **Methods:** The study was a retrospective review of all cases of ovarian cancer, benign ovarian neoplasm and functional ovarian cysts received during Jan–Dec 2008 at Chughtai's Lahore Laboratory. The clinical data of the patients was obtained from their respective files. **Results:** A total of 498 different non-neoplastic and neoplastic lesions were seen during one calendar year 2008. Non-neoplastic cysts were more common (343, 68.87%) than neoplastic tumours (155, 31.12%). The commonest non-neoplastic cyst was luteal cyst followed by follicular cyst. Among the neoplastic tumours 78.70% were benign and 21.29% were malignant. Benign serous cysts were the commonest benign tumour followed by mature cystic teratoma and mucinous cyst. Serous cystadenocarcinoma was the commonest malignant tumour followed closely by endometrioid carcinoma and granulosa cell tumour. Krukenberg tumour, tumour metastatic to ovaries and non-Hodgkins lymphoma was also diagnosed during this period. Malignant germ cell tumours were seen in much younger age group followed by sex cord stromal tumours. Epithelial tumours were seen in much older age group. **Conclusion:** The morphologic diversity of ovarian masses poses many challenges. A specific diagnosis can usually be made by evaluating routinely stained slides but sometimes immunohistochemistry is required in difficult cases. Gross features also provide useful diagnostic clues.

Keywords: Ovarian functional cysts, ovary, ovarian neoplasm

INTRODUCTION

A number of non-neoplastic and neoplastic lesions occur within the ovaries. They can present from the neonatal period to post-menopause. Most are functional in nature and resolve with minimal treatment. However, ovarian cysts can herald an underlying malignant process. When cysts are large, persistent, or painful, surgery may be required.^{1,2}

Some of the non-neoplastic lesions can be confused with neoplasm clinically, intraoperatively, or on pathological examination.³ Differentiation between many different cystic ovarian abnormalities with non-malignant features is relevant since proper treatment depends on the histological abnormality. Ovarian carcinoma is the 5th most common cause of cancer related deaths in Western world and leading cause of death from gynaecologic malignancy.⁴⁻⁶ The 5 year survival is only 30–40% and is due to the fact that most ovarian cancers are inoperable when first discovered. There is no reliable mean for early detection except for genetic screening in high risk individuals.⁶ The understanding of the molecular pathogenesis of ovarian cancer has been hindered by the lack of sufficient number of specimens at early-stage disease. As a result identifiable precursor lesions that ultimately develop into ovarian cancer are still debatable.⁵ The aetiology of ovarian cancers is poorly understood. Previous

epidemiological studies have focused on aetiology of epithelial tumours and found advanced age, nulliparity and a family history of ovarian cancer to be consistently associated with an increased risk while number of pregnancies, oral contraceptive (OC) use and history of hysterectomy or tubal ligation has been found to be associated with a decreased risk. Factors like age at menarche/menopause, age at first childbirth, Hormone Replacement Therapy (HRT), infertility and fertility drug use, breastfeeding, obesity, diet, talc use, smoking, and alcohol or coffee consumption, are found to have no conclusive association. On the other hand, few studies have focused on aetiology of non-epithelial ovarian tumours. It has been observed that an elevated risk of germ cell ovarian cancer occur among girls and young women, the mothers of whom were under 20 years of age at time of pregnancy, had used exogenous hormones during the pregnancy or had a high pre-pregnancy body mass whereas history of oral contraceptives use or oestrogen replacement therapy was associated with a decreased risk of developing sex cord-stromal ovarian tumors.⁷⁻⁹

Carcinomatous processes of the ovary, both primary and metastatic, frequently are complicated by cystic degeneration. Malignant neoplasms include epithelial ovarian carcinoma (70% of all ovarian malignancies), germ-cell tumours (20%), sex-cord

stromal tumours (5%), other rare types and metastases to the ovaries. Subtypes of epithelial tumours include serous, mucinous, endometrioid, clear cell, and Brenner tumours. Germ cell tumours (GCTs) include mature teratoma, dysgerminoma, endodermal sinus tumour (yolk sac tumour), malignant teratoma, embryonal carcinoma, and choriocarcinoma. Sex cord stromal tumours include tumours arising from the sex cords, granulosa cells, Sertoli cells, and the specialised stroma of the genital ridge, theca, and Leydig cells.¹⁰ The objectives of study were to determine the nature of various ovarian lesions and to ascertain the frequency and distribution of the various non-neoplastic and neoplastic lesions.

MATERIAL AND METHODS

This was a retrospective analysis of all cases of ovarian cancer, benign ovarian neoplasms and functional ovarian cysts received in year 2008 at Chughtais Lahore Lab. All cases were identified through a computerised search of a surgical pathology database. Data regarding age, size and tumour histology were collected from medical records. Routine H/E staining was performed. Immunohistochemistry (IHC) was done in difficult cases and included cytokeratin, Epithelial Membrane Antigen (EMA), Inhibin and Leukocyte Common Antigen (LCA).

RESULTS

A total of 498 different non-neoplastic and neoplastic lesions of ovaries were seen in 445 patients with 53 patients having double pathology. These cases were seen during one calendar year from Jan–Dec 2008.

Non-neoplastic ovarian cysts or masses were more common (343, 68.87%) than neoplastic tumours (155, 31.12%). The commonest non-neoplastic lesion diagnosed was luteal cyst (155, 45.19%) followed by follicular cyst (99, 28.86%), endometriotic cyst (48, 13.99%) and simple cyst (41, 11.95%) (Table-1). The age range with mean age and size range with mean size of different non-neoplastic lesions are given in Table-2.

Neoplastic tumours (155, 31.12%) included benign (122, 78.70%) as well as malignant cases (33, 21.29%). Epithelial neoplasms accounts for 106 cases (68.38 %) majority were serous in type being serous cysts/cystadenomas (55, 35.48%), serous cystadenofibromas (4, 2.58%), serous borderline (1, 0.64%) and serous cystadenocarcinoma (7, 4.51%). Mucinous tumours were the second most common epithelial neoplasms accounting for 31 cases (20.0%) with 29 (18.70%) benign mucinous cysts/ cystadenoma and 2 cases (1.29%) of mucinous cystadenocarcinoma. Six cases (3.87%) of endometrioid carcinoma were diagnosed during this period with 1 case (0.64%) having simultaneous endometrioid carcinoma of the uterus and 1 case (0.64%) had associated endometriosis of the

ovary. There were 2 cases (1.29%) of Brenner tumours, 1 benign and one malignant. No case of clear cell carcinoma was seen. Germ cell tumours were next in frequency (37, 23.87%) consisting of mature teratoma (30, 19.35%, Figure-1); Struma ovarii (2, 1.29%), dysgerminoma (3, 1.93%, Figure-2); yolk sac tumour (1, 0.64%) and malignant mixed germ cell tumour (1, 0.64%). Sex cord tumours were relatively uncommon (9, 5.80%). Granulosa cell tumour was most commonly seen among this group (6, 3.87%, Figure-3), with 1 case each of Sertoli Leydig cell tumour, hilar cell tumour and fibroma. One case each of Krukenberg tumour, metastatic tumour from breast and Non-Hodgkin lymphoma were also diagnosed.

Age range with mean age and tumour size range along with mean size of neoplastic lesions is given in Table-3. The largest size of tumour was seen in mucinous cystadenoma followed by dysgerminoma and yolk sac tumour. Malignant germ cell tumours were seen in much younger age group followed by sex cord stromal tumours. Epithelial tumours were seen in much older age group.

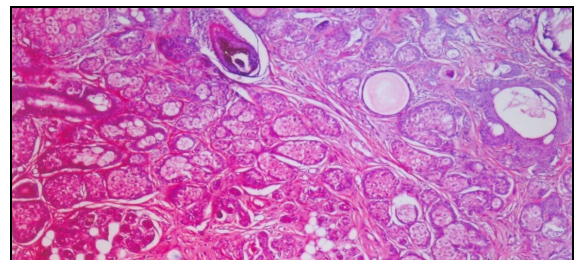


Figure-1: Mature Teratoma

Photomicrograph showing skin adnexae and adipose tissue ×100

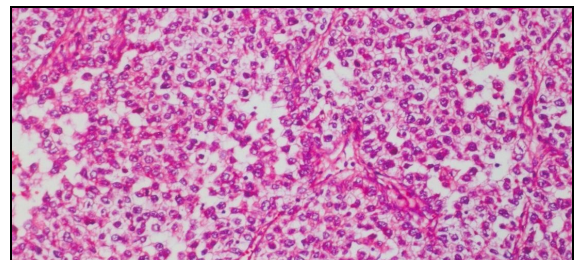


Figure-2: Dysgerminoma

Photomicrograph showing well defined nests of tumour cells separated by fibrous strands ×200

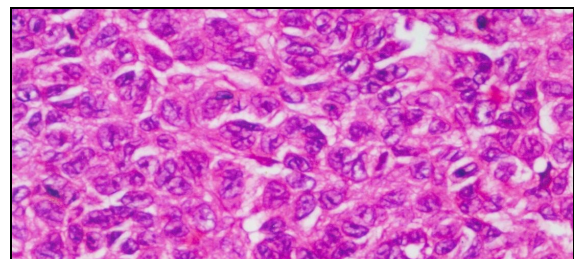


Figure-3: Granulosa Cell Tumour

Photomicrograph showing neoplastic cells arranged in sheets with prominent nuclear grooving imparting coffee bean appearance ×400

Table-1: Incidence of non-neoplastic ovarian lesions

Type	Number	%
Luteal cyst	155	45.19
Follicular cyst	99	28.86
Endometriotic cyst	48	13.99
Simple cyst	41	11.95

Table-2: Patients' age and size of non-neoplastic lesions

Type of Cysts	Age of patients		Tumour size	
	Range Years	Mean Years	Range Cm	Mean Cm
Luteal Cvst	13-56	35.41	1.2-9	3.76
Follicular Cvst	13-55	37.67	1.5-8	3.95
Endometriotic Cvst	17-50	30.28	1-13	5.98
Simple Cvst	16-80	38.17	1-10.5	4.38

Table-3: Age of patients and tumour size of neoplastic lesions

Type of Tumours	Age of patients (Yr)		Tumour size (Cm)	
	Range	Mean	Range	Mean
SURFACE EPITHELIAL TUMORS				
Serous Cysts	18-66	34.07	2.5-23	7.71
Serous cystadenofibromas	18-65	35.28	3-15	7.67
Borderline Papillary cystadenofibromas	40	40	10	10
Serous cystadenocarcinoma	35-55	45.74	9-15	6.28
Mucinous cystadenomas	14-65	34.37	3.5-27	14.29
Mucinous adenocarcinoma	15-35	25	5-13	9
Endometrioid carcinoma	30-60	43.33	5.5-10	7.75
Benign Brenner	40	40	7	7
Malignant Brenner	45	45	10	10
SEX CORD STROMAL TUMORS				
Granulosa Cell Tumours	25-65	39.14	2-10	7.71
Fibromas	41	41	12.2	12.2
Hilar Tumours	35	35	4	4
Sertoli Leydig Cell Tumour	55	55	5.3	5.3
GERM CELL TUMORS				
Mature Cystic Teratomas	15-55	29.06	6-8	8.91
Struma Ovarii	15-55	35	6-8	5.25
Dysgerminoma	13-22	17	16-17	16.5
Yolk Sac Tumours	15	15	18	18
Mixed Germ Cell Tumours	17	17	14	14
MISC				
Metastatic Tumours	30	30	9	9
Krukenberg Tumour	51	51	12	12
NHL	22	22	10	10

DISCUSSION

Most adnexal cysts removed at surgery are benign or functional. It has been found that ovarian functional cysts were fourth most common gynaecologic cause of hospital admission in the United States in the late 1980s. Thus, surgery may represent over treatment in these patients, and the cost and risks may outweigh the benefits. Moreover, the possibility of malignant transformation of ovarian cysts remains unknown. Simple ovarian cysts do not usually become malignant. Nevertheless, the diagnosis of an ovarian cyst causes anxiety, mainly because of the fear of malignancy.¹¹

Two functional ovarian cysts may develop: follicular cysts occurring in the first 2 weeks of the cycle, whereas corpus luteal cysts occur in the later half of the cycle. Failure of corpus luteum degeneration leads to a luteal cyst formation. These cysts may become inflamed or spontaneously bleed, producing symptoms. Other cysts include endometriomas which are cysts filled with blood from ectopic endometrium.^{1,2}

A study by Eriksson *et al* quoted by De Kroon *et al* demonstrated that two-third of the cystic ovaries that required surgery were found to be functional cysts.¹² We also had similar observation as non-

neoplastic lesions seen were 68.87%. Luteal and follicular cysts were the most commonly diagnosed cysts. This is similar to a study from India¹³, and Tayyiba *et al*¹⁴ and Choi *et al*¹⁵.

In the present study the mean size of luteal cyst was 3.7 Cm (range 1.2-9 Cm), of follicular cyst was 3.9, (range: 1.5-8 Cm), of endometriotic cyst was 5.9 Cm (range: 1-13 Cm) and of simple cyst was 4.3 Cm (range 1-10 Cm). These mean sizes were slightly less than those reported by Mesogitis *et al* in Greece.¹¹

In spite of all the advances made in the fields of cancer diagnosis and treatment, ovarian carcinoma remains the leading cause of mortality.¹⁶ Memon *et al* found that ovary is among the five most frequent sites involved by malignancy in females in Pakistan.¹⁷ In present study 155 cases of benign and malignant tumours were recorded in 1 year. Benign serous tumours including serous cysts and cystadenofibroma were the commonest benign tumour constituting 38.06% followed by mature teratoma (19.35%) and mucinous cyst (18.70%). However, Ong *et al* found that teratoma is the commonest benign ovarian neoplasm.¹⁸ Benign serous and mucinous tumours are common but benign endometrioid tumours are very rare.^{19,20} We

found no case of benign endometrioid tumour. Kooning *et al* found that epithelial tumours represent 60% of all ovarian neoplasm and 85% of malignant ovarian neoplasm.²¹ Bushra *et al* also reported 96% epithelial tumours in her series.²² This is in contrast to our study as only 68.38% epithelial tumours were diagnosed with 17 cases of malignant epithelial tumours accounting for 51.51% of all malignant neoplasms.

Epithelial tumours are rare in children but their prevalence increases with age and peaks in 6th and 7th decades of life.²¹ In our study most of the epithelial tumours are seen in 5th and 6th decades. We found no case of epithelial neoplasm in 1st decade and only 5 cases in 2nd decade. Borderline ovarian tumours are of low malignant potential having favourable prognosis and relatively early age at onset.²³ They comprise 4%–14% of all epithelial ovarian neoplasms.²⁴ However, we diagnosed a single case of borderline serous papillary neoplasm (0.64%) during this period in a 40 year old female. In the present study, serous cystadenocarcinoma (4.51%) was the commonest malignant epithelial neoplasm closely followed by endometrioid carcinomas (3.87%). Mucinous cystadenocarcinoma was found in only 1.29% of cases, the frequency of which is much less compared to those reported in literature. Endometrioid carcinoma represent 10–15% of all ovarian cancers with about 15–30% having synchronous endometrial carcinoma and is most common tumour to be associated with endometriosis.¹⁰ This is in agreement with our study as 16.66% of these tumours were seen with synchronous endometrial carcinoma and endometriosis. Clear cell carcinomas represent approximately 5% of ovarian carcinomas.¹⁰ We found no case of clear cell carcinoma. Brenner tumours represent about 2–3% of ovarian tumours and are rarely malignant.^{10,25,26} We diagnosed two cases with one being malignant. Tumours of germ cell origin are the second most common group of ovarian neoplasms, representing 15–20% of all ovarian tumours. Of all the germ cell tumours, only mature teratoma is benign and is the most common lesion in this group.²⁷ This is consistent with our findings. All other germ cell tumours are malignant and account for less than 5% of malignant ovarian tumours. Elevated levels of serum α -fetoprotein and human chorionic gonadotropin (HCG) are usually present and can also help establish the diagnosis. Dysgerminomas are rare ovarian tumours (2%) that occur predominantly in young women. This tumour is the ovarian counterpart of seminoma of the testis.¹⁰ Frequency of dysgerminoma observed in our series is 1.93%. Endodermal sinus tumour, also known as yolk sac tumour, is a rare malignant ovarian tumour that usually occurs in the second decade of life.¹⁰ Our findings are consistent with these facts.

Sex-cord stromal tumours represent approximately 8% of ovarian neoplasms and affect all

age groups. These tumours are of interest because of their hormonal effects which are rare in other ovarian neoplasms. Granulosa cell tumour is the most common malignant sex-cord stromal tumour as well as the most common oestrogen-producing ovarian tumour. Adult granulosa cell tumours are far more common than the juvenile type. They occur predominantly in peri- and postmenopausal women.^{10,28} This is comparable to our findings.

Metastases to the ovaries are relatively frequent with the most common being from the endometrium, breast, colon, stomach, and cervix.¹⁰ However, in present study there was only one case of Krukenberg tumour and one case of metastases from breast tumour. Non-Hodgkins Lymphoma is very rare and can present as bilateral ovarian masses. We diagnosed a single case of NHL in young female of 22 years presenting with bilateral ovarian masses. Majority of malignant tumours (62.64%) and a good number of benign tumours (40.16%) are more than 10 Cm in size. Mucinous cystadenomas tend to be larger than serous cyst at presentation. Immunohistochemistry is an important diagnostic tool in evaluation of ovarian tumors.²⁹ It is especially useful in diagnosing tumours with follicles or other pattern which bring a sex-cord stromal tumour into differential.³⁰ We performed different markers for proper diagnosis in difficult cases.

CONCLUSION

The morphological diversity of ovarian cysts and masses poses many challenges. The best way to exclude malignancy is proper histological examination but this requires surgery. A specific diagnosis can usually be made by evaluating routinely stained slides, but much less often, special stains and IHC staining is also required. Clinical data, operative findings and gross features of the lesions may provide important, and at time decisive diagnostic clues.

ACKNOWLEDGEMENTS

We are thankful to Prof. Tahir Masood Ahmad, Dean, Children's Hospital and Institute of Child Health for providing the work facilities. Dr. Ghazala Hanif deserves special thanks for her valuable suggestions. We also thank our technician Mr. Anayat for his very responsible attitude throughout this work.

REFERENCES

1. Grimes DA, Jones LB, Lopez LM, Schulz KF. Oral contraceptives for functional ovarian cysts. *Cochrane Database Syst Rev* 2006;4:CD006134.
2. Holt VL, Cushing-Haugen KL, Daling JR. Risk of Functional Ovarian Cyst: Effects of Smoking and Marijuana Use according to Body Mass Index. *Am J Epidemiol* 2005;161:520–5.
3. Clement PB. Selected miscellaneous ovarian lesions: small cell carcinomas, mesothelial lesions, mesenchymal and

- mixed neoplasms, and non-neoplastic lesions. *Modern Pathol* 2005;18:113–29.
4. Shah S, Hishikar VA. Incidence and Management of Ovarian Tumors. *Bombay Hospital J* 2008;50(1):30–3.
 5. Stewart SL, Querec TD, Ochman AR, Gruver BN, Bao R, Babb JS, *et al.* Characterization of a Carcinogenesis Rat Model of Ovarian Preneoplasia and Neoplasia. *Cancer Res* 2004;64:8177–83
 6. Auersperg N, Wong AST, Choi KC, Kang SK, Leung PCK. Ovarian Surface Epithelium: Biology, Endocrinology, and Pathology. *Endocr Rev* 2001;22(2):255–88.
 7. Jung SE, Lee JM, Rha SE, Byun JY, Jung JI, Hahn ST. CT and MR Imaging of Ovarian Tumors with Emphasis on Differential Diagnosis. *Radiographics* 2002;22:1305–25.
 8. Ness RB, Grisso JA, Cottreau C, Klapper J, Vergona R, Wheeler JE, *et al.* Factors Related to Inflammation of the Ovarian Epithelium and Risk of Ovarian Cancer. *Epidemiology* 2000;11(2):111–7
 9. Zhang J, Ugnat AM, Clarke K, Mao Y. Ovarian cancer histology-specific incidence trends in Canada 1969-1993: age-period-cohort analyses. *British Journal of Cancer* 1999;81(1):152–8.
 10. Herbst AL. The Epidemiology of Ovarian Carcinoma and the Current Status of Tumor Markers to Detect Disease. *Am J Obstet Gynecol* 1994;170:1099–107.
 11. Mesogitis S, Daskalakis G, Pilalis A, Papantoniou N, Thomakos N, Dessipris N, *et al.* Management of Ovarian Cysts with Aspiration and Methotrexate Injection. *Radiology* 2005;235:668–73.
 12. De Kroon CD, Van der Sandt HAGM, Van Houwelingen JC, Jansen FW. Sonographic assessment of non-malignant ovarian cysts: does sonohistology exist? *Hum Reprod* 2004;19(9):2138–43.
 13. Gupta N, Bisht D, Agarwal AK, Sharma VK. Retrospective and prospective study of ovarian tumors and tumor like lesions. *Indian J Pathol Microbiol* 2007;50:525–7.
 14. Wasim T, Majrooh A, Siddiq S. Comparison of clinical presentation of Benign and Malignant Ovarian Tumors. *J Pak Med Assoc* 2009;59(1):18–21.
 15. Choi HJ, Kim SH, Kim HC, Park CM, Lee HJ, Moon MH, *et al.* Ruptured Corpus Luteal Cyst: CT Findings. *Korean J Radiol* 2003;4:42–5.
 16. Averette HE, Donato DM. Ovarian carcinoma, advances in diagnosis, staging and treatment. *Cancer* 1990;65:703–8.
 17. Memon MH, Memon I, Memon RA. The changing pattern of malignant diseases in Sindh province. *Pak J Pathol* 1992;3:17–20.
 18. Ong HC, Chan WF. Mucinous cystadenoma, serous cyst adenoma and benign cystic teratoma of ovary-clinicopathologic differences observed in Malaysian hospital. *Cancer* 1978;41:1538–42.
 19. Jeong YY, Outwater EK, Kang HK. Imaging evaluation of ovarian masses. *Radiographics* 2000;20:1445–70.
 20. Kawamoto S, Urban BA, Fishman EK. CT of epithelial ovarian tumors. *Radiographics* 1999;19:S85–S102.
 21. Koonings PP, Campbell K, Mishell DR Jr, Grimes DA. Relative frequency of primary ovarian neoplasms: a 10-year review. *Obstet Gynecol* 1989;74:921–6.
 22. Rafiq B, Kokab H, Rao SI. Ovarian tumors. *Professional Med J* 2005;12(4):397–403.
 23. Levi F, Vecchia CL, Randimbison L, Te VC. Borderline ovarian tumors in Vaud, Switzerland: incidence, survival and second neoplasms. *Br J Cancer* 1999;79(1):4–6.
 24. Burkholz KJ, Wood BP, Zuppan C. Best Cases from the AFIP: Borderline papillary serous tumor of the right ovary. *Radiographics* 2005;25:1689–92.
 25. Moon WJ, Koh BH, Kim SK, Kim YS, Rhim HC, Cho OK, *et al.* Brenner tumor of the ovary: CT and MR findings. *J Comput Assist Tomogr* 2000;24:72–6.
 26. Outwater EK, Siegelman ES, Kim B, Chiowanich P, Blasbalg R, Kilger A. Ovarian Brenner tumors: MR imaging characteristics. *Magn Reson Imaging* 1998;16:1147–53.
 27. Outwater EK, Siegelman ES, Hunt JL. Ovarian teratomas: tumor types and imaging characteristics. *Radiographics* 2001;21:475–90.
 28. Jung SE, Rha SE, Lee JM, Park SY, Oh SN, Cho KS, *et al.* CT and MRI Findings of Sex Cord-Stromal Tumor of the Ovary. *AJR Am J Roentgenol* 2005;185:207–15.
 29. Baker PM, Oliva E. Immunohistochemistry as a Tool in the Differential Diagnosis of Ovarian Tumors: An Update. *Int J Gynecol Pathol* 2005;24(1):39–55.
 30. McCluggage WG, Young RH. Immunohistochemistry as a diagnostic aid in the evaluation of ovarian tumors. *Semin Diagn Pathol* 2005;22(1):3–32.

Address for Correspondence:

Dr. Samina Zaman, 266 H-1, Johar Town, Lahore, Pakistan. **Cell:** +92-333-4237548

Email: drsaminazaman@hotmail.com