

PICTORIAL

THE APATHETIC GUT

Rubab Ali, Aun Raza Shah*

BMI Blackheath Hospital, 40-42 Lee Terrace, London, *North Devon District Hospital, Raleigh Road, Barnstaple, Devon-UK

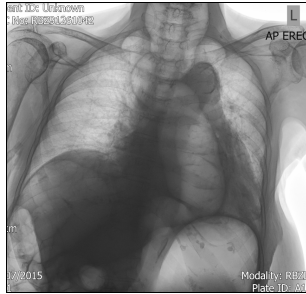

Figure-1: Chest X-ray with inverted gray scale

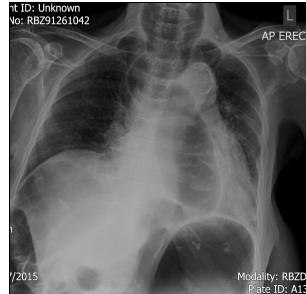


Figure-2: Plain chest X-ray

Citation: Ali R, Shah AR. The apathetic gut. J Ayub Med Coll Abbottabad 2018;30(1):147.

An 86-year-old female managed on long-term low-dose prednisolone for limited systemic sclerosis, presented to her GP with progressive difficulty in swallowing and globus sensation for a few months. She was referred to an ENT surgeon, who found her to have a benign non-toxic multinodular goiter and an agreement was made on conservative management. This included an ongoing input from Speech & Language therapists and an upper GI endoscopy that revealed no abnormality.

Despite these measures, her symptoms continued to worsen over the next year until she was admitted to the hospital with dysphagia, regurgitation and probable aspiration. Plain X-rays revealed marked dilation of the alimentary canal in its entirety. Thorough surgical assessment did not disclose any gastrointestinal obstruction. Upper GI endoscopy undertaken at this time showed a dilated tortuous megaesophagus with almost absolute atony of the gastroesophageal junction. Subsequent video fluoroscopy identified complete absence of peristalsis in the esophagus. A clinical diagnosis of GI dysmotility secondary to systemic sclerosis was made and patient was thereon planned to have swallow therapy, diet modification and management of her symptoms as required.

Systemic sclerosis; both diffuse and limited, can affect any part of the GI tract, the hallmark pathology being dysmotility and fibrosis. Up to 50% of patients have some degree of symptomatic GI involvement, with esophagus being the most commonly affected part of the alimentary canal. The pathogenesis of GI manifestations is hypothesized to progress from neuronal dysfunction to smooth muscle atrophy to the final stage of fibrosis, which heralds irreversible dysfunction and poor prognosis. This unfortunately was the stage seen in our patient, with little to no room for improvement.

Received: 5 March, 2017	Revised: --	Accepted: 28 March, 2017
-------------------------	-------------	--------------------------

Address for Correspondence:

Aun Raza Shah, North Devon District Hospital, Raleigh Road, Barnstaple, Devon-UK

Cell: +92 333 539 4167

Email: aun.raza.shah@hotmail.com