

## ORIGINAL ARTICLE

SURGICAL TREATMENT IN LUMBAR SPONDYLOLISTHESIS:  
EXPERIENCE WITH 45 PATIENTS

Ibrahim Farooq Pasha, Muhammed Abid Qureshi\*, Irfan Zafar Haider,  
Arsalan Sharif Malik\*\*, Muhammad Asad Qureshi\*\*\*, Usama Bin Tahir†

Department of Orthopaedic Surgery, Combined Military Hospital, Peshawar, \*Department of Orthopaedic Surgery, Benazir Bhatta Hospital, Rawalpindi, \*\*Department of Surgery, Combined Military Hospital, Abbottabad, \*\*\*Department of Surgery, Combined Military Hospital, Peshawar, \*\*\*\*Department of Ortho-Spine Surgery, Combined Military Hospital/Army Medical College, Rawalpindi, †King Edward Medical University, Lahore, Pakistan

**Background:** Spondylolisthesis is forward slipping of upper vertebra in relation to its lower one, which at times requires surgery. The objective of present study is to document the outcome of surgical treatment in spondylolisthesis of lumbosacral region. **Methods:** We reviewed outcome of surgery in 45 patients with spondylolisthesis. Improvement in pain intensity, neurological status and union achieved after surgery was studied. All patients requiring surgical treatment were included in the study. The patients were operated by single spine surgeon. A Performa was made for each patient and records were kept in a custom built Microsoft access database. **Results:** Majority of our patient were in 4<sup>th</sup> and 5<sup>th</sup> decade with some male domination. Pain was main indication for surgery which was excruciating in 6, severe in 33, and moderate in 6 cases. The neurological status was normal in 34 cases while 11 patients had some deficit. L5–S1 was affected in 26, L4–L5 in 13 and multi or high level was found in rest of cases. Slip grade was measured with Meyerding grades, 18 had grade II, 15 had I, 9 had III and 3 had IV spondylolisthesis. Posterior lumbar inter body fusion (PLIF) was done in 24 patients, posterolateral, transforaminal lumbar inter body and anterior inter body fusion in others. Translaminar screw fixation, transpedicular transdiscal transcorporeal and Delta fixation in some cases. Pedicle screw fixation was done in most cases, AO fixator interna and 4.5 mm screw in others. Average follow up was 2 years and 5 months, max 5 years and minimum 6 months. Pain relief was achieved in 82%, neurological improvement 60% and union in 91% cases. There was no deterioration of neurological status, two implant failure and one wound infection. **Conclusion:** Surgical procedure for Spondylolisthesis must be individualised. Young patients with spondylolysis can be treated with osteosynthesis and sparing of motion segment. PLIF provides satisfactory results in majority of low to moderate cases with some reduction. Transpedicular transdiscal transcorporeal and delta fixation is good procedure for severe slips in adult.

**Keywords:** Spondylolisthesis, Spondylolysis, Pedicle screw fixation, Posterior lumbar inter body fusion

## INTRODUCTION

Spondylolisthesis is forward slipping of upper vertebra in relation to its lower one which is classified by Wiltse and Rothman into dysplastic, Ishtmic, Degenerative, traumatic, pathologic and iatrogenic.<sup>1</sup> The degree of slip is measured with Meyerding grades into I, II, II, IV and V or spondyloptosis.<sup>2</sup> Meyerding grade I and II are low and Meyerding grade 3, 4, or 5 are high.<sup>3</sup> Isthmic type 2 is most common in young individuals and its aetiology is uncertain, causation appears to be multifactorial<sup>4</sup>, while degenerative is most common in older age group. The incidence of spondylolisthesis is 5–6% in white males and 2–3% in females. The most common site is L5–S1 in 82%, L4–5 in 11%, L3–4 0.5% and L2–3 0.5% cases.<sup>5</sup> Spondylolysis represents a weakness or stress fracture in the bony bridge that connect the upper with the lower facet joints and usually presents with backache aggravated by activity.<sup>6</sup>

A high pelvic incidence results in high shear forces at lumbosacral junction and is associated with slippage. In L5–S1 spondylolisthesis, it has been clearly

demonstrated that an abnormal sacro-pelvic orientation can disturb sagittal balance of the spine.<sup>7</sup> The factors related to the disability and physical functions are important in standing and can be studied using axially loaded magnetic resonance imaging (MRI).<sup>8</sup> The angular instability of the intervertebral disc also play more important role than neurological compression in the pathogenesis and disability.<sup>9</sup>

The treatment is conservative or operative, conservative treatment is generally recommended in patients when there is no neurologic deficit, pain is tolerable or short duration, improvement by exercise program or by brace treatment and high patient co morbidity. This is better in low grade and less mobile slips, once this fails the operative treatment is better regardless of spondylolisthesis grade, disc height or mobility.<sup>10</sup> When operative treatment is considered, options are osteosynthesis of the defect or spondylodesis with adjacent segment. Direct repair of the pars defect is a logical alternative to spondylodesis as it helps to preserve the motion segment and prevents abnormal stresses at the adjacent levels.<sup>11</sup> Osteosynthesis with

motion segment preservation can be achieved with Bucks fusion, Morscher Screw and hook Fixation<sup>12</sup>, sublaminar wiring (Scott's Operation) and bone grafting without instrumentation. Laminoplasty can be done in grade I and II slips.<sup>13</sup> Spondylodesis, fusion with adjacent segment can be achieved by posterolateral lumbar fusion (PLF), posterior lumbar inter body fusion (PLIF)<sup>14</sup>, transforamina lumbar inter body fusion (TLIF)<sup>15</sup>, anterior and posterior combined fusion<sup>16</sup>. Other methods are transpedicular transdiscal transcorporeal screw fixation (TPTDTC)<sup>17</sup>, delta fixation, extreme lumbar inter body fusion (XLIF), axial lumbar inter body fusion (AXIA-LIF), anterior lumbar inter body fusion (ALIF)<sup>18</sup> and Vertebrectomy (Gaine's procedure).

The results are comparable if fusion is done with bone chips alone or with artificial cages but the cages provide better functional outcomes after posterior lumbar interbody fusion.<sup>19</sup> The fusion can be done with reduction or without reduction.<sup>17</sup> The spondylolisthesis surgery is cost effective in long term.

## MATERIAL AND METHODS

Forty-five Patients requiring operation were included in the study and the patients unfit, unwilling or being treated conservatively excluded. The patients were operated by single spinal surgeon. A Performa was made for each patient and records were kept in a custom built Microsoft access database. The consent was obtained from the patients and Hospital Ethical Board.

Posterior approach was made for PLF, PILF, TLIF, TPTDTC and Delta fusion. Anaesthetised patients were operated in prone position over pillows. All pedicle screws were placed using anatomical land marks and confirmed under image intensifier for level and position. Anterior retroperitoneal approach was made for ALIF. Improvement in pain intensity, neurological status and union achieved after surgery was studied. Graphic rating scale (GRS) using descriptive terms such as mild, moderate, severe and pain as bad as it could be (excruciating) was used as a tool to describe patients pain, pre and post operatively.<sup>20</sup> The neurologic deficit was described as per American Spinal Association Injury impairment scale (AIS), AIS-E normal, AIS-D less than normal, AIS-C antigravity power, AIS-B Power with gravity excluded and AIS-A complete deficit.<sup>21</sup> Union was assessed clinically, functional radiography and thin slice computer tomography (thin slice 3-D CT).

## RESULTS

Majority of 45 of our patient were in 4<sup>th</sup> and 5<sup>th</sup> decade (Table-1), with some male domination 24 (53.33%) male and 21 (46.66%) female. Pain was main indication for surgery which was severe in 33 (73.33%), excruciating in 6 (13.33%) and moderate in 6 (13.33%)

cases. The neurological status was AIS-E in 34 (75.55%) cases while AISD in 9 (20%) and AIC in 2 (4.44%) patients. L5-S1 was affected in 26 (57.77%), L4-L5 in 13 (28.88%) and multi in 4 (8.88%) and L2-3 in 2 (4.44%) cases. Slip grade was measured with Meyerding grades, 18 (40%) patients had grade II, 15 (33.33%) had I, 9 (20%) had III and 3 (6.66%) had IV spondylolisthesis.

Posterior approach was made in 43 (95.55%) and anterior in 2 (4.44%) patients. Posterior lumbar inter-body (PLIF) fusion was done in 24 (53.33%) patients, posterolateral fusion (PLF) in 5 (11.11%), transforaminal lumbar inter body fusion (TLIF) in 4 (8.88%), translaminar (TLFS) screw in 3 (6.6%), transpedicular transdiscal transcorporeal (TPTDTC) screw in 3 (6.66%), Delta fixation in 1 (2.22%) and ALIF was done in 2 (4.44%) cases. Pedicle screw fixation (PSF) was done in 32 (71%) cases, AO fixator internaee in 6 (13.33%) and 4.5 mm titanium screw were used in others. The patients were allowed to sit on first postoperative day. They were gradually allowed to mobilise depending upon their neurological status.

Average follow up was 2 years and 5 months, max 5 years and minimum 6 months. Pain relief was achieved in 82% of patients, 29 (64.44%) patient had no pain, 8 (17.77%) had mild, 5 (11.11%) moderate and 3 (6.66%) had severe pain (Table-2). Neurological improvement was noticed in 60% in 11 (24.44%) of patients with deficit (Table-3). We achieved union in 41 (91.11%) cases. We did not have any deterioration of neurological status. We had 2 (4.44%) implant failure and 1 (2.22%) wound infection.

**Table-1: Age distribution of the patients**

Age (Years)	Decade	No. of patients
11-20	2 <sup>nd</sup>	1
21-30	3 <sup>rd</sup>	5
31-40	4 <sup>th</sup>	16
41-50	5 <sup>th</sup>	11
51-60	6 <sup>th</sup>	9
61-70	7 <sup>th</sup>	2
71-80	8 <sup>th</sup>	1

**Table-2: Pain relief (Graphic Rating Scale)**

Pain (GRS)	Preoperative	Postoperative
No pain	0	29
Mild	0	3
Moderate	6	5
Severe	33	8
Excruciating	6	0

**Table-3: Neurological Improvement**

AIS-Score	Preoperative	Postoperative
AIS-C	2	1
AIS-D	9	4
AIS-E	34	40

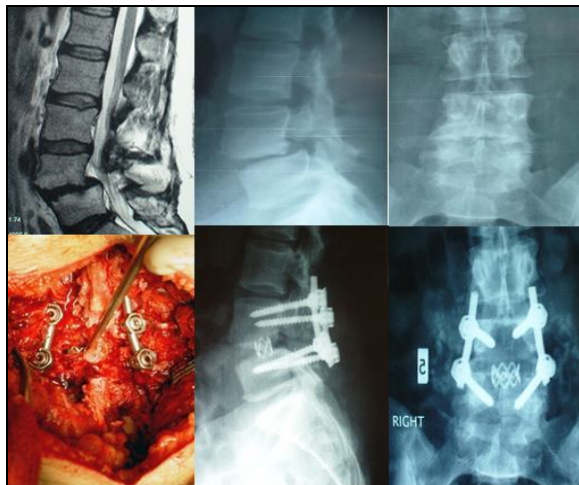
## DISCUSSION

The clinical outcome in spondylolisthesis is closely related to the attainment of solid fusion.<sup>22</sup> Compared with patients who are treated non-operatively, patients in whom degenerative spondylolisthesis and associated

spinal stenosis are treated surgically maintain substantially greater pain relief and improvement in function for longer period.<sup>23</sup> We achieved fusion in 41 (91.11%) patients. Although there are several surgical options, the decision to proceed with decompression and fusion depends on the patient's presenting symptoms and degree of instability. Symptomatic patients often present with severe pain, neurologic deficits, or deformity. We achieved significant pain relief in 82% patients.

The lesion in spondylolysis is a non-union that follows a fatigue fracture of pars interarticularis. Direct repair of the pars defect is a logical alternative to fusion as it helps to preserve the motion segment and prevents abnormal stresses at the adjacent levels. Buck's fusion can be done in spondylolysis with or without grade 1 spondylolisthesis.<sup>24</sup>

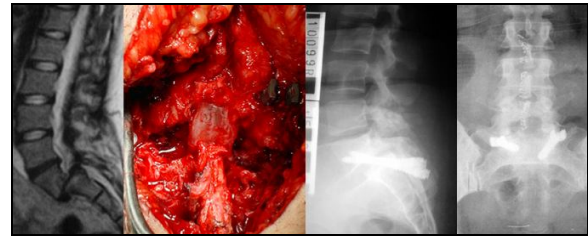
Posterolateral pedicle screw-rod fixation has improved rates of arthrodesis compared with traditional in situ fusions.<sup>25</sup> There is some reduction with pedicle screw and circumferential fusion at L5-S1, achieved entirely through a posterior approach or through separate anterior and posterior approaches.<sup>3</sup> PLIF provides spondylosis with decompression of the canal and 360 degree fusion with single posterior approach. We did PLIF in 24 (53.33%) patients and attained some reduction during posterior only 360 degree fusion (Figure-1). Dynamic stabilisation is another method of treatment in low grade slips by intraspinal and pedicle screw-based devices. Evidence to date indicates that Grade II or larger slips requiring decompression should be fused.<sup>26</sup>



**Figure-1: PLIF with reduction**

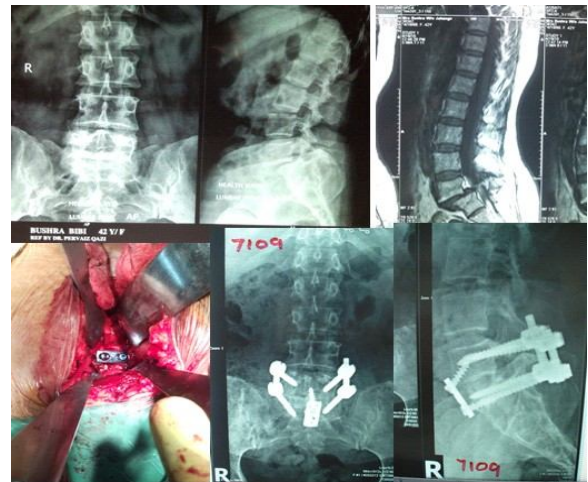High grade spondylolisthesis can be fused with or without reduction of the spondylolisthesis, during reduction the exiting nerve root is at danger. High grade slips can be treated with fusion without reduction of the spondylolisthesis, by two cancellous bone screws inserted bilaterally through the pedicles of the lower

vertebra into the body of the upper slipped vertebra.<sup>17,27</sup> We did spondylosis with TPTDTC screw fixation in 3 patients with high grade slips (Figure-2) and Delta fixation in 1.



**Figure-2: TPTDTC Fixation**

The surgical management of high-grade spondylolisthesis in adults remains challenging and controversial. PLIF provides good fusion rate with some reduction but cage migrations and lower fusion rates as compared to ALIF are documented.<sup>28</sup> Modern-day treatment of high-grade spondylolisthesis usually involves some reduction of the spondylolisthesis along with pedicle screw instrumentation and circumferential fusion at L5-S1, achieved entirely through a posterior approach or through separate anterior and posterior approaches.<sup>3</sup> We did ALIF with combined posterior fusion in 1 case (Figure-3). The fibular strut grafts can also be placed through an anterior approach as part of an anterior/posterior procedure, or via a posterior approach as part of a posterior-only procedure.



**Figure-3: ALIF with combined posterior Fixation**

## CONCLUSION

Surgical procedure for Spondylolisthesis must be individualised. Young patients with spondylolysis can be treated with osteosynthesis and sparing of motion segment. Fusion is must in symptomatic cases but reduction is controversial. We did not aim for reduction by using reduction devices but PLIF provides satisfactory results in majority of low to moderate cases with some correction. TPTDTC and delta fixation is

good procedure for severe slips in adult but exiting nerve root must be identified to avoid injury.

## REFERENCES

1. Wiltse LL, Newman PH, Macnab I. Classification of spondylolysis and spondylolisthesis. *Clin Orthop Relat Res* 1976;(117):23–9.
2. Meyerding HW. Spondylolisthesis. *Surg Gynecol Obstet* 1932;54:371–80.
3. Bridwell KH. Surgical treatment of high-grade spondylolisthesis. *Neurosurg Clin N Am* 2006;17(3):331–8.
4. Jackson RP, Phipps T, Hales C, Surber J. Pelvic lordosis and alignment in spondylolisthesis. *Spine (Phila Pa 1976)* 2003;28(2):151–60.
5. Rowe GG, Roche MB. The etiology of separate neural arch. *J Bone Joint Surg Am* 1953;35:102–10.
6. Syrmou E, Tsitsopoulos PP, Marinopoulos D, Tsonidis C, Anagnostopoulos I, Tsitsopoulos PD. Spondylolysis: a review and reappraisal. *Hippokratia* 2010;14(1):17–21.
7. Labelle H, Mac-Thiong JM, Roussouly P. Spino-pelvic sagittal balance of spondylolisthesis: a review and classification. *Eur Spine J* 2011;5:641–6.
8. Huang KY, Lin RM, Lee YL, Li JD. Factors affecting disability and physical function in degenerative lumbar spondylolisthesis of L4–5: evaluation with axially loaded MRI. *Eur Spine J* 2009;18(12):1851–7.
9. Huang KY, Lin RM, Lee YL, Li JD. Factors affecting disability and physical function in degenerative lumbar spondylolisthesis of L4–5: evaluation with axially loaded MRI. *Eur Spine J* 2009;18(12):1851–7.
10. Pearson AM, Lurie JD, Blood EA, Frymoyer JW, Braeutigam H, An H, *et al.* Spine patient outcomes research trial: radiographic predictors of clinical outcomes after operative or nonoperative treatment of degenerative spondylolisthesis. *Spine (Phila Pa 1976)* 2008;33(25):2759–66.
11. Rajasekaran S, Subbiah M, Shetty AP. Direct repair of lumbar spondylolysis by Buck's technique. *Indian J Orthop* 2011;45(2):136–40.
12. Debusscher F, Troussel S. Direct repair of defects in lumbar spondylolysis with a new pedicle screw hook fixation: clinical, functional and Ct-assessed study. *Eur Spine J* 2007;16(10):1650–8.
13. Kotil K, Akcetin M, Tari R, Ton T, Bilge T. Replacement of vertebral lamina (laminoplasty) in surgery for lumbar isthmic spondylolisthesis. A prospective clinical study. *Turk Neurosurg* 2009;19(2):113–20.
14. Kim DH, Jeong ST, Lee SS. Posterior lumbar interbody fusion using a unilateral single cage and a local morselized bone graft in the degenerative lumbar spine. *Clin Orthop Surg* 2009;1(4):214–21.
15. Hioki A, Miyamoto K, Hosoe H, Sugiyama S, Suzuki N, Shimizu K. Cantilever transforaminal lumbar interbody fusion for upper lumbar degenerative diseases (minimum 2 years follow up). *Yonsei Med J* 2011;52(2):314–21.
16. Lee DY, Lee SH, Maeng DH. Two-level anterior lumbar interbody fusion with percutaneous pedicle screw fixation: a minimum 3-year follow-up study. *Neurol Med Chir (Tokyo)* 2010;50(8):645–50.
17. Zagra A, Giudici F, Minoia L, Corriero AS, Zagra L. Long-term results of pediculo-body fixation and posterolateral fusion for lumbar spondylolisthesis. *Eur Spine J* 2009;18:151–5.
18. Aunoble S, Hoste D, Donkersloot P, Liquois F, Basso Y, Le Huec JC. Video-assisted ALIF with cage and anterior plate fixation for L5–S1 spondylolisthesis. *J Spinal Disord Tech* 2006;19:471–6.
19. Yu CH, Wang CT, Chen PQ. Instrumented posterior lumbar interbody fusion in adult spondylolisthesis. *Clin Orthop Relat Res* 2008;466:3034–43.
20. Heft MV, Parker SR. An experimental basis for revising the graphic rating scale for pain. *Pain* 1984;19(2):153–61.
21. Marino RJ, Barros T, Biering-Sorensen F, Burns SP, Donovan WH, Graves DE, *et al.* International standards for neurological classification of spinal cord injury. *J Spinal Cord Med* 2003;26:S50–S56.
22. Girardo M, Bettini N, Dema E, Cervellati S. Uninstrumented posterolateral spinal arthrodesis: is it the gold standard technique for I degrees and II degrees grade spondylolisthesis in adolescence? *Eur Spine J* 2009;18:126–32.
23. Weinstein JN, Lurie JD, Tosteson TD, Zhao W, Blood EA, Tosteson AN, *et al.* Surgical compared with nonoperative treatment for lumbar degenerative spondylolisthesis. four-year results in the Spine Patient Outcomes Research Trial (SPORT) randomized and observational cohorts. *J Bone Joint Surg Am* 2009;91:1295–304.
24. Rajasekaran S, Subbiah M, Shetty AP. Direct repair of lumbar spondylolysis by Buck's technique. *Indian J Orthop* 2011;45(2):136–40.
25. Acosta FL, Jr., Ames CP, Chou D. Operative management of adult high-grade lumbosacral spondylolisthesis. *Neurosurg Clin N Am* 2007;18(2):249–54.
26. Lawhorne TW, III, Girardi FP, Mina CA, Pappou I, Cammisa FP, Jr. Treatment of degenerative spondylolisthesis: potential impact of dynamic stabilization based on imaging analysis. *Eur Spine J* 2009;18:815–22.
27. Zagra A, Giudici F, Minoia L, Corriero AS, Zagra L. Long-term results of pediculo-body fixation and posterolateral fusion for lumbar spondylolisthesis. *Eur Spine J* 2009;18:151–5.
28. Abbushi A, Cabraja M, Thomale UW, Woiciechowsky C, Kroppenstedt SN. The influence of cage positioning and cage type on cage migration and fusion rates in patients with monosegmental posterior lumbar interbody fusion and posterior fixation. *Eur Spine J* 2009;18:1621–8.

## Address for Correspondence:

**Dr. Ibrahim Farooq Pasha**, Department of Orthopaedic Surgery, Combined Military Hospital, Peshawar, Pakistan.

**Cell:** +923218122 913

**Email:** ifpasha@hotmail.com