

CASE REPORT

LAPAROSCOPIC APPROACH TO A RARE INTERSTITIAL INCISIONAL HERNIA FOLLOWING APPENDECTOMY

Kerim Erdem Ulucay, Muhammad Umar Younis

Department of General Surgery, Canadian Specialist Hospital Dubai-UAE

Among the complications of an open appendectomy is the presentation of an incisional hernia. An interstitial or interparietal hernia is the one in which the hernia sac is present between the muscle layers of the abdominal wall which makes the presentation of a post-operative incisional interstitial hernia quite a rarity. A 52-year-old female was admitted through the outpatient clinic presenting with the complaints of discomfort and a bulge felt in the right hypochondrium for the last 3 years. Radiological investigations were able to delineate an interstitial incisional hernia through the previous open appendectomy scar. A laparoscopic approach to repair of this hernia was successfully undertaken without any complications. This is an interesting case of incisional hernia that may pose a diagnostic challenge to the unsuspecting surgeon with an unusual presentation which may cause unnecessary delays in treatment as well as unnecessary operations. Very few comparable cases can be found in literature.

Keywords: Interstitial hernia; Open appendectomy; Incisional hernia; Laparoscopy

J Ayub Med Coll Abbottabad 2017;29(2):344–6

INTRODUCTION

Acute Appendicitis is a very common presentation in the surgical emergency that's why it is one of the most frequent procedures to be carried out by a general surgeon. Among the complications associated with the operation, the occurrence of incisional hernia is quite unusual with rates of less than 0.12% of patients.¹ An interstitial or inter parietal hernia is the one in which the hernia sac is present between the muscle layers of the abdominal wall which makes the presentation of a post-operative incisional interstitial hernia quite a rarity.² We present here a case of post appendectomy incisional interstitial hernia successfully repaired with laparoscopy.

CASE REPORT

A 52-year-old female presented to the outpatient clinic with complaints of discomfort and bulge in the right upper quadrant of the abdomen for 3 years' duration. Her past surgical history included an open appendectomy via McBurney incision 15 years back. The bulge was not visible and careful abdominal palpation was able to discern its presence in deeper layers. No associated symptoms pertaining to the gastrointestinal system were described by the patient. Examination revealed a well healed open appendectomy scar and the bulge felt as firm, non-tender 3x2cm² lump in the right upper abdomen with no relation to coughing or straining and normal overlying and surrounding skin. The lump had an irregular surface with ill-defined margins. The tone of the abdominal wall musculature was felt to be normal. She did not reveal any chronic medical condition or medication use while history was being taken.

Her routine labs including Complete Blood Count, Coagulation screen and Virology were sent and all found to be normal. Abdominopelvic Ultrasound was requested which described a breach in the continuity of right lower abdominal scar and protrusion of peritoneal fat within the scar measuring 14x13 mm. This further was probed by CT scan abdomen with contrast which confirmed the presence of the incisional defect which was seen communicating with a fat containing hernia sac under cover of external oblique aponeurosis. A diagnosis of post appendectomy incisional interstitial hernia was made and the patient scheduled for laparoscopic repair of the hernia.

Three ports were utilized during the surgery. Veress needle CO₂ insufflation was carried out using Palmer point as the point of access in the left Upper Quadrant of Abdomen maintaining pressure at 14 mmHg. Entry into the abdomen was gained under direct vision with the help of Visiport in the left anterior axillary line which was used as camera port and two 5mm ports were inserted with an acceptable distance on the same side of abdomen as working ports. A 4x2 cm fascial defect was noted in the appendectomy scar through which omentum was extruding out. Dissection was started by performing adhesiolysis using endoscissors with cautery attached. The hernia contents were then gradually pulled down into the abdomen with one assistant pushing and milking the sac from the outer abdominal wall towards the defect from the upper abdomen. With the sac completely reduced and pulled into the abdominal cavity, the contents were analysed. The size of the defect was then ascertained and a 10x12 cm composite mesh was placed to achieve a complete overlap of 4–5 cm around all fascial edges of the defect. Vicryl 3/0 was utilized with the help of endoclosure device to secure

the first stitch to the defect and the rest of the mesh was tacked securely in place using Ethicon Secure strap absorbable fixation device. Her postoperative recovery period went uneventful and was discharged on oral medication on the 3rd day after achieving good pain control. Her follow up visit was arranged after a week with no complaints.

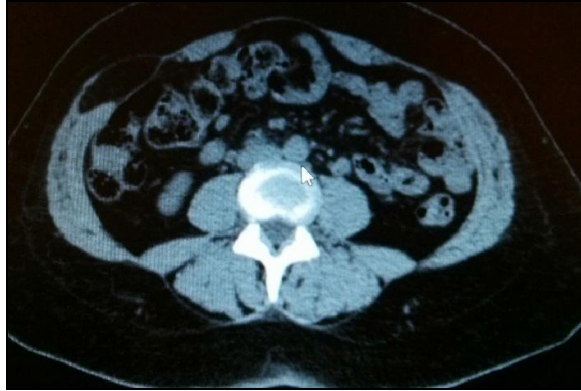

Figure-1: Coronal CT scan abdomen

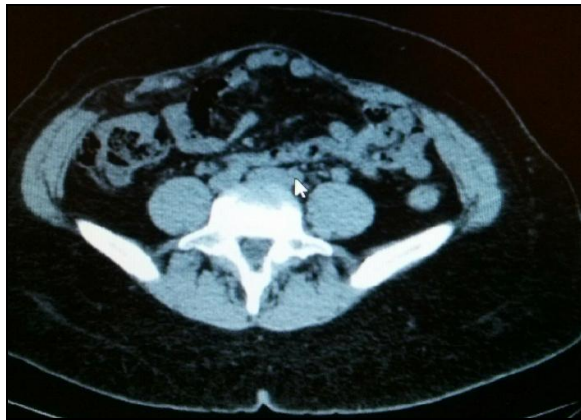

Figure-2: Coronal CT showing defect

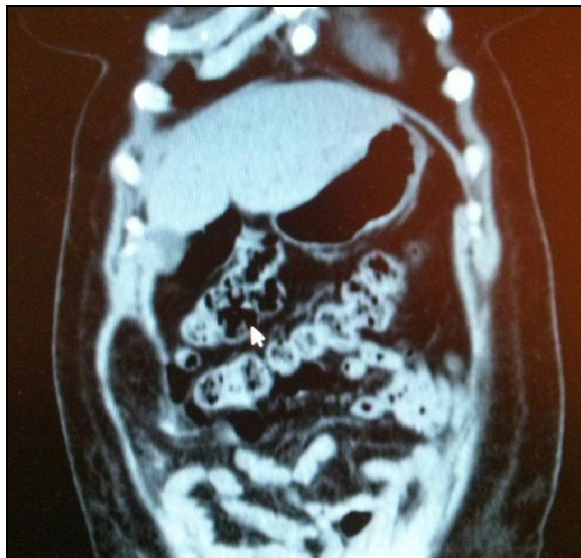

Figure-3: Sagittal CT slice depicting hernia sac

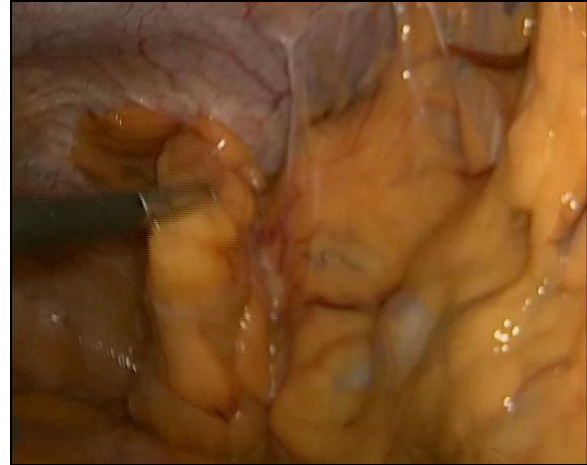


Figure-4: Intra-op view of sac being reduced

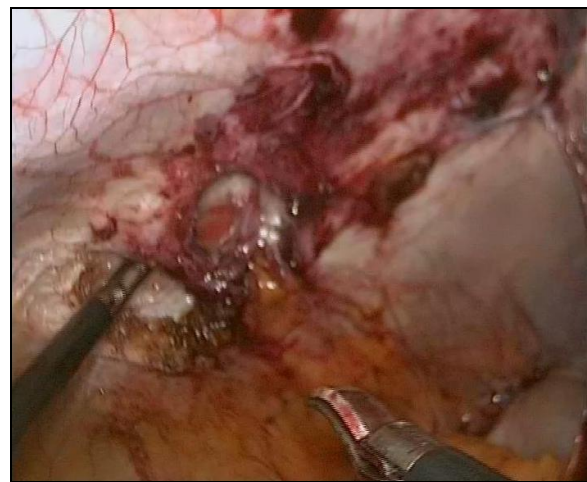


Figure-5: Hernial defect

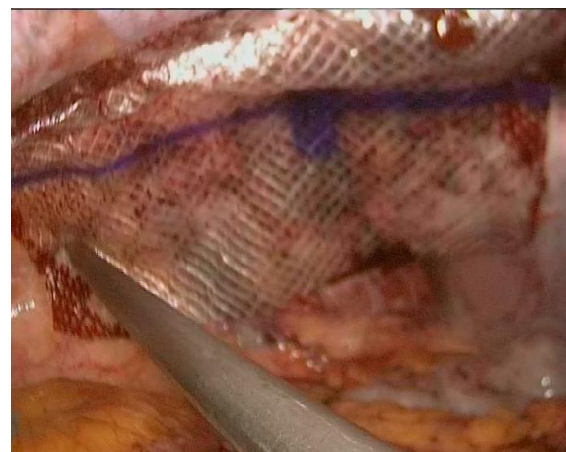

Figure-6: Placement of composite mesh over defect

DISCUSSION

An incisional hernia remains an important complication of surgery even though significant advances have been made in surgical technique and materials used.³ Literature describes most of the

abdominal wall defects to appear at the surgical incision site within 5 years of surgery but can develop later as well.⁴ Factors predisposing an individual to the development of an incisional hernia include weak abdominal wall musculature in old age patients, diabetics, smokers and those using steroids for other medical conditions. Factors pertaining to surgical causes include emergency surgery, bowel surgery, poor choice of suture, poor technique and wound infection.⁵

During open appendectomy using a grid iron or McBurney incision, encountering a complicated appendix infection like an abscess, mass, perforation or localized purulent peritonitis increases the chances of developing a post-operative incisional hernia.⁶ Other causes that can lead to this type of hernia also include passing a drain through the incision site and poor surgical technique of wound closure that may entail weakness in the incision and be a factor in poor wound healing. More commonly an incisional hernia presents as an abdominal lump traversing through all the layers of the wall musculature. Infrequently, as we encountered in our described case, it may manifest as a vague swelling that passes through the transversus abdominis and internal oblique layers but has an intact external oblique aponeurosis over it.² This type of obscure hernia poses a diagnostic dilemma for the surgeon and requires imaging investigations in the form of Ultrasonography and CT Scan Abdomen, as were carried out in our patient, to completely delineate the extents of the defect and determining its contents.

Once diagnosed, surgical repair is usually described in literature in the form of open repair with mesh placement in the preperitoneal space as an on lay mesh with sufficient overlap of 6–8 cm around the edges.⁷ We have delineated a laparoscopic approach to manage such a hernia using three ports with intra-abdominal placement of a composite mesh covering the defect and have shown it as a satisfactory technique in management of such cases.

CONCLUSION

This is an interesting case of incisional hernia that may pose a diagnostic challenge to the unsuspecting surgeon with an unusual presentation which may cause unnecessary delays in treatment as well as unnecessary operations. Very few comparable cases can be found in literature.

AUTHORS CONTRIBUTION

KEU was the operating specialist surgeon, MUY wrote the manuscript and served as surgical assistant along with reviewing the manuscript for critical content. All the authors read and approved the final manuscript.

Competing interests: The authors declare that they have no competing interests.

Funding/support: There was no financial support from any organization.

REFERENCES

1. Kostantakos AK, Zollinger RM Jr. Repair of McBurney incisional hernia after open appendectomy. *Current Surg* 2000;57(1):79–80.
2. Abrahamson J. Hernias. In: Zinner MJ, Schwartz SI, Ellis H, editors. *Maingot's Abdominal Operations*. 10th ed. Connecticut: Appleton & Lange 1997. p.479–580.
3. Feliciano DV. Incisional hernias as emergencies. In: Bendavid R, Abrahamson J, Arregui M, Flament JB, Phillips ED, editors. *Emergency surgery. Abdominal wall hernias*. New York: Springer-Verlag Inc 2001. p.582–7.
4. Chowbey PK, Sharma A, Mehrotra M, Khullar R, Soni V, Bajjal M. Laparoscopic repair of ventral/incisional hernias. *J Min Access Surg* 2006;2(3):192–8.
5. Kumar SL, Saidha N, Ramakrishnan TS, Sahu S. Interstitial Incisional Hernia following Appendectomy. *Med J Armed Forces India* 2009;65(2):176–7.
6. Abou-Nukta F, Bakhos C, Arroyo K, Koo Y, Martin J, Reinhold R, *et al*. Effects of delaying appendectomy for acute appendicitis for 12 to 24 hours. *Arch Surg* 2006;141(5):504–6.
7. Duce AM, Lozano O, Villeta R, Muguerza JM, Martín J, Díez M, *et al*. Incisional hernia following appendectomy. Surgical experience. *Hernia* 1998;2(4):169–71.

Received: 22 August 2016

Revised: 5 September, 2016

Accepted: 23 September, 2016

Address for Correspondence:

Muhammad Umar Younis, Department of General Surgery, Canadian Specialist Hospital Dubai-UAE

Email: umar000@hotmail.com