

ORIGINAL ARTICLE

RAISED INTRAOCULAR PRESSURE AND RECURRENCE OF RETINAL DETACHMENT AS COMPLICATIONS OF EXTERNAL RETINAL DETACHMENT SURGERY

Muhammad Jawwad, Bilal Khan, Mir Ali Shah, Iftikhar Qayyum*, Mohammad Aftab**

Department of Ophthalmology, Lady Reading Hospital, Peshawar, *Department of Medical Research Rehman Medical Institute, Peshawar, **Department of Ophthalmology, Women Medical College, Abbottabad-Pakistan

Background: Patients with Rhegmatogenous retinal detachment may develop raised intraocular pressure and recurrence of retinal detachment when they undergo external retinal detachment surgery. The present study was conducted to determine the postoperative rise in intraocular pressure (IOP) and recurrence of retinal detachment. **Methods:** The present descriptive study was conducted at Eye department of Lady Reading Hospital, Peshawar on 25 patients of both genders from August 2012 to July 2014. **Results:** Of the 25 patients, 18 (72%) developed raised IOP in the immediate postoperative period; this figure decreased to 12 (48%) at one week. Following medical or surgical intervention in these 12 cases, there was only 1 (4%) case with mildly raised IOP at two weeks postoperative. Five (20%) cases developed recurrent retinal detachment which later resolved with treatment. There were no significant differences by age or gender. **Conclusion:** External Retinal Detachment Surgery raised intraocular pressure postoperatively and caused recurrence of retinal detachment. These complications were treated medically and surgically with resolution within two weeks.

Keywords: Retinal detachment, Retinal surgery, intraocular pressure

J Ayub Med Coll Abbottabad 2015;27(4):798-800

INTRODUCTION

Rhegmatogenous retinal detachment (RRD) is separation of sensory retina from retinal pigment epithelium (RPE). RRD is caused by a retinal break in the periphery and vitreoretinal traction, which allows the access of vitreous fluid to the subretinal space. Treatment of symptomatic retinal detachment is currently surgical only. Surgical options are extra ocular and intraocular.¹

The extraocular surgery is scleral buckle. The principle is to relieve vitreous traction on retinal breaks, alter intraocular fluid currents and reappose retinal/RPE anatomy. Scleral buckling in conjunction with retinal cryopexy is used to create a permanent adhesion at the site of retinal breaks. Scleral buckling techniques are of three types i.e. encircling, segmental and radial. External drainage of subretinal fluid and intraocular gas tamponade may be indicated if intraocular pressure increases due to displaced volume from buckling effect, chronic viscous subretinal fluid, fish mouting of large retinal breaks and bullous retinal detachments.²

Postoperative complications of external scleral buckle are secondary glaucoma and retinal redetachment.³ A high proportion of patients with successful retinal reattachment surgery had foveal detachment postoperatively.⁴ Other complications are myopia, ocular ischemia, diplopia, ptosis, orbital cellulitis, subretinal haemorrhage from drainage and retinal incarceration at drainage site, epiretinal membrane formation, extrusion of the buckle and

band migration.²⁻⁵

The main objective of this study is to evaluate the effect of surgery on IOP changes and to see the recurrence of retinal detachment after conventional retinal detachment surgery.

MATERIAL AND METHODS

This descriptive case series was conducted at the Department of Ophthalmology in Lady Reading Hospital, Peshawar, Pakistan, from August 2012 to July 2014, on patients who were operated for Rhegmatogenous retinal detachment. All patients from second decade to seventh decade were studied. The patients complained of decrease in vision and painful eyes. The IOP was confirmed by air puff tonometer. These patients were operated for Rhegmatogenous retinal detachment. The procedure consisted of conventional surgical treatment of retinal detachment by using external implants, i.e., application of encircling band. The intraocular pressure was recorded for one month after surgery. Exclusion criteria were: Preoperative diagnosis of glaucoma or ocular hypertension (OHT); Diabetes with or without diabetic retinopathy and a history of vitrectomy; Penetrating ocular trauma; Ocular inflammation; Ocular ischemia; and therapy with a long-term topical steroid medication. The twenty-five patients were selected by convenience sampling.

First of all the cases were identified after detailed history and ocular examination including visual acuity on Snellen's chart, slit lamp

examination, intraocular pressure, measurement with Air puff tonometer and fundus examination with indirect ophthalmoscope using 20 D lenses and with slit lamp using 78 D and 90 D Lenses.

After admission, investigations like Haemoglobin (Hb), Hepatitis B Antigen (HbsAg) and Hepatitis C Antibody (HCV Ab), Fasting and Random Blood glucose and Blood Pressure were measured. All the patients underwent external scleral buckle surgery. Peribulbar anaesthesia was given. The conjunctiva peritomy was done. Recti muscles were exposed and they were slung with 2/0 black silk. Examination under anesthesia and break localization was done with the help of indirect ophthalmoscope and 20D lens. The sub retinal fluid was drained. Cryotherapy was applied at the site of drainage. Retinopexy that is injection of air was done. Encircling band was passed under the muscle and stitched to the sclera. Tyre was applied beneath the encircling band, where needed. Conjunctiva was stitched. The patients were then prescribed topical steroids and antibiotic eye drops, artificial tear substitute and cycloplegic eye drops to reduce inflammation. The recurrence of retinal detachment and IOP was measured on 1st post op day, then 1st and 2nd weeks. The three IOP values were averaged and analysed. Raised IOP was defined as value greater than IOP in the normal range of 11–21 mmHg. The IOP readings at first week were taken as indication for further medical and surgical intervention, so that patients with pressures between 21–29 mmHg were given medical treatment for glaucoma, while those having pressures of 30 mmHg and above were subjected to band manipulation surgery. After one week of intervention, the final IOP readings were taken (2nd week IOP readings).

The data were entered in SPSS version 15.0 for analysis. Analysis included demographic data, data of IOP at various readings and data of postoperative complications. Variables were analysed for frequencies and related measures as well as for means and SD. Comparisons were done by gender and by complication groups. Chi-square test was used for comparisons of frequencies while the Independent Samples *t*-test was used for comparing means. A $p \leq 0.05$ denoted significance.

RESULTS

Table-1 shows the baseline data by gender of 25 patients who underwent external scleral buckle surgery for Rhegmatogenous retinal detachment (RRD).

Patients belonged to all adult age groups with no significant differences by gender. The mean ages also were fairly similar with no significant gender differences. Similarly involvement of both eyes was found with no significant differences for eye preference by gender.

Table-2 provides the data for all Intraocular Pressure readings in frequencies and means compared by gender. No significant differences were obtained for any of the variables.

Table-3 gives the data for the two postoperative groups based on complication of retinal detachment.

Table-1: Baseline data of patients (n=25).

Variables	Males	Females	p-value	Total
Genders	14	11	-	25
Age Groups (years)				
≤20	4	1	0.306	5
21–40	5	7		12
41–60	3	2		5
61–80	1	2		3
Mean Ages (years)	35.36±19.82	37.27±17.16	0.802	36.20±18.34
Eyes involved				
Right	8	6	0.897	14
Left	6	5		

Table-2: Intra Ocular Pressures (IOP) of Patients (n=25)

Variables	Males	Females	p-value	Total
Mean Post Op IOP (mmHg)	32.07±16.61	30.0±13.56	0.74	31.16±15.07
Mean First Week IOP (mmHg)	25.57±14.73	23.45±11.02	0.695	24.64±13.01
Mean Second Week IOP (mmHg)	15.29±04.63	15.73±5.00	0.821	15.48±4.70*
Mean IOP (mmHg)				
10–15	2	3	0.188	5
16–20	5	3		8
21–25	1	2		3
26–30	3	1		4
31–35	1	-		1
36–40	-	2		2
41–45	2	-		2
Mean IOP (mmHg)	24.29±11.49	22.73±9.65	0.722	23.60±10.54

* $p < 0.001$ as compared to Postop and week one ($p = 0.028$) mean IOP readings (One way ANOVA).

Table-3: Comparison of data for the postoperative complications groups (n=25)

Variables	Retinal Detachment (n=5)	No Retinal Detachment (n=20)	p value	Total	
Gender					
Males	2	12	0.420	14	
Females	3	8			
Age groups (years)					
≤20	-	5	0.482	5	
21–40	04	8			12
41–60	-	5			5
61–80	01	2			3
Mean Ages (years)					
(years)	43.00±18.57	34.50±18.36	0.365	36.20±18.34	
Males (n=14)	52.50±31.82	32.50±17.60	0.198	35.36±19.82	
Females (n=11)	36.67±05.77	37.50±20.27	0.947	37.27±17.16	
Intra ocular pressure (mmHg)					
10–15	3	2	0.482	5	
16–20	1	7			8
21–25	1	2			3
26–30	-	4			4
31–35	-	1			1
36–40	-	2			2
41–45	-	2			2
Mean IOP (mmHg)					
(mmHg)	16.00±5.61	25.50±10.70	0.070	23.60±10.53	
Males (n=14)	13.50±4.95	26.08±11.36	0.159	24.29±11.49	
Females (n=11)	17.67±6.35	24.63±10.31	0.311	22.73±9.65	

All comparisons yielded non-significant *p* values.

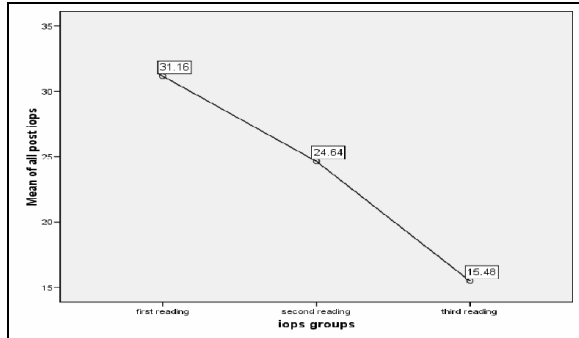


Figure-1: Decreases in mean IOP measured in three readings

DISCUSSION

Of the 25 male and female patients who underwent retinal detachment surgery, 18 (72%) developed raised IOP in the immediate postoperative period. However by the end of the first postoperative week, this number had reduced to 12 (48%) without any intervention. At this stage the option of medical (5 patients) or surgical intervention (7 patients) was offered depending on severity of raised IOP. Readings at the second postoperative week (following the interventions) indicated that only 1 (25%) female patient had mildly raised IOP. The mean IOP readings at week two were significantly decreased from the postoperative readings and the week one readings. In one study, external scleral buckle procedure carried a lower risk (29.5%) of raised IOP requiring intervention;⁵ however risk factors for postoperative elevated IOP were not evaluated in the present study and could account for the difference. A steroid response is the commonest cause of open angle glaucoma after buckling surgery. Most cases of buckle related glaucoma occur without pupil block. The central anterior chamber is shallow due to forward displacement of the ciliary body. This may be due to the combined effects of interrupted choroidal venous drainage and the mass effects of a large explant. This condition does not respond to iridotomy or miosis. Most cases resolve after 1 week with conservative measures including steroids, cycloplegia and ocular hypotensive agents. In intractable cases, the Watzke sleeve may need to be loosened or the band divided.⁷ Redetachment of retina as a postoperative complication was found in 5 (20%) of patients in this study. The recurrence of retinal detachment was due to large number of breaks with more distinct Proliferative vitreoretinopathy (PVR). Retinal detachment is caused by missed breaks.⁸ Localization of retinal tears causing a pseudophakia RD is not always possible. As a result, segmental indentation by external compression cause residual RD. Vitrectomy enables a detailed view of peripheral part of

retina and better detection of small size retinal breaks. PVR was also observed as a cause of RD. Surgical treatment of pseudophakic RD consisting of vitrectomy and scleral buckling showed good anatomic and functional results. It had the advantage of better localization of peripheral retinal tears which resulted in low recurrence rate as compared to external scleral buckle alone.⁹ The retinal redetachment rate was 16.7% with primary PVR rate of 4.2% in one study.¹⁰ In another study, 19% patients developed PVR causing redetachment after external surgery.¹¹ Retinal redetachment may occur because of reopening of a retinal break. Other causes of failure are buckle failure such as buckle of inadequate size, incorrectly positioned buckle and if they are of inadequate height.⁸

CONCLUSION

External scleral buckle surgery for Retinal Detachment is successful in repairing the defect; however postoperative raised IOP is a complication in about half of the cases, which can be relieved by suitable medical or surgical intervention within two weeks postoperatively.

AUTHOR'S CONTRIBUTION

MJ, conceived the idea, data collection, write-up, MAS, IQ: write-up and data analysis, MF: proof reading.

REFERENCES

1. Hejssek L, Dusová J, Stepanov A, Rozsival P. Scleral buckling for Rhegmatogenous retinal detachment. *Cesk Slov Oftalmol* 2014;70(3):110-3.
2. American Academy of Ophthalmology. Vitreoretinal surgery. In: *Retina and Vitreous. Basic and Clinical Science Course*. San Francisco: American Academy of Ophthalmology 2007-2008:323-42.
3. Hang Y, Hu P, Shun L, Zhu X, Yi Y, Liu W. External approach microsurgery of retinal dialysis. *Yan Ke Xue Bao* 2005;21(1):12-4.s
4. Gibran SK, Alwitry A, Cleary PE. Foveal detachment after successful retinal reattachment for macula on rhegmatogeneous retinal detachment: an ocular coherence tomography evaluation. *Eye (Lond)* 2006;20(11):1284-7.
5. Muether PS, Hoerster R, Kirchhof B, Fauser S. Course of intraocular pressure after vitreoretinal surgery: is early postoperative intraocular pressure elevation predictable? *Retina* 2011;31(8):1545-52.
6. Ryan SJ. Retina. *Techniques of Scleral Buckling*. In: Wilkinson CP, Wiedemann P, Schachat AP. *Surgical Retina*. 5th Edition. London: Elsevier Saunders. 2013:1669-95.
7. Golubovic M. Rhegmatogenous retinal detachment and conventional surgical treatment. *Prilozi* 2013;34(1):161-6.
8. Kanski JJ. Retinal Detachment. In: *Clinical Ophthalmology*. 7th ed. London: Elsevier. 2011:687-733.
9. Poumaras CJ, Donati G, Sekkat L, Kapetanios AD. Pseudophakic retinal detachment: treatment by vitrectomy and scleral buckling. Pilot study. *J Fr Ophtalmol* 2000;23(10):1006-11.
10. Framme C, Roider J, Hoerauf H, Laqua H. Complications after external retinal surgery in pseudophakic retinal detachment - are scleral buckling operations still current? *Klin Monbl Augenheilkd* 2000;216(1):25-32.
11. Azad RV, Talwar D, Pai A. Modified needle drainage of subretinal fluid for conventional scleral buckling procedures. *Ophthalmic Surg Lasers* 1997;28(2):165-7.

Address for Correspondence:

Muhammad Jawwad, Eye Department Lady Reading Hospital, Peshawar-Pakistan
Cell: +92 321 968 6924, **Email:** drmjawad_582@hotmail.com