

## CASE REPORT

## GIANT CEMENTOBLASTOMA OF LEFT MAXILLA INVOLVING A DECIDUOUS MOLAR

Anam Javed, Syed Majid Hussain Shah

Department of Oral and Maxillofacial Surgery, Ayub Teaching Hospital Abbottabad-Pakistan

Cementoblastoma is a relatively rare benign tumour. The clinicopathologic features, radiological findings, treatment and prognosis are reported here in a 10-year-old girl who presented to us from Afghanistan. The tumor was managed surgically and the histopathology confirmed the diagnosis of cementoblastoma. There was no evidence of recurrence at one year of follow up.

**Keywords:** Cementoblastoma; Odontogenic tumour; Deciduous molar

J Ayub Med Coll Abbottabad 2017;29(1):145-6

## INTRODUCTION

The WHO has classified cementoblastoma as a benign, rare and the only true neoplasm arising from cementum.<sup>1</sup> It arises from a hamartomatous proliferation of cementoblasts in a disorganized manner around the apical third of a tooth root.<sup>2</sup> Permanent dentition is mostly involved with few reported incidences of the primary teeth. Most of the cases occur in the mandibular molar region with 50% involving mandibular first molars.<sup>3</sup> Symptoms may range from none to deep dull pain and swelling of the involved region.<sup>4</sup> We report a case of a symptomatic, giant, cementoblastoma associated with maxillary left deciduous second molar involving multiple teeth from 22-27 in a 10-year-old female patient.

## CASE

A 10-year-old girl from Afghanistan presented to Oral and Maxillofacial Surgery Department of Ayub Teaching Hospital Abbottabad, with chief complaint of swelling and pain in her left upper jaw for the last 4 months. The onset of swelling was gradual while pain accompanied it for the last 1 month. On extraoral examination, there was swelling of the left cheek causing gross facial asymmetry and obliteration of nasolabial fold (Figure-1a). Overlying skin was mobile and slightly tender. Intraoral examination revealed swelling that extended from 23 to 27 and from midpalatal region to the buccal vestibule forming a huge bulge (Figure-1b). Deciduous canine, first and second molars were also present with gross displacement and mobility. On palpation, the swelling blanched and was slightly compressible, rubbery to firm in consistency.

OPG and CT-scan showed a mixed radiolucent/radio-opaque lesion of ground glass appearance extending from 22 to the distal root of 26 including unerupted 23, 24, 25, 27. There was a circumscribed radio-opacity around the root of maxillary left deciduous second molar (Figure-2, 3). Incisional biopsy was performed which gave a diagnosis of cementoblastoma with histological findings of abundant cementum, islands of polyhedral epithelial cells and fibrous stroma. Excision of the tumour was planned under general anaesthesia, with sub-marginal incision of the left maxillary vestibule flap was raised both buccally and palatally, tumour enucleated (measured 6.5×4.5×3.5 cm) along with 22, 2C, 2D, 2E, 26

(Figure-4). Peripheral ostectomy was done along with chemical cauterization with carnoye's solution. Primary closure was achieved after packing the surgical site with white head's varnish for 3 days. Patient did well postoperatively with no complications and is still on follow-up with no evidence of recurrence.

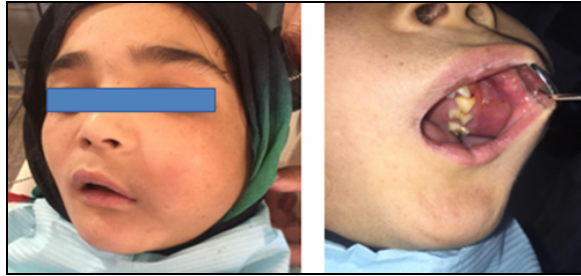
## DISCUSSION

Cementoblastoma is found predominantly in younger individuals in second or third decade of life, almost half of them being encountered under the age of 20 year.<sup>5-7</sup> It was first described by Norberg in 1930 and according to some by Dewey<sup>8</sup> and is a rare tumour with less than 100 cases ever reported in literature<sup>9-13</sup>.

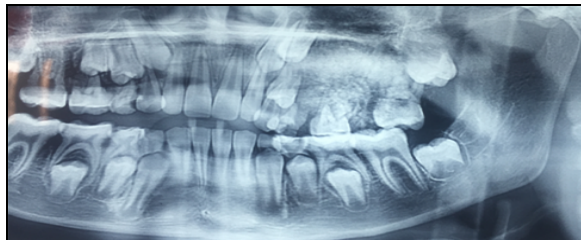
Cementoblastomas are usually slow growing and asymptomatic tumors, excluding the one reported here being the symptomatic one, but they are capable of an unlimited growth potential.<sup>14</sup> They affect both sexes equally and are always found in association with the roots of affected teeth.<sup>5,7,16,17</sup> Over 90% cases occurring in both jaws involve the premolar and molar region, but there can be involvement of the deciduous teeth, impacted molars and multiple teeth as well.<sup>18,19</sup>

In asymptomatic cases cementoblastoma is a chance radiographic finding,<sup>8,20</sup> presentation dependant on the stage of its maturation. Mature lesions are well-circumscribed radio-opaque masses continuous with tooth's root with resultant loss of the root contour, while the immature ones are radiolucent on radiographs.<sup>21</sup> Histologically, the neoplasm is formed by sheets of cementum like tissue with large number of reversal lines, active cementoblasts, lack of mineralization at the periphery and a band of fibrous connective tissue like a capsule may also be apparent.<sup>3,10,22</sup> It seems continuous with the cemental layer of the apical 1/3<sup>rd</sup> of involved root and through continuation of periodontal ligament it remains demarcated from the adjacent bone, hence supporting its odontogenic origin.<sup>21</sup> Treatment involves removal of the tumour along with extraction of involved tooth/teeth<sup>23</sup> followed by thorough curettage and peripheral ostectomy.<sup>6</sup> Endodontic treatment of the involved tooth with apicectomy and enucleation of tumour has also been reported with no recurrence in a 4-

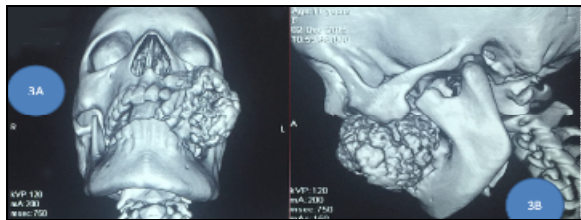
year follow-up period.<sup>24</sup> Prognosis is excellent after complete surgical excision of the tumour.<sup>9</sup>



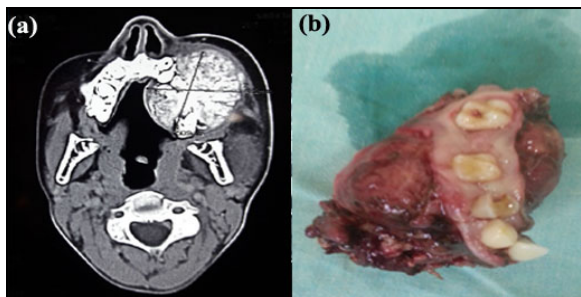
**Figure-1: Clinical photographs showing involvement of palate & buccal vestibule with gross facial disfigurement**



**Figure-2: OPG showing circumscribed radio-opacity around deciduous**



**Figure-3: 3D CT scan showing involvement of the left maxilla**



**Figure-4: Enucleated tumour**

## CONCLUSION

This is a unique case of cementoblastoma in association with a maxillary deciduous molar along with involvement of multiple teeth as it was giant in size with palatal and buccal vestibular involvement. It is important not to leave such lesions undiagnosed and

untreated as they may continue to grow and may cause severe destruction of the involved region.

## REFERENCES

1. Kramer IRH, Pindborg JJ, Shear M, Pindborg JJ. Histological typing of odontogenic tumours. 2nd ed. Berlin; New York: Springer-Verlag; 1992. p.23-40.
2. Dewey KW. Osteoma of a molar. Dent Cosm 1927;69:1143-9.
3. Schafer TE, Singh B, Myers DR. Cementoblastoma associated with a primary tooth: A rare pediatric lesion. Pediatr Dent 2001;23(4):351-3.
4. Ulmanky M, Hjorting-Hansen E, Praetorius F, Hacque MF. Benign cementoblastoma: a review and five new cases. Oral Surg Oral Med Oral Pathol 1994;77(1):48-55.
5. Ackermann GL, Altini M. The cementomas-clinicopathological appraisal. J Dent Assoc S Afr 1992;47(5):187-94.
6. Brannon RB, Fowler CB, Carpenter WM, Corio RL. Cementoblastoma: an innocuous neoplasm? A clinicopathologic study of 44 cases and review of the literature with special emphasis on recurrence. Oral Surg Oral Med Oral Pathol Oral Radiol Endod 2002;93:311-20.
7. Sumer M, Gunduz K, Sumer AP, Gunhan O. Benign cementoblastoma: a case report. Med Oral Patol OralCir Bucal 2006;11(6):E483-5.
8. White, Pharoh. Oral Radiology principles and interpretation. 5<sup>th</sup> ed. Missouri: Mosby; 2009. p.434-8.
9. Pynn BR, Sands TD, Bradley G. Benign cementoblastoma: A case report. J Can Dent Assoc 2001;67(5):260-2.
10. Ghom AG, Meshram V, Diwe A, Kolte V. Benign Cementoblastoma. J Indian Acad Oral Med Rad 2010;22:42-4.
11. Norberg O. Zur Kenntnis der dysontogenetischen Geschwulste der Kieferknochen. Vrtljsschr f Zahn 1930;46:321-55.
12. Regezi JA, Kerr DA, Courtney RM. Odontogenic tumors: analysis of 706 cases. J Oral Surg 1978;36(10):771-8.
13. Garlick AC, Newhouse RF, Boyd DB. Benign cementoblastoma: report of a case. Mil Med 1990;155(11):567-70.
14. Slootweg PJ. Cementoblastoma and osteoblastoma: A comparison of histological features. J Oral Pathol Med 1992;21(9):385-89.
15. Nortje CL. Roentgenologische diagnose. J Dent Assoc S Afr 1974;29(1):535-6.
16. Slootweg PJ. Cementoblastoma and osteoblastoma: a comparison of histological features. J Oral Pathol Med 1992;21(9):385-9.
17. Papageorge MB, Cataldo E, Nghiem F. Cementoblastoma involving multiple deciduous teeth. Oral Surg Oral Med Oral Pathol 1987;63(5):602-5.
18. Piattelli A, Di Alberti L, Scarano A, Piattelli M. Benign cementoblastoma associated with an unerupted third molar. Oral Oncol 1998;34(2):229-31.
19. Shafer WG, Hine MK, Levy BM. A textbook of oral pathology. 4th ed. Philadelphia: W.B. Saunders; 1983. p.917.
20. Sapp J, Eversole L, Wysocki G. Contemporary oral and maxillofacial pathology, St. Louis, US: Mosby-Year Book; 1997.
21. Napier Souza L, Monteiro Lima S, Júnior, Garcia Santos Pimenta FJ, Rodrigues Antunes Souza AC, Santiago Gomez R. Atypical hypercementosis versus cementoblastoma. Dentomaxillofac Radiol 2004;33(4):267-70.
22. Gulses A, Bayar GR, Aydin C, Sencimen M. A case of a benign cementoblastoma treated by enucleation and apicectomy. Gen Dent 2012;60(6):e380-2.
23. Goerig AC, Fay JT, King E. Endodontic treatment of a cementoblastoma. Oral Surg Oral Med Oral Pathol

Received: 12 August, 2016

Revised: 6 January, 2017

Accepted: 13 January, 2017

## Address for Correspondence:

Anam Javed, Department of Oral and Maxillofacial Surgery, Ayub Teaching Hospital Abbottabad-Pakistan

Cell: +92 3119563536, Email: javed.anam@yahoo.com