

## CASE REPORT

## GARRE'S OSTEOMYELITIS OF LONG BONE IN ADULT.

Amina Gul Shehzar Khan, Haseeb Ahsin, Sajjad Khan, Ansar Rafique, Ratib Kamal

Department of Orthopaedic, Ayub Medical College, Abbottabad-Pakistan

Garre's osteomyelitis is a rare form of chronic osteomyelitis characterized by sclerosing and periosteal reaction of the affected bone. We report a case of a 35-year-old woman who presented with left tibial pain and swelling for 18 months. She was diagnosed with Garre's osteomyelitis of the mid-shaft tibia based on radiological and histopathological findings. She underwent curettage, biopsy and culture of the lesion, which revealed oxacillin-sensitive staphylococcus species. She was treated with targeted antibiotics and showed clinical improvement. This case highlights the importance of considering Garre's osteomyelitis in the differential diagnosis of chronic tibial pain and the role of curettage and antibiotics in its management.

**Keywords:** Sclerosing osteomyelitis; Chronic tibial pain; Cortical hyperostosis

**Citation:** Khan AGS, Ahsin H, Khan S, Rafique A, Kamal R. Garre's Osteomyelitis of long bone in adult. J Ayub ed Coll Abbottabad 2024;36(3):674-7.

**DOI:** 10.55519/JAMC-03-13309

## INTRODUCTION

A rare chronic inflammatory condition called sclerosing osteomyelitis of Garré is characterized by thickening of the cortices and loss of the medullary canal.<sup>1</sup> Other names for it include ossifying periostitis, Garré's sclerosing osteomyelitis, nonsuppurative chronic sclerosing osteomyelitis, and chronic osteomyelitis with proliferative periostitis.<sup>1,2</sup> Garré originally reported primary chronic sclerosing osteomyelitis in 1893. He noted thickening of the cortices and loss of the medullary canal, but no signs of acute infection, such as drainage tracts, bony sequestra, or suppuration.<sup>2</sup> Although it can affect any bone, in children, the metaphyses of the long bones are where it most frequently manifests. The illness known as sternocostoclavicular hyperostosis (SCCH) was named for the tendency of the lesion to damage the axial skeleton in adults, with a preference for the sternum, first ribs, and medial end of the clavicles. The mandible, sacrum, spine, and diaphysis of long bones are other common sites, followed by the pelvis and shoulder girdle.<sup>3</sup> Sclerosing osteomyelitis of Garré is thought to be caused by a low-grade viral infection or irritation, however this is still up for debate. One study suggested that it is associated with the host's immune condition, while another found that it is a side effect of the surgical treatment of femur fracture repair.<sup>4</sup> The common microorganisms responsible for this illness are Streptococci, Klebsiella, and Staphylococci.<sup>5</sup> The main complaint is typically mild pain near the affected bone that starts slowly and lasts for a few months before a patient seeks medical attention. The diaphysis of long bones is most frequently affected by the condition. Typically, the clinical description lacks specificity.

Over a period of years, symptoms may flare up and then gradually go away. Years after beginning, a secondary lesion may develop at a different location. It's a long and unpredictable course. In between flare-ups, the majority of patients are well. Physical examination may reveal soreness and swelling around the injured bone.<sup>6</sup> Laboratory results often indicate a slight rise of inflammatory markers, such as erythrocyte sedimentation rate (ESR) and C-reactive protein (CRP). Blood and tissue cultures typically come up negative. Radio imaging typically reveals periosteal response and cortical thickness. Increased uptake at the affected location may be seen in isotope scans. Results from biopsies typically reveal persistent, non-specific inflammatory alterations.<sup>7</sup> The primary focus of treatment is on symptoms, while some individuals may respond momentarily to analgesics. Although the precise process is still unknown, antibiotic medication can temporarily ease symptoms. There aren't many other therapies that have been demonstrated to slow the course of the illness. Surgical alternatives include wire fixation, excision with bone grafting, resection of the area of persistent osteomyelitis, and debridement of the bone with exposure of the medulla. But even after receiving treatment, patients may relapse in their symptoms years later or develop new diseases, such as osteoid osteomas or other bone tumors.<sup>2</sup> Ewing sarcoma, osteosarcoma, and cortical hyperostosis (also known as Caffey disease) are among the differential diagnoses for Garre's osteomyelitis.<sup>8</sup> Here we describe a 35 years old woman with Garre's osteomyelitis of the mid-shaft tibia after presenting with chronic tibial pain and swelling.

## CASE PRESENTATION

A 35-year-old woman presented to our outpatient department on March 2<sup>nd</sup>, 2023 with a history of left tibial pain and swelling for 18 months. The pain was more severe at night and was relieved by oral pain killers. She had no history of trauma, fever, weight loss or other systemic symptoms. She had no history of diabetes, tuberculosis or other chronic diseases. She had no history of previous surgery or dental infection. She was not taking any medications except for analgesics.

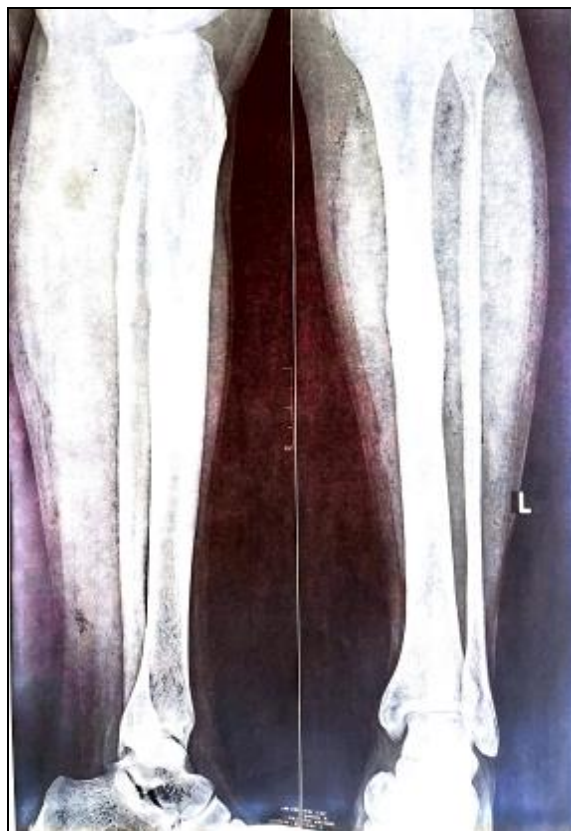On physical examination, she had a firm, tender, bony hard swelling along the anteromedial aspect of left tibial mid-shaft, measuring about 10 cm in length and 5 cm in width. There was no local warmth, erythema or sinus formation. The overlying skin was normal. The range of motion of the left knee and ankle joints was normal. There was no lymphadenopathy or organomegaly.

The laboratory investigations showed normal blood counts, erythrocyte sedimentation rate, C-reactive protein and serum calcium levels. The liver and renal function tests were normal. The blood culture was negative. The Mantoux test was negative.

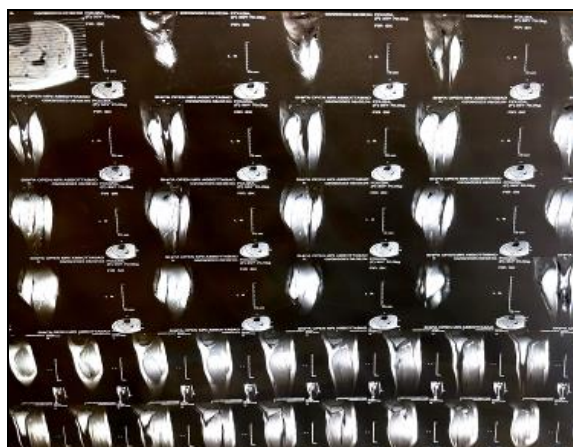
The radiological investigations included an X-ray, a magnetic resonance imaging (MRI) and a computed tomography (CT) scan of the left tibia. The X-ray showed a lytic lesion with periosteal reaction involving the mid-shaft of the left tibia (Figure 1). The MRI showed sclerosing osteomyelitis involving the mid-shaft of the left tibia with cortical thickening and periosteal reaction (Figure 2). The CT scan confirmed the findings of the MRI and ruled out any osteoid osteoma or osteochondroma and revealed cortical thickening, periosteal reaction and medullary cavity sclerosis representing sclerosing osteomyelitis of Garre's. (Figure 3) Based on these findings, a diagnosis of Garre's osteomyelitis of the left tibia was made. The patient was admitted on March 22<sup>nd</sup>, 2023 for curettage, biopsy and culture of the lesion. Under general anaesthesia, a longitudinal incision was made over the anteromedial border of the left tibia and the periosteum was elevated. The sclerotic bone was curetted and sent for histopathological and microbiological examination. The wound was irrigated with saline and closed in layers. A below-knee plaster cast was applied.

The histopathological examination showed mature bone lamellae, fibromuscular and fibro collagenous tissue along with areas of cauterized tissue. There was no evidence of inflammation, granuloma or malignancy. The microbiological examination showed oxacillin-sensitive staphylococcus species, not aureus. The patient was started on intravenous oxacillin for two weeks, followed by oral oxacillin for four weeks. She

showed clinical improvement with resolution of pain and swelling. The plaster cast was removed after six weeks and she was advised to do physiotherapy exercises. The follow-up X-ray after three months showed regression of the periosteal reaction (Figure 4). The patient was asymptomatic at six months follow-up.



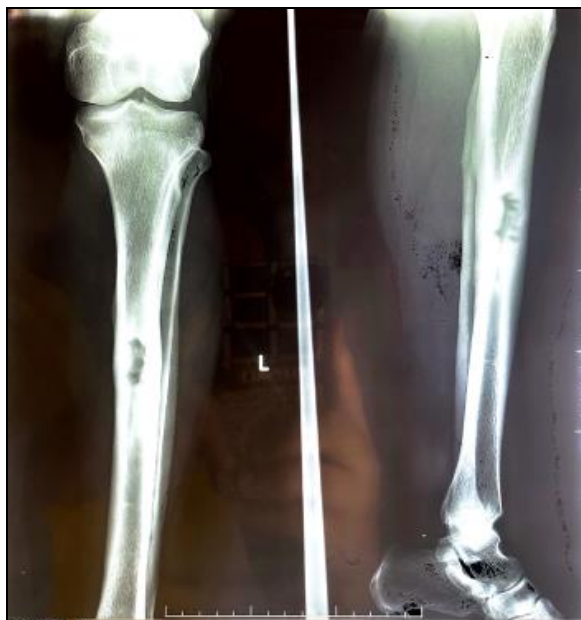**Figure 1 X-ray showing a lytic lesion with periosteal reaction involving the mid-shaft of the left tibia.**



**Figure-2: MRI showing sclerosing osteomyelitis involving the mid-shaft of the left tibia with cortical thickening and periosteal reaction**



**Figure-3: CT scan confirming the findings of the MRI and ruling out any osteoid osteoma or osteochondroma.**



**Figure-4: Follow-up X-ray after three months showing regression of the periosteal reaction**

## DISCUSSION

Garre's sclerosing osteomyelitis is a particular kind of chronic osteomyelitis that was first identified by Carl Garre in 1893. It is characterized by a localized gross thickening of the periosteum and peripheral reactive bone production as a result of infection.<sup>9</sup> The cause of this illness is still not entirely understood. Although there is a suspicion of bacterial infection, cultures are typically negative, and low-virulence infections or even infections that have been treated may continue the chronic process. Polymerase chain reaction (PCR) analysis should be requested if the germ cannot be identified by culture.<sup>10</sup> There are stages of remission and exacerbation due to the common pathogens *Staphylococcus*, *Klebsiella*, and *Streptococcus* encounter in the disease process.<sup>5</sup> Sclerosing osteomyelitis of Garré patients typically experience growing swelling over time along with persistent discomfort.<sup>4</sup> Similarly, our patient presented with left tibial pain and swelling for the last 18 months. The pain was worst at night and was relieved by taking oral painkillers. Aggressive disease was unlikely because the physical examination, laboratory tests, and non-

specific histopathological findings were all basically normal. In patients with sclerosing osteomyelitis of Garré, elevated inflammatory markers, negative tissue culture results, and radiographic abnormalities are typical characteristics.<sup>7</sup> Unlikely in our case, she had a firm, tender, bony hard swelling along the anteromedial aspect of left tibial mid-shaft, measuring about 10 cm in length and 5 cm in width on physical examination. Her investigations were unremarkable except x-ray and magnetic resonance imaging. The x-ray revealed a lytic lesion with periosteal reaction involving the mid-shaft of the left tibia and the magnetic resonance imaging showed sclerosing osteomyelitis involving the mid-shaft of the left tibia with cortical thickening and periosteal reaction. Consequently, the CT scan confirmed the findings of MRI and ruled out any osteoid osteoma or osteochondroma. Apart from Garre's osteomyelitis, other clinical diseases can also lead to the production of new bone. Consequently, it needs to be differentiated from other conditions that result in the formation of new bone, such as fibrous dysplasia, Paget's disease, Ewing's sarcoma, Caffey disease, osteosarcoma, and hard, nodular, or pedunculated masses observed in the mandible (peripheral osteomas, torus and exostoses, ossifying subperiosteal hematoma, etc.).<sup>11</sup> Resolving Garre's osteomyelitis effectively necessitates combining surgical and medicinal methods. Antibiotic treatment deals with the underlying illness, whereas surgical debridement helps to remove the sequestrum and lower the bacterial load. In this instance, the patient's recovery was greatly aided by the discovery of *Staphylococcus aureus* and the subsequent focused antibiotic treatment.<sup>12</sup> However, in our case we made a longitudinal incision over the anteromedial border of the left tibia and the periosteum was elevated under general anaesthesia. The sclerotic bone was curetted and sent for histopathological and microbiological examination. The wound was irrigated with normal saline and closed in layers. A below-knee plaster cast was applied.

The histopathological examination showed mature bone lamella, fibromuscular and fibro collagenous tissue along with areas of cauterized tissue. There was no evidence of inflammation, granuloma and malignancy. The microbiological examination showed Oxacillin-sensitive staphylococcus species, not aureus. Hence, the patient was commenced on intravenous oxacillin for two weeks, followed by oral oxacillin for four weeks. Consequently, she got clinical improvement with resolution of pain and swelling. The plaster cast was removed after six weeks and she was advised to do physiotherapy exercises. The follow up x-ray after three

months showed regression of the periosteal reaction and she became asymptomatic at six months follow up.

## CONCLUSION

In our case, we presented a rare case of Garre's osteomyelitis of the mid-shaft tibia in a 35-year-old woman who presented with chronic tibial pain and swelling. She was diagnosed with Garre's osteomyelitis based on radiological and histopathological findings. She underwent curettage, biopsy and culture of the lesion, which revealed oxacillin-sensitive staphylococcus species. She was treated with targeted antibiotics and showed clinical improvement. She had no recurrence or complications at six months follow-up. This case highlights the importance of considering Garre's osteomyelitis in the differential diagnosis of chronic tibial pain and the role of curettage and antibiotics in its management.

## REFERENCES

1. Song S, Jeong HJ, Shin HK, Kim E, Park SJ, Park JH. Sclerosing osteomyelitis of Garré: A confusing clinical diagnosis. *J OrthopSurg (Hong Kong)* 2019;27(3):2309499019874704.
2. Vannet NB, Williams HL, Healy B, Morgan-Jones R. Sclerosing osteomyelitis of Garré: management of femoral pain by intramedullary nailing. *BMJ Case Rep* 2014;2014:bcr2014206533.
3. Calamita AG, Stimolo D, Puccini S, Innocenti M, Campanacci DA. Garré Sclerosing Osteomyelitis of the Clavicle: Clinical Results after Clavicular Resection. *Healthcare (Basel)* 2024;12(2):202.
4. Bai S, Zhang H, Li Z, Li D, Li H. A 53-year-old man with a sclerosing rib lesion: A case report. *Medicine (Baltimore)* 2017;96(47):e8692.
5. Jayanthan SS, Ganesh R. Garré's Sclerosing Osteomyelitis with Perimandibular Soft Tissue Inflammation and Fistula. *Indian J Radiol Imaging* 2021;31(4):1016–8.
6. Nikomarov D, Zaidman M, Katzman A, Keren Y, Eidelman M. New treatment option for sclerosing osteomyelitis of Garré. *J PediatrOrthop B* 2013;22(6):577–82.
7. Ghazali FR, Samsudin AH. Sclerosing Osteomyelitis of Garré: A Clinico-Radiological Correlation. *Cureus* 2022;14(7):e26866.
8. Barbur I, Bran S, Baciut M, Armencea G, Aghiorghiesei AI, Suciu TS, Barbur AM, Opris H, Baciut G, Dinu C. An Orthodontic Approach for Garre's Sclerosing Osteomyelitis of the Mandible. *Int J Environ Res Public Health* 2021;18(6):3159.
9. Elera-Fitzcarrald C, Alfaro-Lozano JL, Pastor-Asurza CA. Garre's sclerosing osteomyelitis caused by salmonella group D in a patient with systemic lupus erythematosus: an unusual complication. *Clin Rheumatol* 2015;34(12):2155–8.
10. Moraes FB, Motta TM, Severin AA, Faria DD, César FD, Carneiro SD. Garré's sclerosing osteomyelitis: case report. *Rev BrasOrtop* 2014;49(4):401–4.
11. Akgül HM, Çağlayan F, Günen Yılmaz S, Derindağ G. Garre's osteomyelitis of the mandible caused by infected tooth. *Case Rep Dent* 2018;2018:1409539.
12. Kaushik K, Pundkare GT, Tawde A, Kannan A. A Rare Case of Garre's Osteomyelitis of Tibia in an Adult. *Cureus* 2024;16(2):e54034.

Submitted: April 30, 2024

Revised: --

Accepted: October 30, 2024

### Address for Correspondence:

**Amin Gul Shezar Khan**, Department of Orthopaedic, Ayub Medical College, Abbottabad-Pakistan

**Email:** minakhan137@gmail.com