

CASE REPORT

UNVEILING A RARE CASE OF KIKUCHI-FUJIMOTO IN SINDH, PAKISTAN

Saira Bano¹, Inshal Jawed², Fasiha Bakhtawar Fatima¹, Mohammad Omer Alam³, Ahsan Feroze⁴¹PNS Shifa, Karachi-Pakistan²Department of Internal Medicine, Dow University of Health Sciences, Karachi-Pakistan³Sindh Medical College, Jinnah Sindh Medical University, Karachi-Pakistan⁴Department of Internal Medicine, Jinnah Postgraduate Medical Center, Karachi-Pakistan

Kikuchi-Fujimoto disease (KFD) commonly manifests with symptoms of fever, tender cervical adenopathy, and systemic symptoms like night sweats, rashes, headache, weight loss, nausea, vomiting, and sore throat. In this case study, a 27-year-old patient's main complaints included fever, neck oedema, and weight loss that started one month ago. Following preliminary inquiries, ultrasonography, and CT scans, a multidisciplinary team has been overseeing the case. After a biopsy of axillary and cervical lymph nodes, it has been diagnosed as a case of Kikuchi-Fujimoto disease overlapping with Systemic Lupus Erythematosus. Symptomatic and specific treatment started which showed improvement in 4 weeks. The treatment is symptomatic because of the benign characteristic and typical resolution within several weeks to months. The prognosis is usually excellent without an increased risk of malignancy or mortality.

Keywords: Kikuchi-Fujimoto; Pakistan; Rare

Citation: Bano S, Jawed I, Fatima FB, Alam MO, Feroze A. Unveiling a rare case of Kikuchi-Fujimoto in Sindh, Pakistan. J Ayub Med Coll Abbottabad 2024;36(1):226–9.

DOI: 10.55519/JAMC-01-12794

INTRODUCTION

Kikuchi-Fujimoto disease (KFD), or histiocytic necrotizing lymphadenitis, is a rare disorder described by two Japanese scientists, Seishi Kikuchi, and Y. Fujimoto, in 1972. The disease commonly manifests with symptoms of fever, tender cervical adenopathy, and systemic symptoms like night sweats, rashes, headache, weight loss, nausea, vomiting, and sore throat.¹ Several associations have been noted of KFD with certain autoimmune disorders like systemic lupus erythematosus (SLE), polymyositis, scleroderma, lymphoma, thyroiditis and Sjogren syndrome and viral diseases like Varicella Zoster Virus (VZV), Herpes Simplex Virus (HSV), and Epstein-Barr virus (EBV), however, exactly aetiology remains unclear.²

Research shows that this disorder mainly affects young adults <40 years of age but can occur in any age group with slight female predominance.³ Mostly a benign self-limiting disorder resolving within a few weeks or months, this disorder can clinically be diagnosed by lymph node excision biopsy.¹

CASE PRESENTATION

We report a rare case of a 27-year-old male presenting to the hospital's OPD with complaints of intermittent high-grade fever associated with night sweats, neck swelling, a significant weight loss of 7-8 kg over one month, and reduced appetite. The

patient had a positive family history of TB. No other record of diarrhoea, vomiting, burning micturition, joint pain, or rash was reported. Initially, the patient presented with a single swelling of about 1 cm on the left side of his neck; later, during the hospital stay, he also developed nodes in the right axilla and left inguinal region, gradually increasing in size with mild tenderness. The patient underwent lab investigations like Complete Blood Count (CBC), malarial parasite by ICT, Blood and Urine culture, HIV serology, Dengue serology, and Urine RE. The initial studies were unyielding for any significant results. Nonetheless, key results on CT scans of the neck, chest, abdomen, and pelvis as well as ultrasounds of the cervical and axillary oedema were published. Prominent lymph nodes were noted in the (L) posterior cervical chain of size 0.4×1.5 cm, reported as posterior cervical lymphadenopathy. Also, multiple enlarged lymph nodes were recorded in the axillary area, with one measuring about 1.8 cm in the short axis with no significant internal necrosis.

Further investigation with a CT scan showed that the patient had enlarged axillary lymph nodes with intact fatty hila, the largest measuring about 18.8 mm in short axis dimension. A few enlarged mesenteric lymph nodes were also seen, with the largest measuring 11mm in short axis dimension in the inter aortocaval region. A well-defined necrotic collection with air-fluid level is seen in skin and subcutaneous tissues of the left

posterior cervical region in between the posterior border of the sternocleidomastoid and anterior border of ribs measuring 2.3×1.6 cm AP×T dimensions. The CT findings prompted a cervical and axillary lymph node biopsy and histopathology, Mantoux test, ANA profile, anti-dsDNA, AFB/Gene expert as advised by the multidisciplinary team (MDT) including Head of the Department of Medicine with an experience of about 15 years, pulmonologist, infectious disease specialist, consultant histopathologist and a rheumatologist, according to the laboratory reports of Mantoux test and ANA profile, which shows negative result. The result of Anti-dsDNA also reports a value of 25.35, which is slightly above from normal value. All the reports were adverse except the biopsy reports, which showed solid results for Necrotizing Lymphadenitis. Microscopic sections reveal fragments of lymph node showing partial effacement of nodal architecture and the paracortical areas are expanded and pale with sheets of histiocytes, plasmacytoid dendritic cells, lymphocytes, karyorrhexis debris along with foci of necrosis while the cortex shows reactive follicles composed of mature lymphocytes admixed with immunoblasts. It was reported that the morphology seen on biopsy favours Kikuchi Lymphadenitis histologically; however, these morphological changes can be found in other autoimmune disorders. The patient underwent symptomatic treatment, including a non-steroidal anti-inflammatory drug, a regimen of corticosteroids, and immunosuppressant Hydroxychloroquine (HCQ). At an interval of 4 weeks, the patient exhibited improvement in his symptoms with a resolution of fever and a gradual decrease in the size of the affected lymph nodes. The patient has been scheduled for regular follow-ups to assess the disease's prognosis and treat the overlapping condition of SLE.

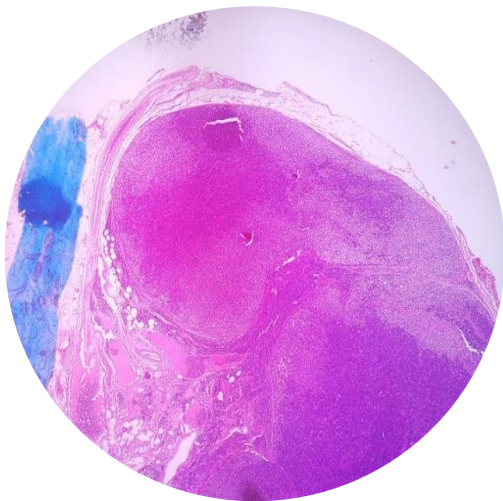


Figure-1: Microphotographs showing lymph node biopsy

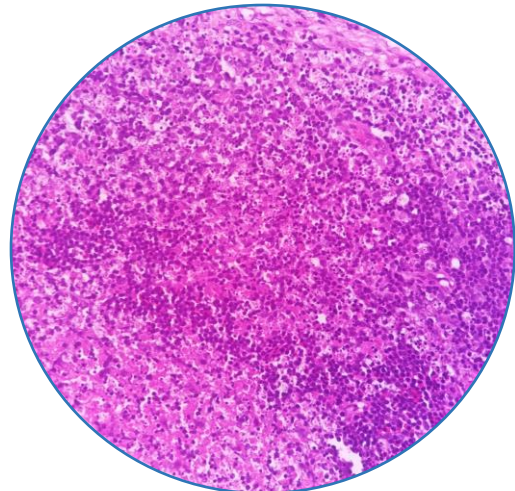


Figure-2: Lymph node biopsy showing capsular invasion

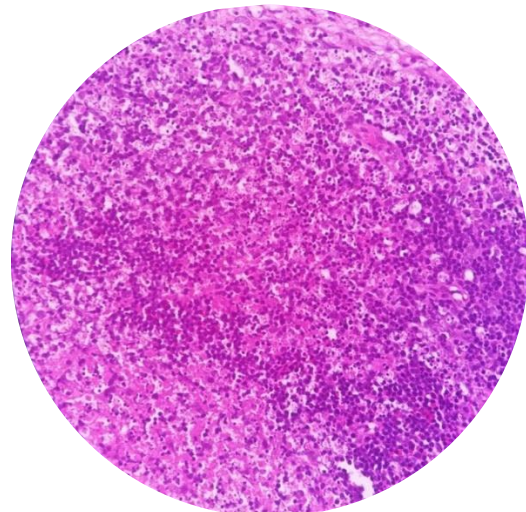


Figure-3: Lymph node biopsy showing capsular invasion.

DISCUSSION

Kikuchi Fujimoto disease is one of the rare diseases, most commonly inflicted on Japanese and East Asian people; however, currently, its occurrence is surging worldwide.⁴ We report one of the few cases from Pakistan with some atypical presentations.

Commencement of KFD is acute or subacute as it establishes itself in 2–3 weeks. The disease is associated with enlarged lymph nodes in the cervical region 56–98% of the time, specifically the posterior cervical triangle (88.5%), which are primarily unilateral (88.5%) and painful (59%). Lymph nodes are typically 0.5–4 cm in size and rarely exceed 6 cm. Only 1–22% of patients experience Generalised Lymphadenopathy, rarely affecting mediastinal, peritoneal, and retroperitoneal regions. In conjunction with Lymphadenopathy, KFD patients are affiliated

with low-grade fever (30–50%) with concomitant upper respiratory symptoms. Weight loss, nausea, vomiting, sore throat, and night sweats are some of the uncommon symptoms. Moreover, these systemic symptoms correspond to extranodal involvement.³ In contrast to the Literature⁴, our case reported high-grade fever, night sweats, weight loss of 7–8 kg, positive family history of TB, photosensitivity on and off, lymph node enlargement in the left posterior cervical, right axilla, left inguinal region and mesenteric lymph nodes without extranodal presentation which prompted to include TB, SLE, Lymphoma, HIV Sarcoidosis in the differential diagnosis.

Initially, it was hypothesized that Viral agents induce KFD due to the harmonious presentations, ineffective antibiotics, symptoms of upper respiratory tract infections (runny nose, sore throat, fever, and malaise), raised cytokines levels in particular interferon α , furthermore, homogeneous Microscopic features includes; amplification/augmentation of cytotoxic T-cell phenotype immunoblasts, an abundance of atypical/reactive Lymphocytes in blood vessels, inflated and necrosed paracortex (T zone) and lastly high T cell prevalence.^{1,2} Following Viruses have been postulated to be associated with this condition: Epstein-Barr virus; herpes simplex virus; varicella-zoster virus; human herpesviruses 6, 7, and 8; parvovirus B19; paramyxovirus; parainfluenza virus; rubella; cytomegalovirus; hepatitis B virus; human immunodeficiency virus; human T-lymphotropic virus type 1; and dengue virus, however, no causation link have been validated/established.¹ A review by Bosch et al. pondered upon the correlation between the high incidence of DPA1*01 and DPB1*0202 alleles in KFD patients, which are also more prevalent in individuals of Asian origin individuals relative to Caucasians, proposed pathogenesis being the vigorous T cell-mediated immune response against the unproven antigen in the genetically susceptible Asian population.³ A clinicopathologic study of 79 cases links the causation of distinctive necrosis and nuclear debris appreciated in KFD with the proliferation of CD8+ T lymphocytes, cells which, along with instigating apoptosis in others, also go through apoptosis.⁵ Elevated levels of interleukin-6 and Fas ligand Inflammatory mediators have also been coupled with the presence of KFD in previous reports.^{6,7} Even Though these associations have been made, the data is still inconclusive regarding the definitive cause of KFD.

Initially, infectious lymphadenitis, autoimmune causes such as systemic lupus erythematosus (SLE), and malignancy, especially lymphoma, are considered before diagnosing Kikuchi-Fujimoto disease.¹ Confirmatory diagnosis of

Kikuchi-Fujimoto disease relies on an excisional biopsy of the affected lymph node and performing immunohistochemistry. The disease exhibits three histological stages- proliferative, necrotizing, and xanthomatous. The lack of neutrophils or eosinophils in all three phases of the disease is a striking feature that distinguishes it from infective causes.^{8,9} Moreover, harmful microscopic and culture data will further cement the notion of ruling out infectious aetiology.¹⁰

Eventually, immunohistochemistry will reveal histiocytes consisting of CD163, CD68, lysozyme, CD4, and myeloperoxidase. CD8-positive T cells and TCL 1 and plasmacytoid dendritic cells (pDCs) will also be present, showing definitive CD123 presence.⁸ Peculiarly, positive B cells for CD20 will be harmful.¹ Furthermore, clinical examination of lymphomas and other malignancies usually show immobile, painless, and enlarged lymph nodes with slower progression than in Kikuchi disease.¹¹ These key findings can aid in correctly diagnosing the disease and ruling out lymphoma.

The histopathology of Kikuchi-Fujimoto disease and SLE lymphadenitis share standard features. Yet, a biopsy and the clinical and serological picture can be crucial in distinguishing between the two diseases. The biopsy in SLE may exhibit DNA deposits in vessel walls, haematoxylin bodies (collections of nuclear DNA), and necrosis areas accompanied by vasculitis regions. These distinct histological features paint a picture of SLE rather than Kikuchi disease.¹² Specifically, haematoxylin bodies are only present in SLE lymphadenitis, not Kikuchi disease.¹ Also, exclusively in KFD, the autoimmune markers for SLE will be negative. Since there is ambiguity between the relationship between Kikuchi disease and other autoimmune diseases and reported cases of SLE and Kikuchi overlapping, it's imperative to involve a rheumatologist and follow up with the patient regularly to document any flare-ups.

CONCLUSION

Kikuchi-Fujimoto disease is a rare and self-limiting condition that can present with fever and lymphadenopathy. The prognosis is usually excellent without an increased risk of malignancy or mortality. Prompt diagnoses may prevent unnecessary and invasive investigations, thus providing relief and reassurance to the patient and the clinician. Additionally, the patients may need surveillance for systemic lupus erythematosus after recovery from Kikuchi-Fujimoto disease due to their potential association.

Conflict of interest: The authors do not have any conflicts of interest.

Acknowledgements: N/A

Patient's consent: Consent has been obtained for the submission of this report from the patient.

REFERENCES

1. Perry AM, Choi SM. Kikuchi-Fujimoto disease: A review. Arch Pathol Lab Med 2018;142(11):1341–6.
2. Hutchinson CB, Wang E. Kikuchi-fujimoto disease. Arch Pathol Lab Med 2010;134(2):289–93.
3. Bosch X, Guilbert A, Miquel R, Campo E. Enigmatic Kikuchi-Fujimoto disease: a comprehensive review. Am J Clin Pathol 2004;122(1):141–52.
4. Sarfraz S, Rafique H, Ali H, Hassan SZ. Case report: kikuchi-fujimoto disease: a case of supraclavicular lymphadenopathy. F1000Res 2019;8:1652.
5. Kuo TT. Kikuchi's disease (histiocytic necrotizing lymphadenitis). A clinicopathologic study of 79 cases with an analysis of histologic subtypes, immunohistology, and DNA ploidy. Am J Surg Pathol 1995;19(7):798–809.
6. Kato K, Ohshima K, Anzai K, Suzumiya J, Kikuchia M. Elevated serum-soluble Fas ligand in histiocytic necrotizing lymphadenitis. Int J Hematol 2001;73:84–6.
7. Kubota M, Tsukamoto R, Kurokawa K, Imai T, Furusho K. Elevated serum interferon γ and interleukin-6 in patients with necrotizing lymphadenitis (Kikuchi's disease). Br J Haematol 1996;95(4):613–5.
8. Cuglievan B, Miranda RN. Kikuchi-Fujimoto disease. Blood 2017;129(7):917.
9. Joean O, Thiele T, Raap M, Schmidt RE, Stoll M. Take a second look: it's Kikuchi's disease! A case report and review of literature. Clin Pract 2018;8(4):1095.
10. Lelii M, Senatore L, Amodeo I, Pinzani R, Torretta S, Fiori S, et al. Kikuchi-Fujimoto disease in children: two case reports and a review of the literature. Ital J Pediatr 2018;44(1):83.
11. Feder Jr HM, Liu J, Rezuke WN. Kikuchi disease in Connecticut. J Pediatr 2014;164(1):196–200.e1.
12. Baenas DF, Diehl FA, Haye Salinas MJ, Riva V, Diller A, Lemos PA. Kikuchi-Fujimoto disease and systemic lupus erythematosus. Int Med Case Rep J 2016;29:163–7.

Submitted: December 28, 2023

Revised: February 28, 2024

Accepted: March 13, 2024

Address for Correspondence:

Inshal Jawed, Department of Internal Medicine, Dow University of Health Sciences, Karachi-Pakistan

Cell: +92 341 263 6484

Email: inshaljwd@gmail.com