

## ORIGINAL ARTICLE

## CHARACTERISTICS AND OUTCOMES OF AERODIGESTIVE FOREIGN BODIES IN CHILDREN

Murad Habib, Khurrum Arif, Muhammad Amjad Chaudhary

Department of Paediatric Surgery, The Children's Hospital Pakistan Institute of Medical Sciences Islamabad-Pakistan

**Background:** Aerodigestive foreign bodies are common in children of pre-school-going age. It is one of the leading cause of morbidity and mortality in the paediatric population and a global health burden. **Methods:** We present here data of 108 patients who presented to Children hospital's Emergency with a suspicion of foreign body ingestion/aspiration over 2 years from July 1<sup>st</sup> 2021 to 30<sup>th</sup> June 2023. Their descriptive analysis including, socio-demographics, type of foreign body, age of presentation, and mode of presentation were calculated and correlation was done using the Pearson Chi square test. **Results:** We observed different types & characteristics of foreign bodies, patients were predominantly male with 62.26%. The mean age of presentation was 40.97 months. The majority of patients were of pre-school age, younger than 4 years (44.44%) followed by the infant population (19.44%)  $p=0.002$ . Foreign bodies were mainly located in the upper oesophagus for ingested FBs (60.8%). Most of the population presented within the first 5 hours (52.88%) followed by the first 12 hours (11.11%). Coin ingestion was by far the most common (54%) followed by button battery (19%) and the whistle was the most common aspirated object (33%). **Conclusion:** All patients with a suspicion of foreign body ingestion/inhalation should be evaluated. Early recognition and treatment are imperative because the complications are serious and can be life-threatening and once confirmed should undergo endoscopic removal.

**Keywords:** Foreign body, ingestion, aspiration, paediatric

**Citation:** Habib M, Arif K, Chaudhary MA. Characteristics and outcomes of aerodigestive foreign bodies in children: A tertiary care experience. J Ayub Med Coll Abbottabad 2023;35(4 Suppl 1):726–31.

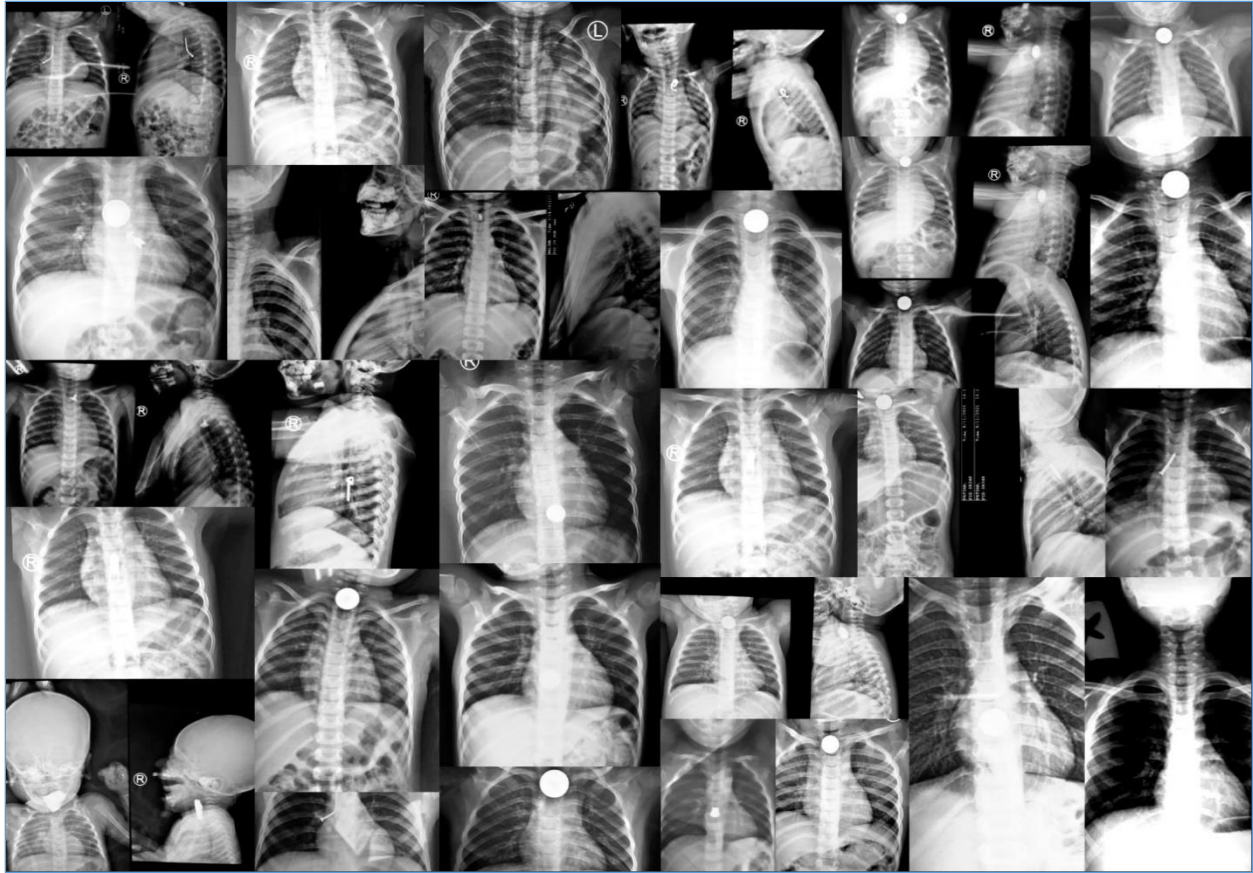**DOI:** 10.55519/JAMC-S4-12199

## INTRODUCTION

Aerodigestive foreign bodies present a diagnostic dilemma in the paediatric population. They are common in children of pre-school going age. Aerodigestive foreign bodies are a preventable phenomenon.<sup>1</sup> Most foreign bodies will pass through the aerodigestive tract spontaneously; however, fewer may get lodged which depends on the site of the foreign body, size of the foreign body & time of ingestion. There are three potential sites of constriction/lodgement in the oesophagus and most common being the cervical oesophagus.<sup>2</sup> It is one of the most common presentations in the emergency department. Identification of these foreign bodies in the aerodigestive tract can be challenging due to a lack of communication skills and improper history thus can lead to a vague diagnosis because a patient might well present with atypical symptoms.<sup>3</sup> In adults the most common foreign bodies are the food particles, whereas children due to their inquisitive nature and exploring their surroundings ingest the non-edible objects since there is no swallowing mechanism developed in the children the foreign body.<sup>4</sup> The majority of the foreign bodies get passed through the digestive tract but some do get logged. The oesophageal foreign bodies may present with dysphagia, odynophagia and in some cases complete oesophageal obstruction whereas in the aspiration group, they present with

choking, cough, cyanosis and might end up with anoxic brain injury.<sup>5</sup> Despite the best of efforts over the past decade ADT foreign body is a cause of significant morbidity and mortality in children and causes six deaths per 100,000 and 150 deaths per year in the United States.<sup>6</sup>

Due to poor history and communication with the paediatric patient, it is difficult to localize the foreign body. A chest radiograph is the best initial and non-invasive modality of choice which confirms the diagnosis, however in small aspirated foreign bodies, a computed tomography of the chest may be required.<sup>7</sup> In the past people used to attempt extracting foreign bodies from the upper oesophagus by using a bougie or a Foley catheter but it had its limitations and with the advent of modern science Esophagoscopy and Bronchoscopy are the treatment of choice as they can be used for both diagnostic as well as therapeutic purposes.<sup>8</sup> The availability of both rigid and flexible bronchoscopy should be emphasized since larger aspirates may not be retrievable with a flexible bronchoscope. It also may need a bronchoscope with fluoroscopic guidance.<sup>9</sup> Surgery is only reserved for deeply impacted foreign bodies where conservative measurements and endoscopic manoeuvres have failed. The approach varies from site, type and time of ADT foreign body. Which increases the risk of both morbidity and mortality in paediatric patients.<sup>10</sup>



**Figure-1: Foreign bodies lodged in ADT**

Our study aimed to evaluate and determine the outcomes of foreign bodies lodged in the ADT at our paediatric surgery department and to compare this data in ingestion and aspiration groups. And to attract the attention of caregivers and parents regarding the dangers of foreign body ingestion.

## MATERIAL AND METHODS

A prospective study of all the children with final diagnosis of aerodigestive foreign bodies younger than 13 years of age done between 1<sup>st</sup> July 2021 to 30<sup>th</sup> June 2023 at the Department of Paediatric Surgery, The Children's Hospital (PIMS) Islamabad were included in this study. Foreign bodies were divided into different groups based on their characteristics. Patients were also grouped into low and middle socioeconomic status. A total of 150 patients were included and 108 were enrolled in the study.

Informed consent was obtained from the corresponding parent (male or female). And they were free to decline/withdraw from the study at any point.

All the neonates and children ranging from 1 day to 13 years (male or female) with Foreign

body ingestion/inhalation after written & informed consent were enrolled in the study.

Those patients who already underwent esophagoscopy/bronchoscopy at another hospital were excluded from the study. Total 150 patients were initially included in this study, of whom 42 did not fulfill the inclusion criteria, so the remaining 108 patients were eligible and enrolled in this study.

Patients data were analyzed by using SPSS 24.0. Frequencies and percentages were calculated for qualitative variables. The association between different parameters was determined by using the chi-square test, and a P-value  $\leq 0.05$  was considered significant.

## RESULTS

A total of 108 patients admitted for FB ingestion or aspiration in the paediatric surgery department were evaluated. The patients were predominantly male with 62.26%. The mean age of presentation was 40.97 months. The majority of patients were of pre-school-going age, younger than 4 years (44.44%). They were followed by infant population (19.44%)  $p=0.002$ . Foreign bodies were mainly located in the upper oesophagus for ingested FBs (60.8%). Most

of the population presented within the first 5 hours (52.88%) followed by the first 12 hours (11.11%). Few patients presented late, after weeks and after a month with no symptoms at all (5.55%). The hospitalization period of patients admitted for FB aspiration was longer than that of patients with FB ingestion. Patients were advised to take x-rays post-

operatively. There were no complications. The most commonly ingested FBs were coins (54%) followed by button batteries (12.96%), whereas the whistle was most commonly aspirated (33%) followed by organic seeds (25%). There were two cases of oesophageal perforation followed by button battery ingestion which were managed conservatively.

**Table-1: Distribution of age according to FB in ADT**

Age	Ingestion	Aspiration	Total n=	Percentage	p value
<1yr	08	13	21	19.44	
1-3	39	09	48	44.44	
4-6	11	07	18	16.66	
7-10	06	05	11	10.18	
>10	08	02	10	9.25	
Total	72	36	108		p=0.049

**Table-2: Distribution of Gender according to Groups**

Gender	Ingestion	Aspiration	Total n=	Percentage	p value
Male	45	21	66	62.26	
Female	27	15	42	37.74	
Total	72	36	108		p=0.175

**Table-3: Time of presentation of Foreign bodies**

Length of time	No of Ingestions	No of Aspirations	Total n=	Percentage
0-5 h	39	15	54	52.88
5-10 h	10	02	12	11.11
10-24 h	04	04	08	7.4
1-3 d	05	02	07	6.48
3-7 d	02	04	06	5.55
7-14 d	01	01	02	1.85
14-30 d	01	03	04	3.70
>30 d	04	02	06	5.55
Unknown	06	03	09	8.33
Total	72	36	108	100
p <0.0001				

**Table-4: Types of foreign bodies**

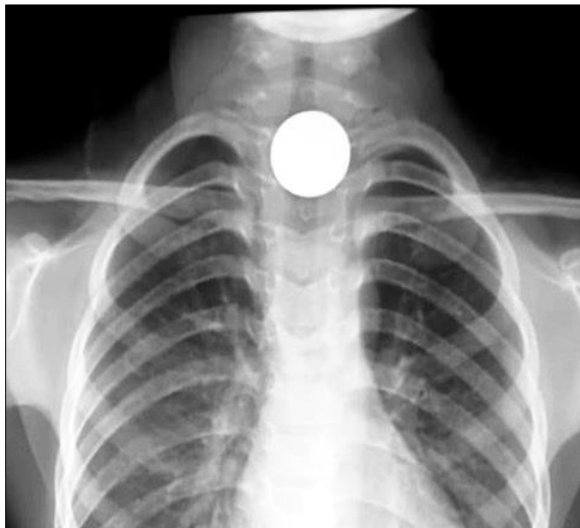Foreign body	Ingestion	%age	Aspiration	%age	Total n=	Percentage
Coin	39	54.16	00	-	39	36.11
Whistle	00	-	12	33.33	12	11.11
Peanut	00	-	07	19.44	07	6.48
Seeds	02	2.7	09	25	11	10.18
Button battery	14	19.44	00	-	14	12.96
Metallic object	07	9.72	03	8.33	10	9.25
Plastic objects	04	5.55	04	11.11	08	7.40
Ear rings	04	5.55	00	-	04	3.70
Bone	02	2.77	01	2.77	03	2.77
Total	72		36		108	100
P=0.0002						

**DISCUSSION**

Decades ago, ADT foreign bodies were a major health burden. They would not only increase morbidity but also mortality in children. An attempt to extract the foreign body from the ADT would end up in hazardous complications. The prognosis of an untreated foreign body is hazardous. In the 1990s the complication rates were more than 50% as reported by Terraol.<sup>11</sup> There were a total of 150 cases of both foreign body ingestion and inhalation

out of 42 were excluded and 108 were enrolled in the study n=72 (66.67%) in the ingested group and n=36 (33.33%) in the aspiration group. Children aged 5 years and below account for approximately 100, 000 cases of FB ingestion annually in the United States alone, with a peak incidence of less than 3 years of age and a predominantly male population as evaluated by our study.<sup>12</sup> From ingesting a coin to a button battery or seeds patients are presented with all types of household objects. Their symptoms range from dysphagia, and

odynophagia to no symptoms at all. Whereas foreign body ingested at the level of cricothyroid can give a varied presentation and might as well present with cough and drooling of saliva giving the suspicion of foreign body aspiration.<sup>13</sup> The management of oesophageal foreign bodies varies from place to place to site of impaction to time of presentation. According to our data most common site of impaction was the upper oesophagus this is in accordance to Smith *et al.*<sup>14</sup>

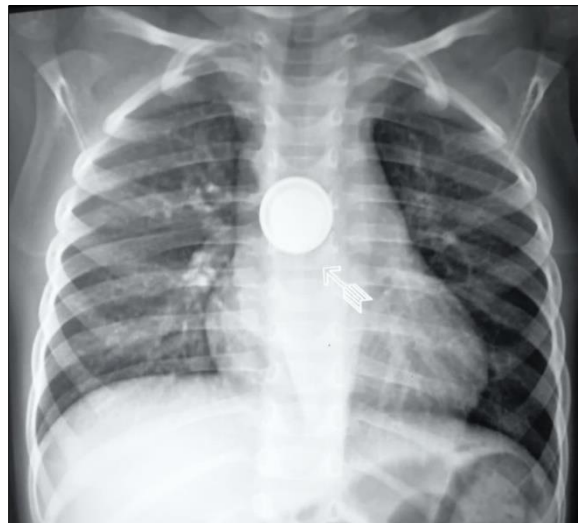

**Figure 2: A radiopaque foreign body in the upper oesophagus**

A coin is by far the most commonly ingested foreign body 36.11% with statistically significant results.<sup>14</sup> Due to dubious history in paediatric patients and no symptoms at all it is difficult to diagnose a case of foreign body ingestion. Thus, a chest radiograph is the initial most important diagnostic modality. An antero-posterior (AP) neck chest and abdomen radiograph is obtained. On the antero-posterior (AP) radiograph a coin appears as a radio-dense object as seen in Figure 2. For a more detailed examination, a lateral chest radiograph can also be obtained to differentiate between a foreign body in the oesophagus and trachea. In comparison a coin in the trachea would appear as a dense circular object with opacity as tracheal cartilages resist penetration. It is to be noted that most of the coins pass spontaneously without producing any symptoms. It is those with a diameter greater than  $> 23\text{mm}$  will get stuck in the oesophagus.<sup>15</sup>

In contrast to an ingested coin, a button battery can present devastating results. And it is of utmost importance for radiologists to differentiate between a coin and a button battery. As on an antero-posterior chest radiograph coin would appear as a

radiopaque density whereas a button battery will produce a halo sign. Figure 3



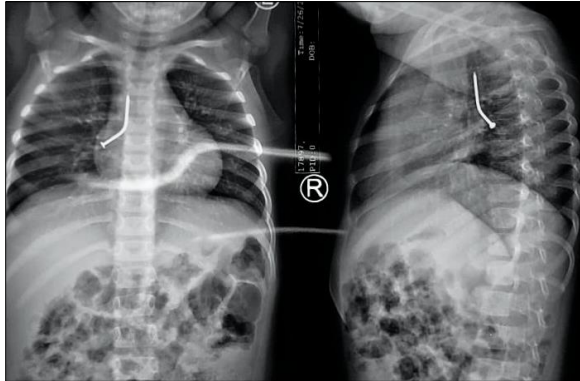
**Figure 3: A button battery in the mid-oesophagus (note the halo sign)**

Of all the oesophageal foreign bodies button battery has the most devastating complications and is the most critical indication of urgent endoscopy in the paediatric population. In addition to low voltage current, it causes pressure necrosis by leaking the alkaline solution. Which has a corrosive effect thus leading to liquefactive necrosis. It causes esophagitis and scarring within the first hour and can lead to oesophageal perforation if delayed more than 6 hours.<sup>16</sup> We had two cases of button battery ingestion who presented late after the ingestion and ended up with oesophageal perforation. Other than this depending on the site of impaction patient might well end up with aorto-oesophageal or trachea-oesophageal fistula.<sup>17</sup>

Foreign body aspiration is a common cause of mortality and morbidity in children, especially in those younger than three years of age. From 2001 to 2016, there were a total of 305,814 nonfatal injuries due to choking in children from 0 to 19 years of age in the United States.<sup>18</sup> Children under five years of age accounted for 73 percent of nonfatal injuries and 75 percent of choking fatalities. Nonetheless, in the United States, FBA was responsible for approximately 5000 deaths in 2020, or approximately 0.6 deaths per 100,000 children zero to four years old. Death caused by suffocation following aspiration is the fourth most common cause and the leading cause of unintentional-injury mortality in children younger than one year in the United States.<sup>19</sup>

Approximately 80 percent of paediatric foreign body aspirations occur in pre-school children younger than three years as reported by our data (63%), with the peak incidence between one and two years of age.<sup>20</sup> At this age, most children can stand and be mobile

independently and are apt to explore their world via the oral route. They also have the fine motor skills to put a small object into their mouths, but they have immature swallowing mechanisms hence resulting in foreign body impaction. Young children are also particularly vulnerable to foreign body aspiration because of the smaller diameter of their airway, which is prone to obstruction.<sup>21</sup> Figure 4



**Figure-4: An aspirated foreign body in the right main bronchus**

An aspirated foreign body is an emergency where retrieval is imminent and the classic triad of cough, wheeze and reduced breath sounds is not always present. Most of the aspirated foreign bodies are common household items lying around that a child grasps while playing or toys which are smaller in diameter as in our case whistle being the most common (33%) or can be organic like seeds (25%) which gets impacted. In Pakistan whistles wrapped in toys and snacks is easily available. And the child while playing with it aspirates. In the case of a whistle when it's choked the child forcefully inhales thus resulting in aspiration.<sup>22</sup> However, the type of foreign body varies from place to place and largely on socioeconomic status.<sup>23</sup> For example, whistle is most commonly aspirated in Pakistan followed by organic seeds. Sunflower, pumpkin and watermelon seeds are the most commonly aspirated foreign bodies in Egypt, Turkey and Greece, whilst fish bones are more commonly reported in patients from China and Japan.<sup>24</sup>

According to the Royal College of Emergency Medicine, a plain radiograph chest and abdomen should be offered in every patient presenting to emergency with a suspicion of foreign body ingestion/aspiration. Until and unless there is no affirmation upon the Xray. And an Xray should always be obtained before surgery to localize the exact position. Computed tomography of the chest is rarely used in emergent settings but can help identify an organic foreign body in paediatric patients.<sup>25</sup>

In 1937 Jackson and Jackson published a research paper on the management of the foreign bodies ADT tract where he emphasized the use of rigid endoscope.<sup>26</sup> Soon after in 1945 Richardson used papain in a case of bolus obstruction in the oesophagus which is a proteolytic enzyme and in 1966 Bigler extracted foreign bodies using a Foley catheter both reported in the literature.<sup>26,27</sup> Bonadio and co-workers used dilators to push swallowed oesophageal coins into the stomach.<sup>28</sup>

As McGuirt stated, those advocating the alternative methods generally are physicians who were not specifically trained in foreign body endoscopy.<sup>29</sup> We performed rigid esophagoscopy/bronchoscopy under general anaesthesia for the extraction of ADT foreign body and we believe it's the safest method for the retrieval of an ADT foreign body with a protected airway and our results are similar to those previously published in the literature

## CONCLUSION

All patients with a suspicion of foreign body ingestion/inhalation should be evaluated. Early recognition and treatment are imperative because the complications are serious and can be life-threatening and once confirmed should undergo endoscopic removal.

### Recommendations:

Prevention remains the best treatment, implying an increased education of parents on age-appropriate foods and household items, and strict industry standards regarding the dimensions of toy parts and their secure containers.

### Data Availability

The data that support the findings of this study are available from the corresponding author upon request to the corresponding author.

### Code availability

All study code is available upon request to the corresponding author.

### Conflict of interest

The authors have no conflicts of interest relevant to this article to disclose.

### Ethical Approval

This study was reviewed and approved by the ethical review board of Pakistan Institute of Medical Sciences.

### Consent to Participate

All participants provided informed consent prior to study participation

## AUTHORS' CONTRIBUTION

MH, MAC: Concept. KA: Acquisition of data. MH, KA: Interpretation of data. MH: Statistical analysis. MH, KA: Writing, editing and formatting. MAC: Supervision.

## REFERENCES

1. Hariga I, Khamassi K, Zribi S, Amor MB, Gamra OB, Mbarek C, *et al.* Management of foreign bodies in the aerodigestive

- tract. Indian J Otolaryngol Head Neck Surg 2014;66(Suppl 1):220–4.
2. Rodríguez H, Passali GC, Gregori D, Chinski A, Tiscornia C, Botto H, *et al.* Management of foreign bodies in the airway and oesophagus. Int J Pediatr Otorhinolaryngol 2012;76(Suppl 1):S84–91.
  3. Mathew RP, Liang TI, Kabeer A, Patel V, Low G. Clinical presentation, diagnosis and management of aerodigestive tract foreign bodies in the paediatric population: Part 2. SA J Radiol 2021;25(1):2027.
  4. Uyemura MC. Foreign body ingestion in children. Am Fam Physician 2005;72(2):287–91.
  5. Mishra A, Shukla G, Bhatia N. Aerodigestive foreign bodies. Indian J Pediatr 2000;67:429–33.
  6. Reilly JS, Cook SP, Stool D, Rider G. Prevention and management of aerodigestive foreign body injuries in childhood. Pediatr Clin North Am 1996;43(6):1403–11.
  7. Assefa D, Amin N, Stringel G, Dozor AJ. Use of decubitus radiographs in the diagnosis of foreign body aspiration in young children. Pediatr Emerg Care 2007;23(3):154–7.
  8. Bai W, Zhou X, Gao X, Shao C, Califano JA, Ha PK. Value of chest CT in the diagnosis and management of tracheobronchial foreign bodies. Pediatr Int 2011;53(4):515–8.
  9. Badr AI, Badr UI, El-Attar HAES. Alternative approach in deeply and difficult extracted metallic foreign bodies in bronchial tree. Editor Board 2012;20(3-4):177.
  10. Pinto A, Scaglione M, Pinto F, Guidi G, Pepe M, Del Prato B, *et al.* Tracheobronchial aspiration of foreign bodies: current indications for emergency plain chest radiography. Radiol Med 2006;111(4):497–506.
  11. Al-Qudah A, Daradkeh S, Abu- Khalaf M. Esophageal foreign bodies I. Eur J Cardiothorac Surg 1998;13(5):494–8.
  12. Gummin DD, Mowry JB, Spyker DA, Brooks DE, Fraser MO, Banner W. 2016 annual report of the american association of poison control centers' national poison data system (NPDS): 34th annual report. Clin Toxicol (Phila) 2017;55(10):1072–254.
  13. Pasquariello Jr PS, Kean H. Cyanosis from a foreign body in the esophagus: respiratory difficulties three months after swallowing a coin. Clin Pediatr (Phila) 1975;14(3):223–5.
  14. Smith MT, Wong RKJ. Foreign bodies. Gastrointest Endosc Clin N Am 2007;17(2):361–82.
  15. Chen X, Milkovich S, Stool D, van As AB, Reilly J, Rider G. Pediatric coin ingestion and aspiration. Int J Pediatr Otorhinolaryngol 2006;70(2):325–9.
  16. Webb WA. Management of foreign bodies of the upper gastrointestinal tract: update. Gastrointest Endosc 1995;41(1):39–51.
  17. Sinclair EM, Stevens JP, McElhanon B, Meisel JA, Santore MT, Chahine AA, *et al.* Development and repair of aorto-esophageal fistula following esophageal button battery impaction: A case report. J Pediatr Surg Case Rep 2021;66:101782.
  18. Chang DT, Abdo K, Bhatt JM, Huoh KC, Pham NS, Ahuja GS. Persistence of choking injuries in children. International journal of pediatric otorhinolaryngology. Int J Pediatr Otorhinolaryngol 2021;144:110685.
  19. Kim IA, Shapiro N, Bhattacharyya N. The national cost burden of bronchial foreign body aspiration in children. Laryngoscope 2015;125(5):1221–4.
  20. Eren S, Balci AE, Dikici B, Doblán M, Eren MN. Foreign body aspiration in children: experience of 1160 cases. Ann Trop Paediatr 2003;23(1):31–7.
  21. Committee on Injury, Violence and Poison Prevention. Prevention of choking among children. Pediatrics 2010;125(3):601–7.
  22. Khan AR, Khan NS. Management of Whistle as a Foreign body Tracheobronchial Tree. J Postgrad Med Inst 2004;18(4):602–6.
  23. Salih AM, Alfaki M, Alam-Elhuda DM. Airway foreign bodies: A critical review for a common pediatric emergency. World J Emerg Med 2016;7(1):5–12.
  24. Higo R, Matsumoto Y, Ichimura K, Kaga K. Foreign bodies in the aerodigestive tract in pediatric patients. Auris Nasus Larynx 2003;30(4):397–401.
  25. Lue AJ, Fang WD, Manolidis S, Surgery N. Use of plain radiography and computed tomography to identify fish bone foreign bodies. Otolaryngol Head Neck Surg 2000;123(4):435–8.
  26. Jackson C, Jackson CL. Diseases of the air and food passages of foreign-body origin. Saunders; 1937.
  27. Bigler FC. The use of a Foley catheter for removal of blunt foreign bodies from the esophagus. J Thorac Cardiovasc Surg 1966;51(5):759–60.
  28. Bonadio WA, Jona JZ, Glicklich M, Cohen R. Esophageal bougienage technique for coin ingestion in children. J Pediatr Surg 1988;23(10):917–8.
  29. McQuirt WF. Use of Foley Catheter for Removal of Esophageal Foreign Bodies. A survey. Ann Otol Rhinol Laryngol 1982;91(6 Pt 1):599–601.

Submitted: June 20, 2023

Revised: August 31, 2023

Accepted: September 8, 2023

### Address for Correspondence:

**Murad Habib**, Resident Paediatric surgery, The Children's Hospital, Pakistan Institute of Medical Sciences Islamabad-Pakistan

**Email:** muradhabib007@gmail.com