

CASE REPORT

A DIFFICULT DIAGNOSIS AND CHALLENGING MANAGEMENT OF AN AGGRESSIVE CASE OF AQUAPORIN 4 NEGATIVE NMOSD

Amna Khan, Warda Zahoor, Taskeen Zehra, Zafar Ullah, Nabeel Muzaffar Syed

Shifa International Hospital Islamabad-Pakistan

Neuromyelitis optica spectrum disorders can be challenging to diagnose and manage. There is considerable potential long-term morbidity but this can be avoided by appropriate treatment. Here we present one such case that is interesting as well as instructive.

Keywords: Neuromyelitis optica; Devic's disease; Aquaporin 4; Demyelinating disease

Citation: Khan A, Zahoor W, Zehra T, Ullah Z, Syed NM. A difficult diagnosis and challenging management of an aggressive case of aquaporin 4 negative NMOSD. J Ayub Med Coll Abbottabad 2023;35(3):515-8.

DOI: 10.55519/JAMC-03-11914

INTRODUCTION

Neuromyelitis optica spectrum disorders (NMOSD) are antibody mediated diseases of the central nervous system characterized by demyelination and axonal damage predominantly targeting optic nerves and the spinal cord.¹ Its characteristic features include attacks of bilateral or rapidly sequential optic neuritis, acute transverse myelitis, area postrema syndrome, acute brainstem syndrome, symptomatic narcolepsy and symptomatic cerebral syndrome.² NMOSD is primarily mediated by the humoral immune system with associated astrocyte death, axonal loss, perivascular lymphocytic infiltration, and vascular proliferation with AQP4-IgG autoantibodies playing a direct role in its pathogenesis.³

CASE REPORT

A 39-year-old previously healthy male, with no known comorbidities, presented to the gastroenterology clinic in November 2021 with recent onset intractable vomiting. He had been struggling with post-meal nausea, severe retching and vomiting, which was non-bilious and non-projectile in nature, followed by bouts of hiccups lasting for 20-30 minutes. GI workup including upper and lower GI endoscopies was unremarkable. Neurological examination was also normal at that time. His MRI of the brain was performed and was reported as normal (Figure-1: A, B, C, D).

He was then referred to the psychiatry clinic where he was started on 10mg of escitalopram daily, resulting in mild improvement of his symptoms. In late December 2021, the patient developed difficulty in walking, diplopia and voice changes. Upon neurological examination on Jan 1, 2022, the speech was nasal, there was right-sided ptosis, miosis and nystagmus. The tongue appeared atrophic and deviated to the left. The rest of the

cranial nerves were intact. He also had right-sided ataxia, but muscle power and reflexes were normal. Babinski's reflex was negative bilaterally at that time. A differential diagnosis of Wernicke's encephalopathy or CNS chronic infections or CNS demyelinating diseases was made.

Repeat neuroimaging was performed that revealed a moderate sized T2 and FLAIR bright MR signal which is a mildly enhancing lesion in the medulla and ponto-medullary junction with slight medullary fullness.

Anti AQP4 Antibodies, anti-GAD Antibodies, anti-neuronal profile, Anti MOG antibodies, HIV profile and workup for autoimmune encephalitis were all negative.

A week later, on the eighth of January, 2022, the patient presented with worsening symptoms including urinary retention, dysphagia and a now positive right Babinski sign. He was admitted and started on pulse methylprednisolone 1g daily. After 2 doses, he significantly improved his dysphagia but other symptoms were persistent. Steroids were continued daily for 7 days. Since his symptoms did not resolve significantly, he was started on plasmapheresis on the 15th of January, 2022 and was discharged after 5 sessions on oral steroids 60 mg/day and azathioprine 50 mg/day. One week later his ALT rose to 188 U/L after which, the azathioprine was stopped and mycophenolate mofetil 500 mg twice daily was started. During the month of February, he started having severe painful spasms that continued to worsen and caused significant distress and disability. Carbamazepine and baclofen, in initial doses, failed to control the spasms and he continued to deteriorate.

In March, the patient was readmitted with spasms involving all four limbs, dysphagia and respiratory distress. Despite being placed on high-

flow oxygen, he continued to worsen and needed to be intubated and mechanically ventilated.

Meanwhile, his spasms remained uncontrolled despite baclofen 60 mg per day, carbamazepine 900 mg per day, diazepam 30 mg per day and pregabalin 75 mg twice daily. Weaning the patient off the ventilators was difficult and a tracheostomy had to be performed. Another session of plasmapheresis was conducted. A decision to administer rituximab was reached to control his underlying disease, however, since he had sepsis due to MDR organisms and was being treated with linezolid, colistimethate and minocycline, it was delayed. Meanwhile, IVIG was administered on 17th March 2022. Despite the IVIG, he continued to have severe spasms and difficulty in weaning off the ventilator and it was finally decided to administer the first dose of rituximab after extensive discussions with the family. On 25th March 2022, the first dose of rituximab (MabThera) 1400 mg/11.7ml subcutaneously was given to the patient.

After the 1st dose of rituximab, the patient started showing signs of improvement and was successfully weaned off the ventilator. His diplopia and muscle spasms also improved. His MRI brain was repeated on 30th March 2022 which showed interval subtle regression in size and signal intensities of the lesion in the medulla involving the cervico-medullary junction with no significant enhancement on post-contrast images. (Figure-1: J, K, L, M, N). His 2nd dose of rituximab 1gm was administered on April 8, 2022, after which, he was able to walk with support, albeit with a mild ataxia and residual ptosis. He was discharged on oral steroids and mycophenolate mofetil. The tracheostomy tube was removed on the 22nd of April. For spasticity carbamazepine 400 mg/day and baclofen 40 mg/day were continued and diazepam was tapered off. The patient was able to return to work after a couple of months. He received his 2nd dose of rituximab on the 10th of October 2022. As of late Oct 2022, he can walk without support and is happily continuing his job.

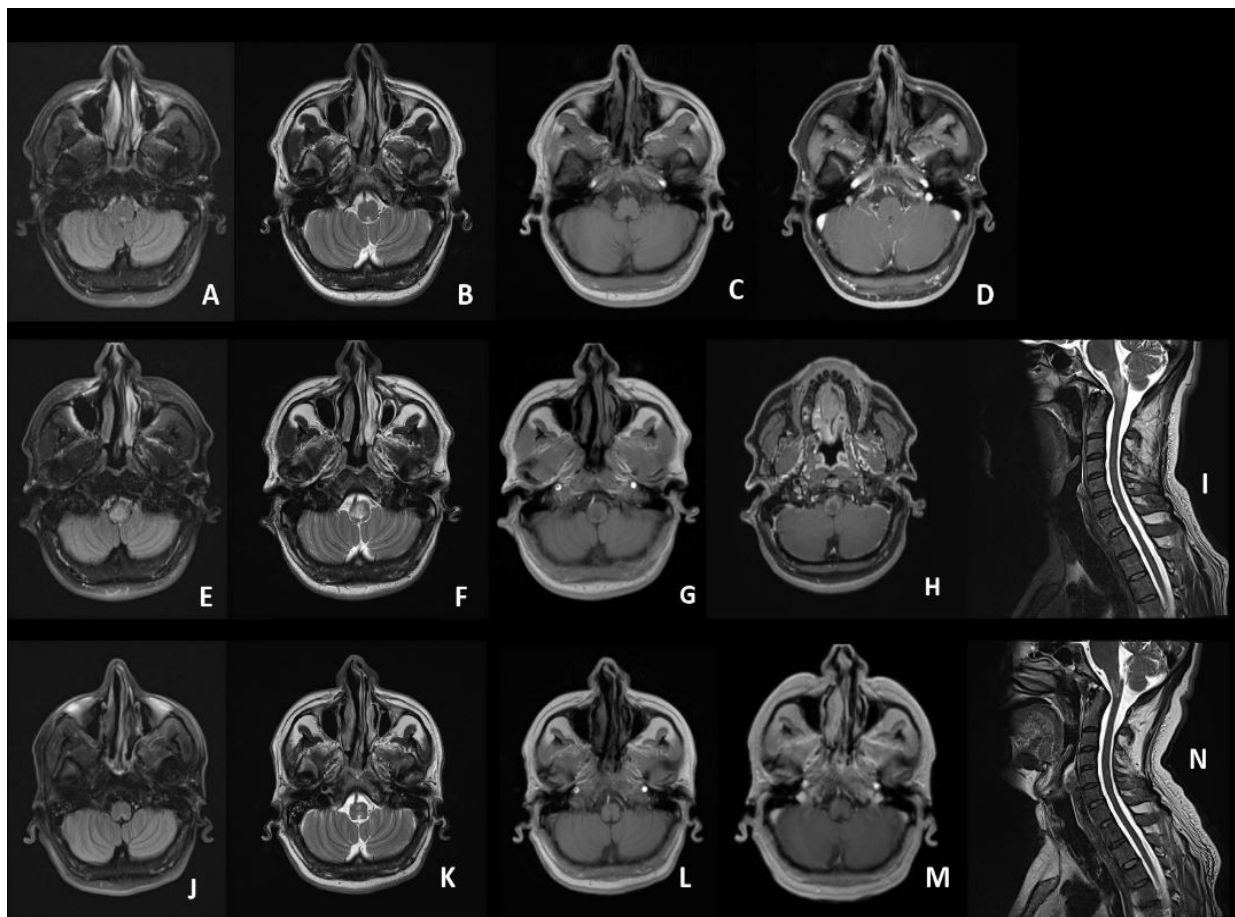


Figure-1: (A,B,C,D) shows subtle enhancement around area postrema, although it was not reported. (E, F, G, H, I) shows T2 and FLAIR hyper-intense signals in the medulla and pons with mild post contrast enhancement. (J, K, L, M, N) showing interval subtle regression in size and signal intensities of the lesion in medulla and the cervico-medullary junction with no significant post contrast enhancement.

Table-1: Investigations

Basic Chemistry	
TLC	5630/ μ L
Haemoglobin	14.5g/dL
Platelets	277000/UL
Creatinine	0.9mg/dL
Sodium	142mEq/L
Potassium	3.8 mEq/L
Ionized Calcium	4.7 mg/dL
ALT	10 U/L
AST	12 U/L
ALP	89 U/L
GGT	47 U/L
Autoimmune Work-Up	
ESR	22
CRP	10.81 mg/L
ANA	Negative
Anti-dsDNA, anti-histone, anti-nucleosome Ab	Negative
C-ANCA, P-ANCA	Negative
Rheumatoid factor	6IU/mL
Cerebrospinal Fluid Studies	
Routine Examination	WBCs: 07 cells/uL, neutrophils: 10% lymphocytes: 90% Glucose: 63 mg/dL (100 mg/dL). Protein: 26.1 mg/dL
C/S	Negative
Cytology	Negative
MTB-DNA PCR	Negative
OG Bands	Negative
Anti-MOG Ab	Negative
AQ-4- Ab	Negative
Anti-GAD Ab	Negative
Anti-TPO Ab	Negative
Anti-TTG	Negative
HIV antibodies	Negative
Anti-neuronal profile (Anti-amphysin antibodies, AntiCV2 antibodies, Anti PNMA2 antibodies, Anti Ri / ANNA-2 antibodies, Anti yo / PCA-1 antibodies, Anti Hu/ANNA-1 antibodies, Anti recoverin antibodies, Anti SOX1 antibodies, Anti Tin antibodies)	Negative
Autoimmune encephalitis panel (NMDA-Receptor, CASPR2 antibodies, Glutamate receptors AMPA1/2, LGI 1 antibodies, DPPX, GABA b receptor)	Negative
Visual evoked potentials	Right: P100 Latency: 113.4 Amplitude: 4.59 Left: P100 Latency: 112.5 Amplitude: 5.4

DISCUSSION

Although, Neuromyelitis Optica was first described by Albutt in 1870⁴ and then by Devic and Gault in 1894⁵, our understanding of the disease has evolved significantly in the past 2 decades, mainly due to the discovery of the disease-specific Aquaporin 4 antibodies in 2004⁶. The diagnostic criteria, revised in 2015⁷, allow diagnosis of NMOSD in cases in which Aquaporin 4 antibodies are either negative or unavailable.

Our case is unusual in many respects. Firstly, represented a diagnostic challenge as he just presented with an area postrema syndrome with a normal neurological examination. The initial MRI brain appeared and was reported as normal,

however, in hindsight, we do appreciate the subtle abnormal signals as shown above.

Secondly, after the initial 2 months or so, his disease progressed very rapidly, requiring IV steroids and plasma exchange and then relapsed quickly on oral steroids and nonsteroidal immune suppressants. Thirdly, the spasms were debilitating and extremely resistant to treatment, even at high doses of carbamazepine, diazepam, baclofen and pregabalin. The decision to administer rituximab was taken early but was not deemed safe due to the severe sepsis. However, he tolerated it fine and his disease course, which was constantly going downhill, only improved after rituximab.

CONCLUSION

Our case was unusual in regards to normal neuroimaging at the initial stage, the sudden transition to an aggressive course of illness despite immunotherapy and frequent relapses which added to the overall morbidity of the patient. This serves as a reminder to keep our suspicion index high even with atypical patterns of neurological diseases presenting in our everyday clinics.

REFERENCES

1. Huda S, Whittam D, Bhojak M, Chamberlain J, Noonan C, Jacob A. Neuromyelitis optica spectrum disorders. Clin Med (Lond). 2019 Mar;19(2):169-176. doi:10.7861/clinmedicine.19-2-169
2. Lana-Peixoto MA, Talim N. "Neuromyelitis Optica Spectrum Disorder and Anti-MOG Syndromes". Biomedicines 2019;7(2):42.
3. Levin MC. Neuromyelitis optica spectrum disorder. Kenilworth (NJ): Merck Manuals. 2020.
4. Albutt T. On the ophthalmoscopic signs of spinal disease. Lancet 1870;1:76-8.
5. Devic E. Myélite subaiguë compliquée de névrite optique. Bull Med 1894;8:1033-4.
6. Lennon VA, Wingerchuk DM, Kryzer TJ, Pittock SJ, Lucchinetti CF, Fujihara K, *et al.* A serum autoantibody marker of neuromyelitis optica: distinction from multiple sclerosis. Lancet 2004;364(9451):2106-12.
7. Wingerchuk DM, Banwell B, Bennett JL, Cabre P, Carroll W, Chitnis T, *et al.* International Panel for NMO Diagnosis 2015. International consensus diagnostic criteria for neuromyelitis optica spectrum disorders. Neurology 2015;85(2):177-89.

Submitted: March 22, 2023

Revised: April 17, 2023

Accepted: May 13, 2023

Address for Correspondence:

Nabeel Muzaffar Syed, Neurology Department, Dar Ul Shifa, Shifa International Hospital, H-8/4 Islamabad, Pakistan

Tel: +92 51 846 3175

Email: nabeel175@gmail.com