

CASE REPORT**ISOLATED PRIMARY HYDATID DISEASE OF THE BREAST****Ayesha Shahid, Shahneela Manzoor, Aazma Mirza**

Department of Surgery, Jinnah Post Graduate Medical Centre Karachi-Pakistan

Our study is relevant because our report adds further light on diagnosing and treating the isolated primary hydatid cyst disease of the breast. The purpose of this case report is to educate physicians and health care workers to keep this condition in the differential diagnosis of the breast lump even though the breast is a rare site of primary hydatid disease even in the endemic areas. Awareness of this entity can help in arriving at a pre-operative diagnosis, even without cytological examination, which is important in the management of the cyst.

This is the first of its kind case being reported from Pakistan.

Keywords: Hydatid; Breast; Liver; Echinococcus

Citation: Shahid A, Manzoor S, Mirza A. Isolated primary hydatid disease of the breast. J Ayub Med Coll Abbottabad 2022;34(4):901-2.

DOI: 10.55519/JAMC-04-10988

INTRODUCTION

This cyclozoonotic disease is caused by the larval stage of cestodes, commonly known as a tapeworm. It belongs to the genus *Echinococcus* under the *Taenia* family.^{1,2} Humans are an incidental host where the parasites hit a dead end. Only about 15% of embryos are free to develop cysts after extermination by the liver and the lungs¹ which also happen to be the organs that have the most chance of developing cysts.

CASE REPORT

A 48 years old female, from Sukkur, consulted the OPD of Jinnah postgraduate medical centre Karachi in August 2020, for a painless lumpy growth in the right breast. According to her, the appearance of symptoms dated back to 8 years when she identified a nodule on self-examination not associated with any increase in its size, or nipple discharge. Clinical examination showed a mass approximately 3 cm in diameter localized to the upper outer quadrant of the right breast. It had a smooth texture, was well confined, movable, pain-free, and lacked any signs of inflammation of the overlying skin. Bilateral breast mammography identified a lobulated soft tissue density lesion containing curvilinear calcification in the right breast measuring 3.3x3.1 cm mass. A concomitant ultrasound showed an irregular thick-walled multiloculated cystic lesion with calcification along the wall and septations at 11 and 12 o'clock positions representing a complicated cyst classified ACR3 BIRADS. Lumpectomy was performed in an elective setting, as shown in Figure 1. Grossly, the lumpectomy specimen was a circumscribed cyst consisting of a whitish membranous structure containing daughter cysts. The histopathological analysis described a cyst wall composed of three layers; an outer fibrous layer, a middle laminar

acellular layer and a focal inner germinal layer containing protoscolices. Postoperative recovery was uneventful and the patient was put on medical treatment based on albendazole 10 mg/kg/day divided into two daily doses for the subsequent three months. The patient reported no distant or local recurrences during the subsequent follow-ups.

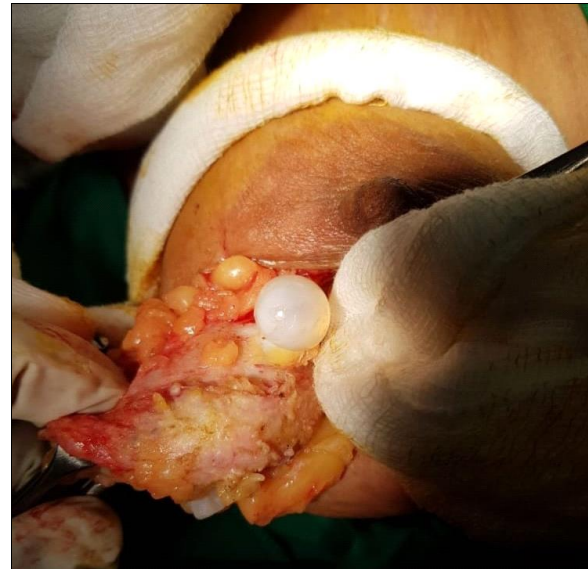


Figure-1: Hydatid cyst excision in progress

DISCUSSION

The breast is an exceptionally unusual primary location for an isolated hydatid cyst and it makes up only about 0.27% of all cyst hydatidoses.²⁻⁵ Upon examination, a smooth contoured circumscribed, movable mass is palpable not accompanying any regional lymphadenopathy as we witnessed in our case. Ultrasonography can show multiple cystic lesions with variable echogenicity and lobulated contours and can define it according to the Gharbi

Classification. Mammography shows ring-shaped structures inside the homogenous round, nonspecific mass and MR imaging might show capsular contrast enhancement.⁴ Although FNAC is a constituent of the triple assessment of breast masses, some authors believe that it should not be done if the ultrasound indicates hydatid as a possible diagnosis.² However, some reports suggest fine-needle aspiration cytology as a reliable and risk-free procedure that can endorse conservative management.⁵ FNAC of the cyst reveals segments of the laminated membrane consisting of parallel striations, scattered retractile hooklets, granular debris, and occasional multinucleated giant cells.^{4,5}

In our case, her mammography and ultrasound strongly suggested a cystic disease so we did not go for FNAC due to the fear of spillage. The gold standard management of isolated hydatid cyst disease of the breast is surgical excision.^{1,5} Incidental spillage and implantation may be restrained by irrigation of the cyst bed with hypertonic saline.⁵ Moreover, it has been established that chemoprophylaxis before and after the surgical excision with mebendazole helps minimize the relapse of cyst formation.^{2,4} Relapse may occur in 2% to 25% cases due to either incompletely excised cysts

or previously unidentified cysts.⁵

CONCLUSION

Our case report highlights the need of keeping isolated hydatid cyst disease, an important differential when dealing with a breast lump.

Consent: Written informed consent was taken for publication of the case and associated pictures.

Acknowledgement: None

Disclaimer: None

Conflict of interest: None.

Funding disclosure: None.

REFERENCES

1. Moussaoui KE, Lakhdar A, Baidada A, Kherbach A. Hydatid cyst of the breast: case report. *Int J Surg Case Rep* 2020;77:325–8.
2. Shekh ZA. Hydatid disease - An unusual cause of a breast cyst: Case report. *Int J Surg Case Rep* 2020;68:178–9.
3. Patmano M, Çetin DA, Gümüş T, Yavuz Y. A Rare Case; Hydatid Cyst of the Breast. *Türkiye Parazitoloj Derg* 2019;43(1):47–9.
4. Temiz A, Albayrak Y, Akalp SÖ, Yalçın A, Albayrak A. Breast Recurrent Hydatid Cyst Disease. *Chirurgia (Bucur)* 2017;112(4):482–5.
5. Cancelo MJ, Martín M, Mendoza N. Preoperative diagnosis of a breast hydatid cyst using fine-needle aspiration cytology: a case report and review of the literature. *J Med Case Rep* 2012;6:293.

Submitted: May 19, 2022

Revised: August 14, 2022

Accepted: November 9, 2022

Address for Correspondence:

Dr. Ayesha Shahid, Department of Surgery, Jinnah Post Graduate Medical Centre Karachi-Pakistan

Cell: +92 336 083 9149

Email: shahidayesha56@yahoo.com