

CASE REPORT

A CASE OF PRECURSOR B-ACUTE LYMPHOBLASTIC LEUKAEMIA MASQUERADING AS HYPEREOSINOPHILIA AND SPACE OCCUPYING LESION IN A 14-YEAR-OLD BOY

Fatima Sharif, Ayesha Junaid, Khadija Ashraf

Department of Haematology, Shifa International Hospital, Islamabad-Pakistan

Peripheral blood eosinophilia is associated with a variety of benign and neoplastic conditions. Rarely, marked eosinophilia can mask an underlying Acute Leukaemia, delaying the correct diagnosis and treatment. Here, we report a case of 14-year-old boy, who presented with marked eosinophilia and space occupying lesion in the brain. Bone marrow biopsy and biopsy of brain lesion were performed to assess the underlying disorder, revealing the unexpected diagnosis of Precursor B- Acute Lymphoblastic Leukaemia in this patient. Cytogenetic studies revealed a normal male karyotype. This case highlights the significance of considering the rare possibility of Acute Lymphoblastic Leukaemia among the differential diagnosis of persistent eosinophilia in order to facilitate prompt and appropriate treatment.

Keywords: Acute Lymphoblastic Leukaemia; Eosinophilia, diagnosis

Citation: Sharif F, Junaid A, Ashraf K. A case of precursor B-Acute lymphoblastic leukaemia masquerading as hyper eosinophilia and space occupying lesion in a 14-year-old boy. J Ayub Med Coll Abbottabad 2022;34(4):903–6.

DOI: 10.55519/JAMC-04-10647

INTRODUCTION

Eosinophilia – defined as an absolute eosinophil count of greater than 500 cells/ul in the peripheral blood – is associated with a variety of reactive and malignant conditions.¹ Reactive causes of eosinophilia include parasitic infections, allergies, asthma, dermatological disorders, medications and autoimmune diseases such as sarcoidosis and Churg Strauss syndrome; whereas clonal proliferation of eosinophils can occur in Hodgkin Lymphoma, Myeloproliferative Neoplasms and Acute Leukemia.² Eosinophilia can mask an underlying leukaemia and delay the actual diagnosis, particularly if steroids are administered.³ Early diagnosis of leukaemia is essential to prevent the associated complications. Here we present the case of a 14-year-old boy who presented with marked eosinophilia and space occupying lesion in the brain. Bone marrow biopsy was performed to assess the underlying cause of markedly raised total leucocyte count, leading to the unexpected diagnosis of Precursor B Acute Lymphoblastic Leukaemia (Pre B-ALL) in this patient.

CASE

A 14-year-old boy presented with the history of fever accompanied by right sided focal seizures and irritability. The fever was documented upto 100 °F. Patient was also admitted three months back with the complaint of sudden onset of headache and transient right arm and forearm weakness with difficulty in writing. Computed tomography was performed on earlier admission as well as on current admission; both revealed impression of progressively increasing subdural collection/enhancing lesion in left parietal region causing mild mass effect. Brain biopsy was advised, but was deferred by the family during the initial visit. During the current visit, the patient was febrile and

lethargic. On examination, there was no visceromegaly or lymphadenopathy. Normal heart sounds and bilateral normal vesicular breathing were noted. His laboratory investigations were sent which revealed a raised C-Reactive Protein of 25 mg/dL (normal up to 5 mg/dL). LDH levels were raised up to 506U/L (135-225U/L), with no apparent evidence of haemolysis. Serum B12 and Folate levels were unremarkable. The striking findings were in his Complete Blood Count which showed: Total leucocyte count of 209,180/ul (4000–11,000/ul, Haemoglobin 14.1g/dl (12–16 g/dl) and Platelet count 141000/ul (150,000 – 450,000/ul). Peripheral smear examination revealed marked leucocytosis with absolute eosinophilia (>80% eosinophils), few myeloid precursors and occasional atypical cells. Serum IgE levels and bone marrow biopsy were advised to investigate the cause of marked leucocytosis with eosinophilia.

Subsequently, bone marrow aspirate and trephine biopsy were performed under sedation. Bone marrow aspirate revealed increased eosinophils and their precursors along with scattered lymphoblasts in the specimen. The blasts were small to medium in size with high nuclear to cytoplasm ratio, immature chromatin and inconspicuous nucleoli. Bone marrow trephine showed a hypercellular marrow with an overall cellularity of 100% and increased blasts, having same morphology as mentioned above. On immunohistochemistry, these blasts were positive for TdT, CD10 and CD20 immunomarkers whereas heterogeneous distribution of CD34 immuno-stain was observed. Diagnosis of Precursor B-Acute Lymphoblastic Leukaemia was made. Peripheral blood and bone marrow findings are depicted in Figure-1. Cytogenetic studies were performed on bone marrow aspirate, revealing a normal male karyotype.

He also underwent biopsy of brain lesion which was consistent with Precursor B- Lymphoblastic Lymphoma. Figure-2 demonstrates the morphological and immunohistochemical findings of brain biopsy in this patient.

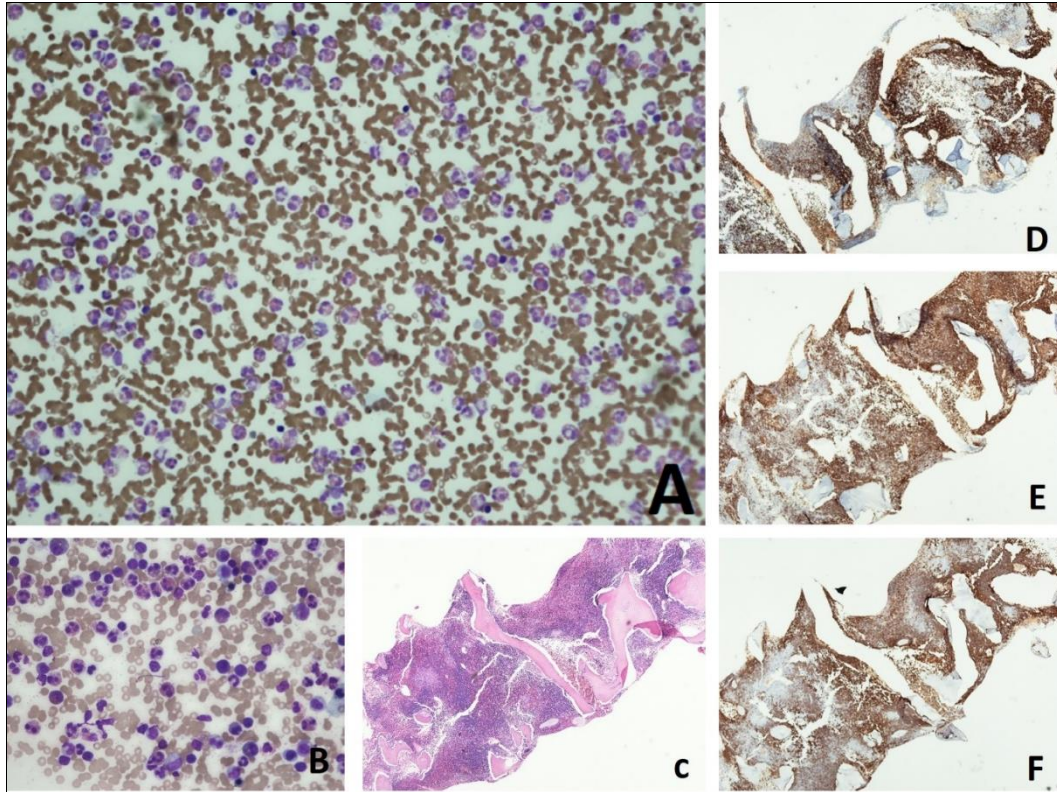


Figure-1: A: Peripheral blood, B: Bone marrow aspirate, C: Trephine biopsy Haematoxylin and Eosin stain, D: Tdt, E: CD10, F: CD20 immunostains

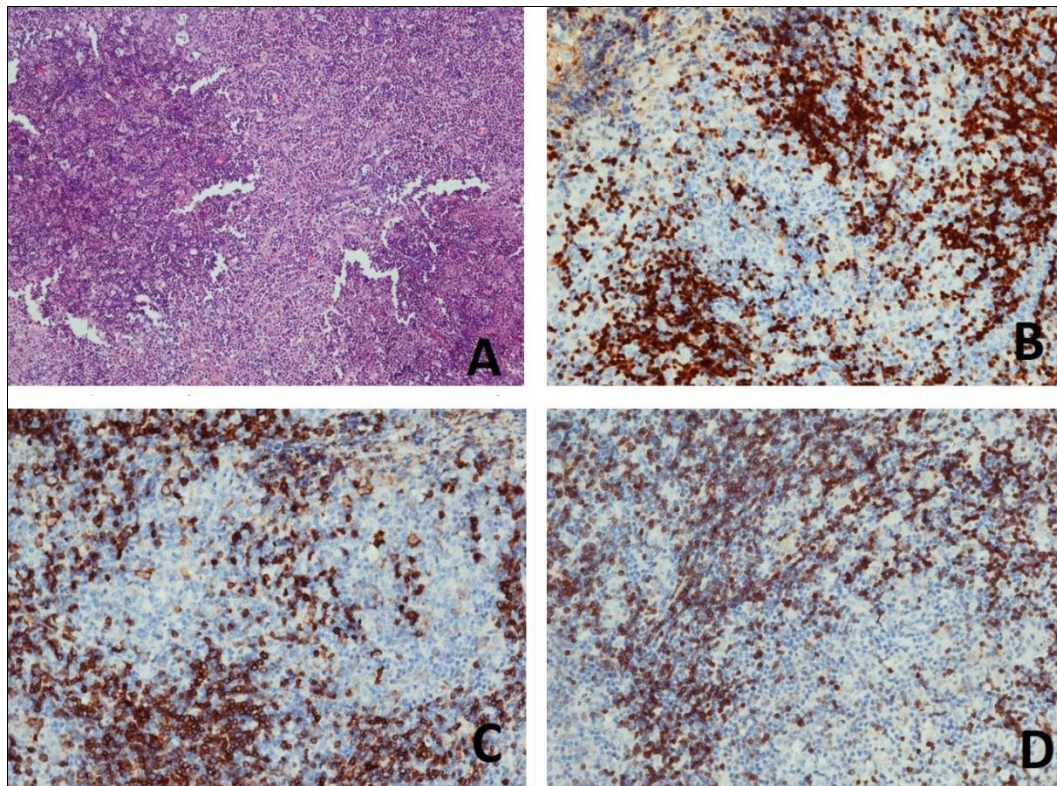


Figure-2: A: Brain biopsy Haematoxylin and Eosin stain, B: CD20, C: Tdt, D: CD79a

Table-1: Clinicopathological and cytogenetic characteristics of ALL patients presenting with eosinophilia

Author	Year	n	Age	Clinical presentation	Cytogenetics/ Molecular studies
Yu <i>et al.</i> ³	2015	1	13 years	Dyspnoea, cardiomegaly, cough, pleural effusion	IL3-IgH rearrangement, PIK3CA mutation
Avramova <i>et al.</i> ⁴	2020	1	30 months	Fever, itching	normal 46 XX karyotype
Kaneko <i>et al.</i> ⁶	2014	1	57 years	Fever, eosinophilia	t(5;14)(q31;q32) IGH-IL3 rearrangement
Song <i>et al.</i> ⁹	2012	1	61 years	Fatigue, muscle pain	normal 46 XY karyotype FISH for BCR/ABL, TEL/AML1, MYC, E2A, MLL, P16, DNA probes of chromosome 5 and 14 were negative
Toboso <i>et al.</i> ¹¹	2017	1	60 years	Dyspnoea, fever, pulmonary embolism, deep vein thrombosis	t(5;14)(q31;q32) IGH-IL3 rearrangement
Matnani <i>et al.</i> ¹²	2020	1	13 years	Flank pain, hepatosplenomegaly	high hyperdiploid karyotype: 52,XY,+X,+4,+9,+14,+21,+21
Ferruzzi <i>et al.</i> ¹³	2018	1	11 years	Headache, fever, cough, weight loss	hyperdiploid karyotype: 53-55, XY, +X, add(1)(q21q25), +4, +9, +10, +14, +2, +1, +21/46, XY
Sahu <i>et al.</i> ¹⁰	2014	1	21 years	Fever, dyspnoea, mediastinal mass	normal karyotype
Bhatti <i>et al.</i> ¹⁴	2009	1	31 years	Fatigue, generalized weakness, joint pain	unique cytogenetic abnormality t(7;12)(q22;p13)-9
Our case	2021	1	14 years	Fever, seizures	Normal karyotype

DISCUSSION

Acute Lymphoblastic Leukaemia (ALL) with eosinophilia accounts for less than 1% of total cases of ALL and has been reported in both adult and paediatric populations.⁴ This rare association was initially reported by Spitzer and Garson in 1973.⁵ However, due to clinical resemblance with Hypereosinophilic Syndrome (HES) and masking of leukemic cells in peripheral blood, the diagnosis may be overlooked unless bone marrow biopsy or flow cytometry is performed.⁶

Various cytogenetic findings have been documented in patients with ALL who present with eosinophilia.⁷ The translocation t(5;14) (q31;q32); IGH-IL3 has been implicated in a number of cases, which juxtaposes the IGH enhancer on chromosome 14q32 to the IL3 gene on 5q31. This results in increased production of interleukin-3 (IL-3), which causes the production and release of eosinophils into the bloodstream.⁸ The eosinophils seen in these cases are mostly mature, therefore it is postulated that the eosinophilia occurring in ALL is a non-neoplastic response to the presence of lymphoblasts.⁹ However, regardless of whether eosinophilia is a reactive or clonal proliferation, eosinophilic infiltration can result in life threatening end organ damage to the heart, lungs, liver, brain and kidneys.¹⁰

Table 1 summarizes the clinicopathological, cytogenetic and/or molecular findings in patients with ALL who presented with peripheral blood eosinophilia.

A study by Ferruzzi *et al.* analyzed the characteristics of several cases of ALL presenting with eosinophilia, reported in the literature between 1973 and 2017.¹³ They found that blasts were present in peripheral blood at the time of diagnosis in 26.3% of the cases whereas 29.5% of patients had a normal

karyotype on cytogenetic studies, as was the case in our patient. Furthermore, they concluded that the association of ALL with hypereosinophilia has a poor prognosis due to increased risk of thromboembolism and cardiac infiltration by eosinophils.¹³

Involvement of the Central Nervous System (CNS) as seen in our patient occurs in approximately 3 to 5% of patients at the time of diagnosis of ALL.¹⁵ In our patient, the features of peripheral blood eosinophilia along with space occupying lesion in a young boy led to the initial differential diagnosis of parasitic disease. However, infection related workup was negative and bone marrow biopsy successfully led to the definitive diagnosis.

CONCLUSION

Acute Lymphoblastic Leukemia is a rare cause of persistent eosinophilia which may be overlooked due to masking of leukemic cells in the peripheral blood. Recognition of this association is imperative for early diagnosis and management of disease.

REFERENCES

1. Butt NM, Lambert J, Ali S, Beer PA, Cross NC, Duncombe A, *et al.* Guideline for the investigation and management of eosinophilia. *Br J Haematol* 2017;176(4):553–72.
2. Larsen RL, Savage NM. How I investigate eosinophilia. *Int J Lab Hematol* 2019;41(2):153–61.
3. Yu H, Wertheim G, Shankar S, Paessler M, Aplenc R, Pillai V. Marked eosinophilia masking B lymphoblastic leukemia. *Am J Hematol* 2016;91(5):543–4.
4. Avramova B, Vlahova I, Banchev A, Bachvarov K, Stoyanova D, Konstantinov D. Hypereosinophilia as a Presenting Symptom of Acute Lymphoblastic Leukemia in a Child. *Int J Clin Pediatr* 2020;9(2):59–63.
5. Spitzer G, Garson OM. Lymphoblastic leukemia with marked eosinophilia: a report of two cases. *Blood* 1973;42(3):377–84.
6. Kaneko H, Shimura K, Yoshida M, Ohkawara Y, Ohshiro M, Tsutsumi Y, *et al.* Acute lymphoblastic leukemia with

- eosinophilia lacking peripheral blood leukemic cell: a rare entity. Indian J Hematol Blood Transfus 2014;30(1):80–3.
7. Loghavi S, Kutok JL, Jorgensen JL. B-acute lymphoblastic leukemia/lymphoblastic lymphoma. Am J Clin Pathol 2015;144(3):393–410.
 8. Fournier B, Balducci E, Duployez N, Clappier E, Cucuini W, Arfeuille C, *et al.* B-ALL with t (5; 14)(q31; q32); IGH-IL3 rearrangement and eosinophilia: a comprehensive analysis of a peculiar IGH-rearranged B-ALL. Front Oncol 2019;9:1374.
 9. Song G, Liu H, Sun F, Gu L, Wang S. Acute lymphocytic leukemia with eosinophilia: a case report and review of the literature. Aging Clin Exp Res 2012;24(5):555–8.
 10. Sahu KK, Malhotra P, Khadwal A, Sachdeva MS, Sharma P, Varma N, *et al.* Hypereosinophilia in acute lymphoblastic leukemia: two cases with review of literature. Indian J Hematol Blood Transfus. 2015;31(4):460–5.
 11. Toboso DG, Campos CB. Peripheral eosinophilia as the first manifestation of B-cell acute lymphoblastic leukemia with t (5; 14)(q31; q32). Blood 2017;130(3):380.
 12. Matnani R, Weissmann D. Hyperdiploid B-lymphoblastic leukemia/lymphoma with hypereosinophilia and very few circulating lymphoblasts. Blood 2020;135(12):974.
 13. Ferruzzi V, Santi E, Gurdo G, Arcioni F, Caniglia M, Esposito S. Acute lymphoblastic leukemia with hypereosinophilia in a child: case report and literature review. Int J Environ Res Public Health 2018;15(6):1169.
 14. Bhatti FA, Hussain I, Ali MZ. Adult B lymphoblastic leukaemia/lymphoma with hypodiploidy (-9) and a novel chromosomal translocation t (7; 12)(q22; p13) presenting with severe eosinophilia—case report and review of literature. J Hematol Oncol 2009;2(1):1–6.
 15. Lenk L, Alsadeq A, Schewe DM. Involvement of the central nervous system in acute lymphoblastic leukemia: opinions on molecular mechanisms and clinical implications based on recent data. Cancer Metastasis Rev 2020;39(1):173–87.

Submitted: January 29, 2022

Revised: February 21, 2022

Accepted: March 27, 2022

Address for Correspondence:

Ayesha Junaid, Consultant Haematologist, Department of Haematology, Shifa International Hospital, Islamabad-Pakistan

Cell: +92 323 508 4779

Email: ayesha.junaid@shifa.com.pk