

## CASE SERIES

## TRANS ORAL ENDOSCOPIC THYROIDECTOMY VESTIBULAR APPROACH (TOETVA), CASE SERIES OF THE FIRST CLINICAL EXPERIENCE FROM PAKISTAN

Iqra Zakir, Ahmad Nawaz

Department of Otorhinolaryngology Liaquat National Postgraduate Medical Centre  
Karachi, Pakistan

**Background:** The objective of the study to assess the workability and cosmetic outcome of endoscopic thyroidectomy vestibular approach (TOETVA) and share results of underdeveloped country with the world about their first clinical experience. **Methods:** We performed TOETVA in 3 patients presenting with thyroid nodules in our hospital, between October 2020 and December 2020 at Liaquat National hospital. Three-port technique was used, one 10-mm port for camera and two 5-mm ports for working. All ports were passed through oral vestibule. The demographic data of the patients and surgical outcomes were retrospectively reviewed. The surgery was completed successfully in all 3 patients. The operative time was between 120–150 mins. **Results:** No complications such as recurrent laryngeal nerve palsy, mental nerve injury or parathyroid gland injury damage occurred in patients postoperatively. No visible scarring occurred in the patients postoperatively. Patients remain stable after surgery and got discharged next day. No complications were noted in 6 months follow up. **Conclusion:** TOETVA is safe, feasible, and effective and scar free option as compared to conventional thyroid surgery.

**Keywords:** TOETVA; Minimally invasive thyroid surgery

**Citation:** Zakir I, Nawaz A. Trans oral endoscopic thyroidectomy vestibular approach (TOETVA), case series of the first clinical experience from Pakistan. J Ayub Med Coll Abbottabad 2023;35(1):148–51.

**DOI:** 10.55519/JAMC-01-10613

### INTRODUCTION

For the past many years the conventional thyroid surgery has remained standard surgical technique after Emil Theodar Kocher modified it in the beginning of 19<sup>th</sup> Century.<sup>1</sup> The scar on the neck after conventional thyroidectomy results in cosmetic defect which can lead to self-consciousness and psychological distress. The evolutionary development of minimally invasive surgeries satisfies the cosmetic demands and cause very less trauma. The first endoscopic neck surgery that was partial Para thyroidectomy was described in 1996.<sup>2</sup> Huscher *et al* in 1997 did endoscopic thyroid surgery for the first time, operated 4mm thyroid nodule through trans cervical approach.<sup>3</sup> Miccoli in 2004 reported 556 cases of minimally invasive video assisted thyroidectomy (MIVAT) that addressed a single small 15mm incision.<sup>4</sup> Witzel described sublingual Transoral approach in 2007.<sup>5</sup> In 2009 Wilhelm described surgical anatomy of the floor of the oral cavity and the neck spaces for trans-oral, minimal-invasive endoscopic surgical procedures<sup>6</sup> and later in 2010 reported his first clinical experience calling it endoscopic minimally invasive thyroidectomy (eMIT)<sup>7</sup>. Nakajo in 2012 reported Trans-Oral Video-Assisted Neck Surgery (TOVANS) which was a new transoral technique of endoscopic thyroidectomy<sup>8</sup> many approaches have been described in the literature like anterior chest wall approach, axillary, cervical,

transoral and breast approach<sup>9–14</sup>. The first case series of trans oral endoscopic thyroidectomy vestibular approach (TOETVA) comprises of sixty cases, was reported by Anuwong in 2015.<sup>15</sup> Transoral endoscopic thyroidectomy via vestibular approach (TOETVA) is one of the recent techniques, offers marvellous cosmetic results by not leaving visible scar provide accessible approach to thyroid and involves minimal dissection resulting in decrease surgical trauma. In this case series we report the first case series of TOETVA in our country.

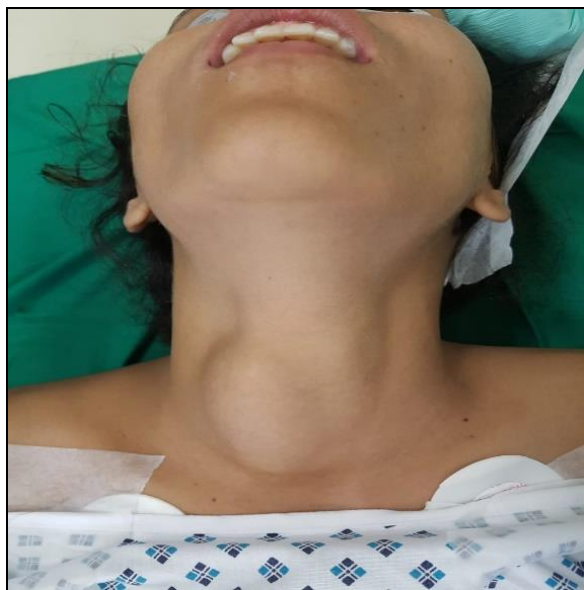
### MATERIAL AND METHODS

We performed lobectomies through TOETVA in 3 patients presenting with thyroid nodules between October 2020 and December 2020 at Liaquat National Postgraduate Medical Centre. The demographic data of the patients and surgical outcomes were retrospectively reviewed after taking approval from hospital. We included three patients, 1 male and 2 females. The age of patients was from 21–30 years with no known comorbid. Pre-operative thyroid function tests were normal in all patients-All lesions were solitary nodule under ultrasonography. Right lobe was involved in all three cases. The nodule diameter range from 2 cm till 5cm. Among 3 cases 1 was cystic nodule and 2 were solid nodes. Pre-operative diagnosis on FNAC showed 1 case of Bethesda III (follicular

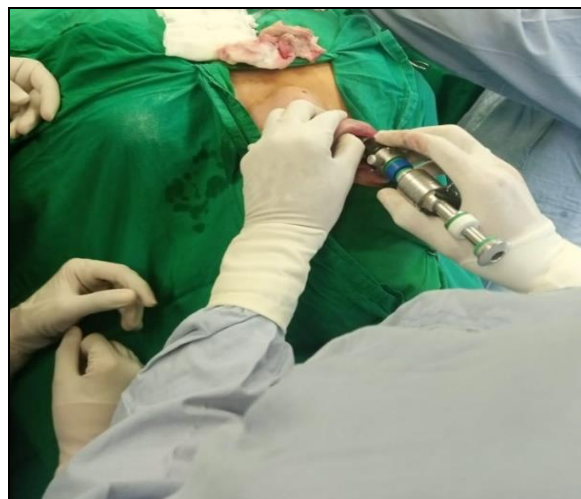lesion of unknown significance) and 2 cases of Bethesda II (benign thyroid nodule). All patients had no compressive symptoms. Histological examination of tissue removed at surgery was suggestive of benign nodule (Bethesda 2).

After inducing general anaesthesia, the patient was placed in supine, shoulder roll inserted below the shoulders for neck extension (Figure-1). A prophylactic antibiotic was given intravenously 30 min before the operation.

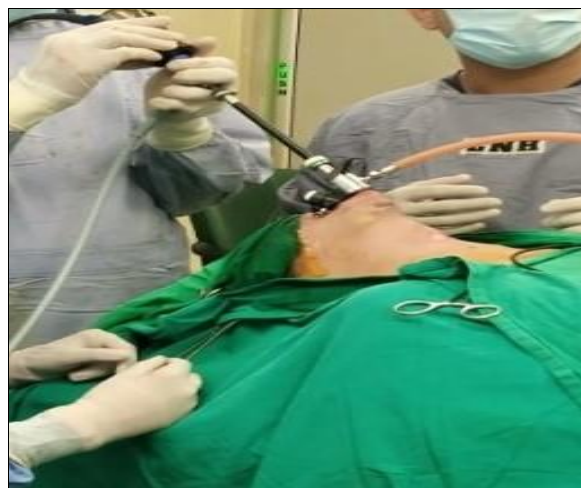The oral cavity was disinfected with chlorhexidine. The gland was approached through the inferior vestibule of the oral cavity through which the midline 10 mm camera port (Figure-2) and two 5 mm working ports were introduced in front of the canine tooth on both sides. 0-degree scope was introduced through the port (Figure-3). The carbon dioxide was insufflated in the operative field which was maintained at 6 mmHg to provide good access. The subplatysmal plane was identified and dissected to create the working space. The fascia was divided, and the strap muscles retracted to improve exposure. Subsequently, the isthmus of the gland was identified and divided, and then the superior and inferior pedicle was identified and divided close to the gland. Recurrent laryngeal nerve was identified in tracheoesophageal groove and preserved. Parathyroid glands were identified and preserved. Haemostasis was secured completely. The entire lobe was brought out through the oral cavity using endobag via a 10mm incision. Strap muscles were closed in midline with vicryl 3/0. Oral vestibule wound closed with vicryl in 2 layers (Figure-4). Oral antibiotics were continued for 7 days and oral diet was started on the day of surgery.



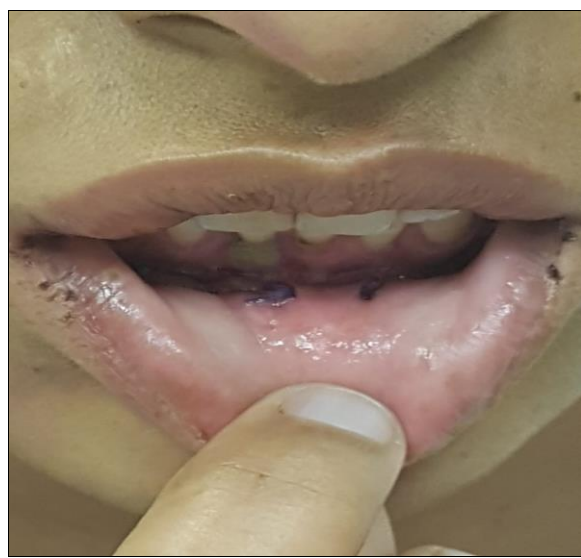**Figure-1: Position of patient for surgery with neck extension**



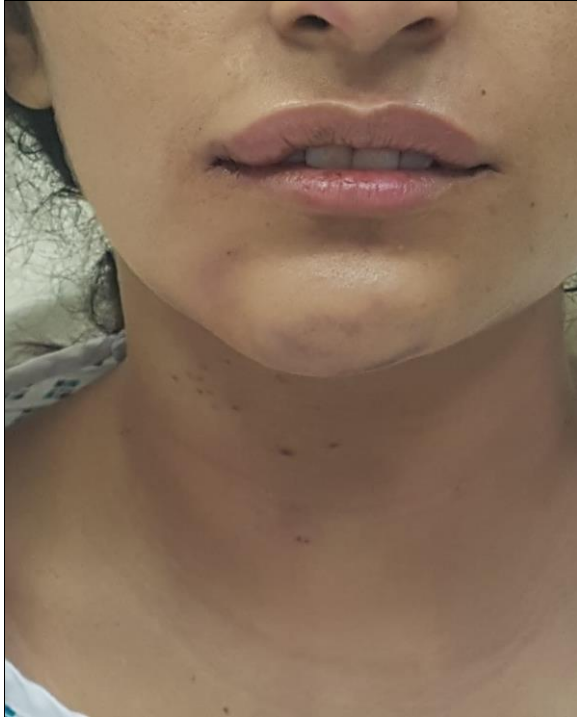**Figure-2: Insertion of trocar during surgery**



**Figure-3: Insertion of endoscope during procedure**



**Figure-4: Vestibular incisions after closure**



**Figure-5: Patient satisfied from the result of surgery**

## RESULTS

All surgeries went uneventful. The operative time was between 120–150 mins. Blood loss was between 100–150ml. Recurrent laryngeal nerve and parathyroid glands were saved in all patients. Postoperative pain was controlled with mild analgesics. No postoperative complications like seroma, recurrent laryngeal nerve palsy, hypocalcaemia, hematoma, superior laryngeal nerve injury and dyspnoea. Patients were kept for observation for 24 hours in hospital and oral diet was started on the day of surgery. Patients were satisfied with the results of their scar free surgery (Figure-5). No complications were noted in 6 months follow-up.

## DISCUSSION

In 19<sup>th</sup> century thyroid surgery was considered as a dreadful butchery by Gross but by twentieth century it was considered one of the safest operations.<sup>16</sup> It is associated with low morbidity and minimal mortality but leaves incisional scar on the neck which cannot be avoided and it affects cosmesis. Cosmesis play a pivotal role in maintaining feeling of self-consciousness and may be the particular concern in patients.

The evolutionary development of endoscopic technologies has allowed surgeons to deliver better cosmetic results and less trauma. To improve cosmetic outcomes various approaches have been discovered such as trans axillary approach, trans

areolar approach, retro auricular approach and trans anterior chest wall approach and they all were quite successful in providing minimal scars but maximal dissections were involved as these approaches were not using natural anatomic planes.<sup>17</sup> In 2010, Wilhelm performed first transoral thyroid surgery with the goal to develop absolutely scar less technique to minimize extensive tissue dissection and trauma seen in extra cervical approaches.<sup>7</sup>

In 2002 Yeung *et al* highlighted that cultures also impact the cosmetic demands of the individual<sup>18</sup> Young individuals are usually particularly more concerned about postoperative scar especially western young females don't want visible scarring especially of breast area. Postoperative scar caused by extra cervical approaches is a social stigma in many countries. Significant social stigma in far eastern countries and Korea associated with visible scars in the neck was highlighted by Foley *et al*.<sup>19</sup> TOETVA has gained considerable attention in recent years, as it preserves anatomic integrity, involves minimal surgical trauma and tissue damage, minimizes morbidity, promotes a quicker recovery, shorten hospital stay and is truly a scar free surgery.

According to the Anuwong *et al* TOETVA is safe and postoperative complication rates is similar to the conventional thyroidectomy but this technique has additional advantage of easy accessibility to both sides of neck, less tissue dissection due to short surgical pathway and good view of the anatomical structures and only approach that avoids cutaneous scar.<sup>20</sup>

TOETVA is a feasible and safe new approach having superb cosmetic results. Our patients developed no postoperative complications and were very satisfied with the results of the surgery. We found this approach very effective and believe that this will be the leading option in future for thyroidectomies. Surgeon's skills and experience will be a learning curve and this will improve with time.

## CONCLUSION

TOETVA is a safe and advisable alternative with several advantages and is becoming famous among patients all around the world due to its amazing cosmetic results. In near future maybe it will be one final frontier in endoscopic thyroidectomy.

## REFERENCES

1. Yu JJ, Bao SL, Yu SL, Zhang DQ, Loo WT, Chow LW, *et al*. Minimally invasive video-assisted thyroidectomy for the early-stage differential thyroid carcinoma. *J Transl Med* 2012;10(1):13.
2. Gagner M. Endoscopic subtotal parathyroidectomy in patients with primary hyperparathyroidism. *Br J Surg* 1996;83(6):875.

3. Hüscher CS, Chiodini S, Napolitano C, Recher A. Endoscopic right thyroid lobectomy. *Surg Endosc* 1997;11(8):877.
4. Miccoli P, Materazzi G. Minimally invasive, video-assisted thyroidectomy (MIVAT). *Surg Clin North Am* 2004;84(3):735–41.
5. Witzel K, Von Rahden BHA, Kaminski C, Stein HJ. Transoral access for endoscopic thyroid resection. *Surg Endosc* 2008;22(8):1871–5.
6. Wilhelm T, Harlaar JJ, Kerver A, Kleinrensink GJ, Benhidjeb T. Surgical anatomy of the floor of the oral cavity and the cervical spaces as a rationale for trans-oral, minimal-invasive endoscopic surgical procedures: results of anatomical studies. *Eur Arch Otorhinolaryngol* 2010;267(8):1285–90.
7. Wilhelm T, Metzigg A. Endoscopic minimally invasive thyroidectomy: first clinical experience. *Surg Endosc* 2010;24(7):1757–8.
8. Nakajo A, Arima H, Hirata M, Mizoguchi T, Kijima Y, Mori S, *et al.* Trans-Oral Video-Assisted Neck Surgery (TOVANS). A new transoral technique of endoscopic thyroidectomy with gasless premandible approach. *Surg Endosc* 2013;27(4):1105–10.
9. Inabnet WB 3rd, Jacob BP, Gagner M. Minimally invasive endoscopic thyroidectomy by a cervical approach. *Surg Endosc* 2003;17(11):1808–11.
10. Cho YU, Park IJ, Choi KH, Kim SJ, Choi SK, Hur YS, *et al.* Gasless endoscopic thyroidectomy via an anterior chest wall approach using a flap-lifting system. *Yonsei Med J* 2007;48(3):480–7.
11. Ikeda Y, Takami H, Sasaki Y, Takayama J, Niimi M, Kan S. Clinical benefits in endoscopic thyroidectomy by the axillary approach. *J Am Coll Surg* 2003;196(2):189–95.
12. Lee J, Chung WY. Current status of robotic thyroidectomy and neck dissection using a gasless transaxillary approach. *Curr Opin Oncol* 2012;24(1):7–15.
13. Choe JH, Kim SW, Chung KW, Park KS, Han W, Noh DY, *et al.* Endoscopic thyroidectomy using a new bilateral axillo-breast approach. *World J Surg* 2007;31(3):601–6.
14. Koh YW, Kim JW, Lee SW, Choi EC. Endoscopic thyroidectomy via a unilateral axillo-breast approach without gas insufflation for unilateral benign thyroid lesions. *Surg Endosc* 2009;23(9):2053–60.
15. Anuwong A. Transoral endoscopic thyroidectomy vestibular approach: a series of the first 60 human cases. *World J Surg* 2016;40(3):491–7.
16. Hannan SA. The magnificent seven: a history of modern thyroid surgery. *Int J Surg* 2006;4(3):187–91.
17. Tan CTK, Cheah WK, Delbridge L. “Scarless” (in the neck) endoscopic thyroidectomy (SET): an evidence-based review of published techniques. *World J Surg* 2008;32(7):1349–57.
18. Yeung GHC. Endoscopic thyroid surgery today: a diversity of surgical strategies. *Thyroid* 2002;12(8):703–6.
19. Foley CS, Agcaoglu O, Siperstein AE, Berber E. Robotic transaxillary endocrine surgery: a comparison with conventional open technique. *Surg Endosc* 2012;26(8):2259–66.
20. Anuwong A, Sasanakietkul T, Jitpratoom P, Ketwong K, Kim HY, Dionigi G, *et al.* Transoral endoscopic thyroidectomy vestibular approach (TOETVA): indications, techniques and results. *Surg Endosc* 2018;32(1):456–65.

Submitted: January 21, 2022

Revised: November 1, 2022

Accepted: November 7, 2022

### Address for Correspondence:

**Iqra Zakir**, Department of Otorhinolaryngology, Liaquat National Postgraduate Medical Centre, Karachi-Pakistan

**Cell:** +92 333 3197871

**Email:** iqrazakir00@gmail.com